

colloid, and the autologous whole blood is reinfused within 4-6 h of its collection.

We encourage the use of this technique as well as autologous pre-donation of blood to decrease the surgical patient's exposure to the risk of homologous blood products.

DON HAN, M.D.
Liver Transplant Fellow

MEG ROSENBLATT, M.D.
Assistant Professor

Anesthesiology
73:1057, 1990

Bloodless Turbinectomy Following Blind Nasal Intubation: Faulty Technique?

To the Editor:—Cooper¹ reported "middle turbinectomy" following nasal intubation. Anesthesiologists should be aware that this is a rare but unacceptable complication of nasal intubation.

With correct technique of nasal intubation, the middle turbinate should never be contacted by an endotracheal tube. It should pass between the inferior turbinate and the floor of the nasal cavity, where there is maximum area to accommodate it.

When an endotracheal tube is being inserted through the nostril's opening, its bevel should be directed laterally so as to direct its leading edge away from the superior, middle, and inferior turbinates. Then before it is advanced, it should be pulled cephalad (fig. 1). Doing so directs its bevel so that it is advanced along the floor of the nasal cavity and below the inferior turbinate. When it is judged that the tip of the tube has passed the uvula, the exposed part of the endotracheal tube, which has not passed the nostril, is returned to its normal curvature. Then the tube is advanced toward the larynx.

DANIEL C. MOORE, M.D.
*Department of Anesthesiology
The Mason Clinic
1100 Ninth Avenue
P.O. Box 900
Seattle, Washington 98111*

Anesthesiology
73:1057, 1990

In Reply:—I wish to thank Dr. Moore for his comments concerning my Letter to the Editor.¹ His description of nasal intubation, in particular the pulling of the endotracheal tube cephalad before it is advanced along the floor of the nasal cavity, when correctly followed should avoid trauma to the turbinates in the majority of cases.

When an endotracheal tube has been softened by prewarming, the advantage gained by a cephalad pull can be reduced, since this pull depends on the fulcrum effect of the nostril against a relatively firm endotracheal tube.

I must emphasize that the main point of my letter was to urge vigilance after cocaine paste has been applied to the nasal mucosa as described by Pearman,² since absence of bleeding even with a proper technique of nasal intubation does not preclude severe nasopharyngeal trauma and the entry of foreign material into the airway.

*Department of Anesthesiology
Box 1010
The Mount Sinai Medical Center
1 Gustave L. Levy Place
New York, New York 10029-6574*

REFERENCE

1. Bourke DL, Smith TC: Estimating allowable hemodilution. *ANESTHESIOLOGY* 41:609-612, 1974

(Accepted for publication September 5, 1990.)

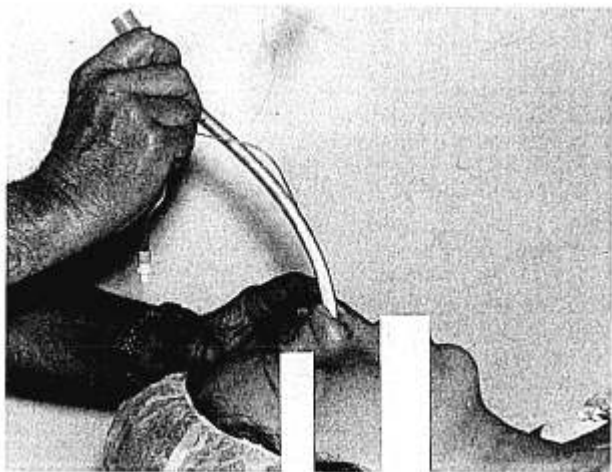


FIG. 1. Nasal tracheal intubation showing cephalad traction being placed upon the tube as the tip is advanced along the floor of the nasal cavity.

REFERENCE

1. Cooper R: Bloodless turbinectomy following blind nasal intubation (letter). *ANESTHESIOLOGY* 71:469, 1989

(Accepted for publication September 5, 1990.)

RON COOPER, M.B., F.F.A.R.C.S.I.
*23 William Street
Donaghadee, Co. Down
Northern Ireland BT21 OHL*

REFERENCES

1. Cooper R: Bloodless turbinectomy following blind nasal intubation. *ANESTHESIOLOGY* 71:469, 1989
2. Pearman K: Cocaine: A review. *J Laryngol Otol* 93:1191-1199, 1979

(Accepted for publication September 5, 1990.)