

lation. Between 0.4 and 4% of treatment cycles will result in severe OHSS. Some of these patients will require surgery and anesthetic management for termination of pregnancy or laparotomy.⁸ Therefore, it becomes important for the anesthesiologist to understand the related pathophysiology and potential treatment modalities for severe OHSS.

The authors wish to thank Daniel Navot, M.D., for his critical appraisal of this manuscript.

REFERENCES

1. Schenker JC, Weinstein D: Ovarian hyperstimulation syndrome: A current survey. *Fertil Steril* 30:255-268, 1978
2. Demey HE, Daelemans R, Galdermans D, Verpooten GA, DeBroe ME, Bossaert LL: Acute oligo-anuria during ovarian hyperstimulation syndrome. *Acta Obstet Gynecol Scand* 66:741-743, 1987
3. Zosmer A, Katz Z, Lancet M, Konichezky S, Schwartz-Shoham Z: Adult respiratory distress syndrome complicating ovarian hyperstimulation syndrome. *Fertil Steril* 47:524-526, 1987
4. Navot D, Relou A, Birkenfeld A, Rabinowitz R, Brezezinski A, Margalioth J: Risk factors and prognostic variables in the ovarian hyperstimulation syndrome. *Am J Obstet Gynecol* 159:210-215, 1988
5. Navot D, Margalioth EJ, Laufer N, Birkenfeld A, Relou A, Rosler A, Schenker JC: Direct correlation between plasma renin activity and severity of the ovarian hyperstimulation syndrome. *Fertil Steril* 48:57-61, 1987
6. Sueldo CE, Price HM, Bachenberg K, Steinleitner A, Gitlin N, Swanson J: Liver dysfunction in ovarian hyperstimulation syndrome: A case report. *J Reprod Med* 33:387-390, 1988
7. Kirshon B, Doody MC, Cotton DB, Gibbons W: Management of ovarian hyperstimulation syndrome with chlorpheniramine maleate, mannitol, and invasive hemodynamic monitoring. *Obstet Gynecol* 71:485-487, 1988
8. Shulman DL, Sherer D, Beilin B: Pulmonary edema in the ovarian hyperstimulation syndrome. *N Z Med J* 101:643-644, 1988

Anesthesiology
73:1277-1279, 1990

Pneumoencephalos after Inadvertent Intrathecal Air Injection during Epidural Block

YESHAYAHU KATZ, M.D., D.Sc.,* ROBERT MARKOVITS, M.D.,† BENO ROSENBERG, M.D.‡

The "loss-of-resistance" technique is routinely employed for identification of the epidural space. During performance of this test, air may be injected along the epidural needle tract and into the epidural space.¹ We report a case in which a loss-of-resistance test used in the presence of unnoticed dural puncture resulted in a severe transient neurologic event. If a computerized tomographic (CT) brain scan had not been performed, the neurologic symptoms might have been attributed to another complication—prolonged neurotoxicity of bupivacaine hydrochloride following total spinal anesthesia—which also occurred during the administration of this epidural block.

CASE REPORT

A healthy, 25-yr-old primigravida was anesthetized with epidural block for cesarean section. Using a 16-G Tuohy needle, the epidural

space was identified, after many attempts, by a loss-of-resistance test and subsequent repeated injections of air (total amount, approximately 20 ml) for further confirmation of needle localization. Sixteen milliliters of bupivacaine hydrochloride 0.5% with epinephrine 1:200,000 were slowly injected and were followed immediately by cessation of respiration and a decrease in blood pressure. After tracheal intubation, the patient's lungs were mechanically ventilated with 100% oxygen, 2,000 ml saline supplemented with 50 mg ephedrine were administered intravenously, and blood pressure rapidly increased to preanesthetic values. An infant with normal Apgar scores was delivered, after which anesthesia was maintained using 10 mg diazepam, 0.3 mg fentanyl, and a mixture of 66% N₂O in oxygen. At the end of the operation, the patient was transferred to the recovery room, and mechanical ventilation was continued until the effects of the total spinal anesthesia were expected to subside. Four hours later, spontaneous breathing resumed and involuntary movement began. The patient, however, remained drowsy and stuporous. Since her condition did not improve over the following hours, she was referred to our hospital for neurologic evaluation.

A CT brain scan revealed a large subarachnoid air-filled cavity located mainly at the parietofrontal cerebral cortex region with an estimated volume of 25 ml. The ventricles were not displaced and appeared normal (fig. 1). The patient was admitted to the neurosurgical intensive care unit (ICU) for continuous monitoring. The next day, her neurologic status improved, and she was able to sit, talk, and move freely. A repeat CT scan did not show any residual air within the subarachnoid space, and the patient was discharged from the neurologic ICU on the third day postpartum.

DISCUSSION

The clinical symptoms presented by the patient could have been attributed, if not correctly diagnosed, to pro-

* Resident in Anesthesiology.

† Senior Anesthetist.

‡ Senior Lecturer and Head, Department of Anesthesiology.

Received from the Department of Anesthesiology, Rambam Medical Center and Faculty of Medicine, Technion-Israel Institute of Technology, Haifa, Israel. Accepted for publication July 11, 1990.

Address reprint requests to Dr. Katz: Department of Pharmacology, Faculty of Medicine, Technion-Israel Institute of Technology, P.O.B. 9649, 31096 Haifa, Israel.

Key words: Anesthetics, local: bupivacaine. Anesthetic techniques: epidural. Complications: intrathecal injection. Pneumoencephalos.

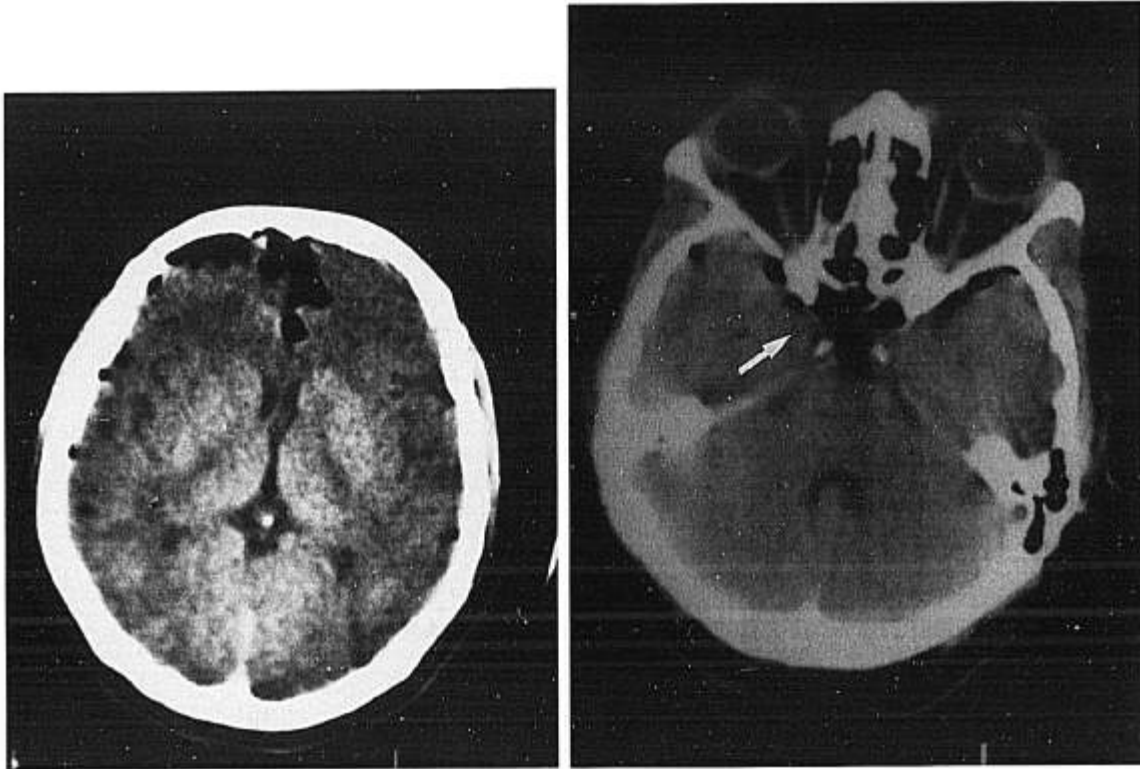


FIG. 1. Computerized tomographic brain scan showing multiple air-filled cavities, mainly in the right subarachnoid frontoparietal cerebral cortex (left) and in the suprasellar cistern (right, arrow).

longed neurotoxicity caused by the subarachnoid injection of the local anesthetic. The incidence of this complication, however, is very rare. Moore and Bridenbaugh,² in a study of 11,574 cases of spinal block, reported on two patients with sustained analgesia (36 and 48 h); one of the latter complained of muscular weakness of the lower extremities that persisted for 8 months. Lund,³ in a series of 10,000 cases, found that inadvertent spinal block with 2% hexylcaine hydrochloride resulted in residual partial paralysis of the leg in one patient, and Moore *et al.*,⁴ in a study of 7,286 patients, also reported on one patient who had postoperative bilateral quadriceps paralysis.

It should be stressed, however, that in none of the aforementioned large-scale epidemiologic studies was bupivacaine hydrochloride used. In contrast, more recent publications that have addressed the issue of bupivacaine hydrochloride use for epidural anesthesia in labor have indicated that the incidence of delayed recovery from the neural blockade with this drug is significantly higher.^{5,6} A variety of causes, including hypotension, the addition of epinephrine in various dilutions,⁷ and the relatively tenacious tissue binding of bupivacaine hydrochloride, have been implicated for the resultant persistent neurobehavioral impairment. § Such properties may pertain to

the current case in which the presence of bupivacaine hydrochloride in the brain produced the unexpected and prolonged neurologic changes observed in this patient. The duration of symptoms *per se* is not indicative of the etiology of this event, since neurologic sequelae of tension pneumocephalus may last for days or weeks,⁸ as do those of local anesthetic neurotoxicity.⁹

Before the era of CT scanning and nuclear magnetic resonance imaging, pneumoencephalography was commonly used to visualize intracranial lesions. To perform this test, a large volume (30–40 ml) of air was injected through a spinal needle after an equivalent amount of cerebrospinal fluid (CSF) had been evacuated. This procedure is generally free of side effects, but sometimes pneumoencephalos may manifest symptoms and signs ranging from persistent headache through lethargy, confusion, and slow arousal, up to hemiparesis and hemiplegia.⁸ In the current case, preventive drainage of CSF obviously was not conducted before the inadvertent intrathecal injection of air, although the possibility exists that some of the CSF exited through the puncture in the dura. Moreover, the use of N₂O after switching to general anesthesia further complicated the situation. Saidman and Eger¹⁰ found an increase in CSF pressure in humans anesthetized with N₂O after injection of air into the lumbar subarachnoid space for pneumoencephalography. Thus, the increased pressure within the 25-ml air-filled cavity during the administration of N₂O worsened the

§ Wegrzynowicz ES: Comparison of equi-myocardial depressant doses of lidocaine vs. bupivacaine on cardiac toxicity duration (abstract). ANESTHESIOLOGY 63:A222, 1985.

intracranial cavity space-occupying effect, leading to the observed encephalopathy. This effect of N₂O is short-lived due to rapid reabsorption on its discontinuation^{10,11}; however, the neurologic sequelae may persist for several days, as can be encountered not only in tension pneumocephalos but also in bupivacaine hydrochloride toxicity.

In conclusion, the described complication emphasizes the caution with which the injection of air in the loss-of-resistance test should be implemented. If total spinal anesthesia occurs during the performance of epidural block and general anesthesia is required, the use of N₂O should be avoided if air had been used as part of a loss-of-resistance test. The current case supports clinicians who recommend identifying the epidural space with a loss of resistance to saline rather than to air. Such a measure could avoid the potential for pneumocephalos entirely.

The authors thank Ruth Singer for typing and editing the manuscript.

REFERENCES

1. Rozenberg B, Tischler S, Glick A: Abdominal subcutaneous emphysema: An unusual complication of lumbar epidural block (letter). *Can J Anaesth* 35:325, 1988

2. Moore DC, Bridenbaugh LD: Spinal (subarachnoid) block: A review of 11,574 cases. *JAMA* 195:123-128, 1966
3. Lund PC: Peridural anesthesia. *Acta Anaesthesiol Scand* 6:143-159, 1962
4. Moore DC, Bridenbaugh LD, Bagdi PA, Bridenbaugh PO, Stander H: The present status of spinal (subarachnoid) and epidural (peridural) block: A comparison of the two technics. *Anesth Analg* 47:40-49, 1968
5. Cuerden C, Buley R, Downing JW: Delayed recovery after epidural block in labour: A report of four cases. *Anaesthesia* 32:773-776, 1977
6. Moore J, Murnaghan GA, Lewis MA: A clinical evaluation of the maternal effects of lumbar extradural analgesia for labour. *Anaesthesia* 29:537-544, 1974
7. Urquhart-Hay D: Paraplegia following analgesia: Case report. *Anaesthesia* 24:461-470, 1969
8. Standefer M, Bay JW, Trusso R: The sitting position in neurosurgery: A retrospective analysis of 488 cases. *Neurosurgery* 14:649-658, 1984
9. Pathy GV, Rosen M: Prolonged block with recovery after extradural analgesia for labour. *Br J Anaesth* 47:520-522, 1975
10. Saidman LJ, Eger EI II: Changes in cerebrospinal fluid pressure during pneumoencephalography under nitrous oxide anesthesia. *ANESTHESIOLOGY* 26:67-72, 1965
11. Aired RB: Experimental encephalography with anesthetic gases. *Arch Surg* 32:193-198, 1936

Anesthesiology
73:1279-1282, 1990

Tracheal Agensis: Resuscitative Management

STEVEN M. McDONALD, M.D.,* NANCY E. ORIOL, M.D.†

Complete tracheal agensis is a very rare anomaly. This report describes the successful respiratory resuscitation of a newborn who was later discovered to have tracheal agensis.

CASE REPORT

A 30-yr-old woman (gravida 6, para 1, spontaneous abortion 3) (G₆P₁SAb₃) was scheduled for a repeat cesarean section at Boston's

Beth Israel Hospital. Ultrasound revealed a single pregnancy with mild polyhydramnios and a slightly small-for-gestational-age fetus.

Cesarean section was performed under lumbar epidural anesthesia. Immediately on delivery, the neonate was noted to make respiratory efforts without an audible cry. These respiratory efforts ceased within seconds as the obstetrician suctioned a large quantity of fluid from the airway. As the anesthesiologist received the neonate, no spontaneous respirations were noted, so ventilation with positive pressure *via* bag and mask was attempted; however, no lung inflation was achieved. The 1-min Apgar score was 2 (+2 for heart rate). Direct laryngoscopy was performed, and a Neo-Vac® (Concord Portex, Keene, NH) 3.0-mm suctioning device/endotracheal tube was placed through the vocal cords *via* direct vision. After removal of the stylet-suction catheter, attempted positive pressure ventilation *via* the endotracheal tube (ETT) was again unsuccessful. In light of the copious secretions, a decision was made to suction the ETT. The stylet-suction catheter was reinserted. Initially, there was resistance to advancement of the stylet-suction catheter, but it suddenly decreased, allowing full insertion of the catheter. After repeat suctioning, a third attempt at positive pressure ventilation *via* the ETT was again unsuccessful. The ETT was then withdrawn about 0.5 cm, enabling apparently normal ventilation of the lungs. It was assumed that the ETT had been placed in the right main stem bronchus and the repositioning had allowed ventilation. Breath sounds were now equal bilaterally, although rhonchi were present throughout both lung fields.

After ventilation for 3 min, the 5-min Apgar score was 8 (-1 for

* Resident in Anesthesia, Beth Israel Hospital, Clinical Fellow in Anesthesia, Harvard Medical School, Boston, Massachusetts.

† Instructor in Anesthesia, Beth Israel Hospital, Director of Obstetric Anesthesia, Harvard Medical School, Boston, Massachusetts.

Received from Beth Israel Hospital and Harvard Medical School, Boston, Massachusetts. Accepted for publication July 11, 1990.

Address reprint requests to Dr. McDonald: Department of Anesthesia, Beth Israel Hospital, 330 Brookline Avenue, Boston, Massachusetts 02215.

Key words: Bronchoesophageal fistula. Neonatal resuscitation. Pediatrics: congenital anomalies. Tracheal agensis. Tracheoesophageal fistula.