

intracranial cavity space-occupying effect, leading to the observed encephalopathy. This effect of N<sub>2</sub>O is short-lived due to rapid reabsorption on its discontinuation<sup>10,11</sup>; however, the neurologic sequelae may persist for several days, as can be encountered not only in tension pneumocephalos but also in bupivacaine hydrochloride toxicity.

In conclusion, the described complication emphasizes the caution with which the injection of air in the loss-of-resistance test should be implemented. If total spinal anesthesia occurs during the performance of epidural block and general anesthesia is required, the use of N<sub>2</sub>O should be avoided if air had been used as part of a loss-of-resistance test. The current case supports clinicians who recommend identifying the epidural space with a loss of resistance to saline rather than to air. Such a measure could avoid the potential for pneumocephalos entirely.

The authors thank Ruth Singer for typing and editing the manuscript.

#### REFERENCES

1. Rozenberg B, Tischler S, Glick A: Abdominal subcutaneous emphysema: An unusual complication of lumbar epidural block (letter). *Can J Anaesth* 35:325, 1988

2. Moore DC, Bridenbaugh LD: Spinal (subarachnoid) block: A review of 11,574 cases. *JAMA* 195:123-128, 1966
3. Lund PC: Peridural anesthesia. *Acta Anaesthesiol Scand* 6:143-159, 1962
4. Moore DC, Bridenbaugh LD, Bagdi PA, Bridenbaugh PO, Stander H: The present status of spinal (subarachnoid) and epidural (peridural) block: A comparison of the two technics. *Anesth Analg* 47:40-49, 1968
5. Cuerden C, Buley R, Downing JW: Delayed recovery after epidural block in labour: A report of four cases. *Anaesthesia* 32:773-776, 1977
6. Moore J, Murnaghan GA, Lewis MA: A clinical evaluation of the maternal effects of lumbar extradural analgesia for labour. *Anaesthesia* 29:537-544, 1974
7. Urquhart-Hay D: Paraplegia following analgesia: Case report. *Anaesthesia* 24:461-470, 1969
8. Standefer M, Bay JW, Trusso R: The sitting position in neurosurgery: A retrospective analysis of 488 cases. *Neurosurgery* 14:649-658, 1984
9. Pathy GV, Rosen M: Prolonged block with recovery after extradural analgesia for labour. *Br J Anaesth* 47:520-522, 1975
10. Saidman LJ, Eger EI II: Changes in cerebrospinal fluid pressure during pneumoencephalography under nitrous oxide anesthesia. *ANESTHESIOLOGY* 26:67-72, 1965
11. Aired RB: Experimental encephalography with anesthetic gases. *Arch Surg* 32:193-198, 1936

Anesthesiology  
73:1279-1282, 1990

## Tracheal Agenesis: Resuscitative Management

STEVEN M. McDONALD, M.D.,\* NANCY E. ORIOL, M.D.†

Complete tracheal agenesis is a very rare anomaly. This report describes the successful respiratory resuscitation of a newborn who was later discovered to have tracheal agenesis.

#### CASE REPORT

A 30-yr-old woman (gravida 6, para 1, spontaneous abortion 3) (G<sub>6</sub>P<sub>1</sub>SAb<sub>3</sub>) was scheduled for a repeat cesarean section at Boston's

Beth Israel Hospital. Ultrasound revealed a single pregnancy with mild polyhydramnios and a slightly small-for-gestational-age fetus.

Cesarean section was performed under lumbar epidural anesthesia. Immediately on delivery, the neonate was noted to make respiratory efforts without an audible cry. These respiratory efforts ceased within seconds as the obstetrician suctioned a large quantity of fluid from the airway. As the anesthesiologist received the neonate, no spontaneous respirations were noted, so ventilation with positive pressure *via* bag and mask was attempted; however, no lung inflation was achieved. The 1-min Apgar score was 2 (+2 for heart rate). Direct laryngoscopy was performed, and a Neo-Vac® (Concord Portex, Keene, NH) 3.0-mm suctioning device/endotracheal tube was placed through the vocal cords *via* direct vision. After removal of the stylet-suction catheter, attempted positive pressure ventilation *via* the endotracheal tube (ETT) was again unsuccessful. In light of the copious secretions, a decision was made to suction the ETT. The stylet-suction catheter was reinserted. Initially, there was resistance to advancement of the stylet-suction catheter, but it suddenly decreased, allowing full insertion of the catheter. After repeat suctioning, a third attempt at positive pressure ventilation *via* the ETT was again unsuccessful. The ETT was then withdrawn about 0.5 cm, enabling apparently normal ventilation of the lungs. It was assumed that the ETT had been placed in the right main stem bronchus and the repositioning had allowed ventilation. Breath sounds were now equal bilaterally, although rhonchi were present throughout both lung fields.

After ventilation for 3 min, the 5-min Apgar score was 8 (-1 for

\* Resident in Anesthesia, Beth Israel Hospital, Clinical Fellow in Anesthesia, Harvard Medical School, Boston, Massachusetts.

† Instructor in Anesthesia, Beth Israel Hospital, Director of Obstetric Anesthesia, Harvard Medical School, Boston, Massachusetts.

Received from Beth Israel Hospital and Harvard Medical School, Boston, Massachusetts. Accepted for publication July 11, 1990.

Address reprint requests to Dr. McDonald: Department of Anesthesia, Beth Israel Hospital, 330 Brookline Avenue, Boston, Massachusetts 02215.

Key words: Bronchoesophageal fistula. Neonatal resuscitation. Pediatrics: congenital anomalies. Tracheal agenesis. Tracheoesophageal fistula.

acrocyanosis and -1 for irregular respirations). Fifteen minutes after birth, the infant was vigorous, had normal tone, and was maintaining strong, regular spontaneous respirations *via* the ETT. Therefore, the ETT was withdrawn. Immediately after extubation, the infant developed respiratory distress and required positive pressure ventilation by mask to maintain normal skin color. Multiple attempts at reintubation with a 2.5- and 3.0-mm ETT with and without stylets, respectively, proved unsuccessful. The ETT could not be passed through the cords more than 1 cm, and ventilation was unsuccessful. Between each intubation attempt, mask ventilation was continued until the infant's color returned to normal.

At this point, the anesthesiologist and neonatologist theorized that the first "successful intubation" actually became an esophageal intubation during repositioning of the ETT, and the lungs had been ventilated through some form of tracheoesophageal fistula. The esophagus was then purposely intubated using a 3.5-mm ETT that was slowly withdrawn until maximum ventilation was achieved.

A chest x-ray taken shortly thereafter revealed no evidence of a trachea, dextrocardia, and a right apical pneumothorax (fig. 1). After transfer to Children's Hospital Medical Center, an esophagobronchogram was performed, revealing bronchi originating from the esophagus (fig. 2). The left lung was clearly visualized, but the right side revealed only a vague bronchial outline due to the pneumothorax. Endoscopy was performed, revealing a mildly hypoplastic larynx leading into an

approximately 1-cm long trachea that ended in a blind pouch. The bronchoscope was then passed down the esophagus and revealed that each main bronchus originated independently from the esophagus. The esophagus was patent to the stomach.

After extensive consultation and discussion, and in light of the uniformly poor surgical results obtained to date with this particular type of bronchoesophageal fistula, a decision not to attempt surgical correction was made jointly by the family and the medical team. The ETT was removed, and the infant died after respiratory arrest.

## DISCUSSION

There are several varieties of tracheoesophageal fistula. It is a relatively common anomaly that occurs approximately once in each 3,000-3,500 live births.<sup>1</sup> Tracheal atresia or agenesis (a variant of a bronchoesophageal or tracheoesophageal fistula) is extremely rare. Three types of primary agenesis have been described.<sup>2</sup> Type I consists of atresia of the proximal trachea, the presence of a distal trachea and carina leading to two completely formed bronchi, and a communication between the distal trachea

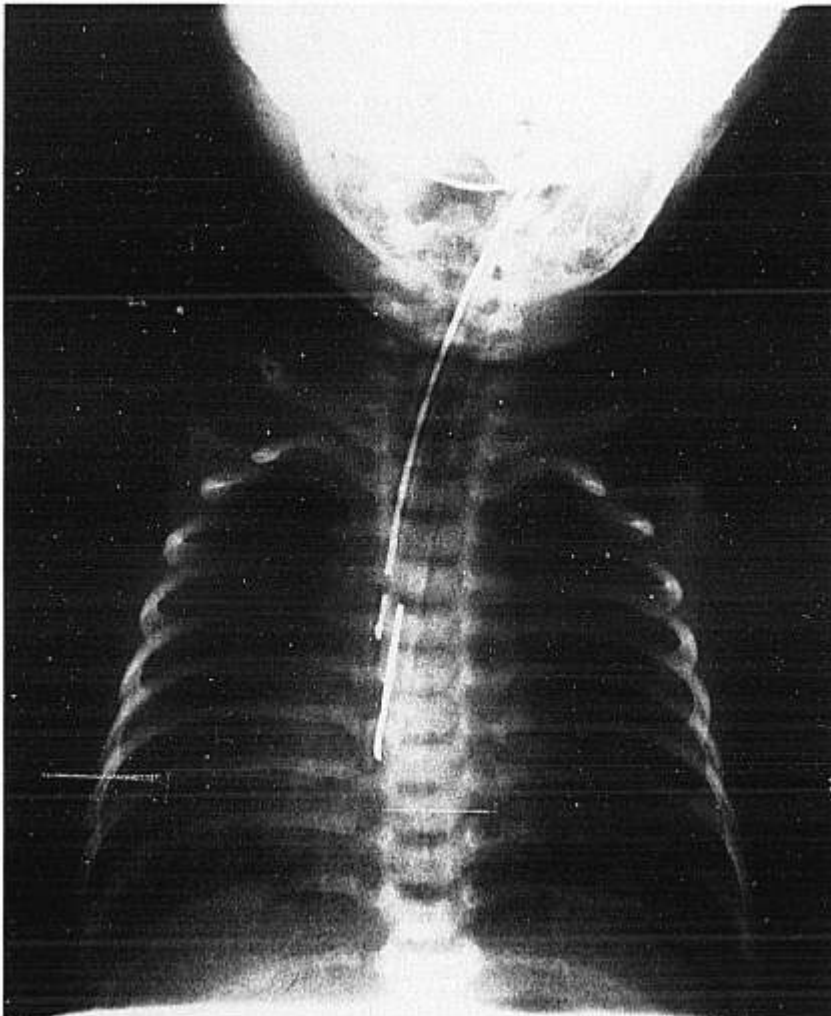
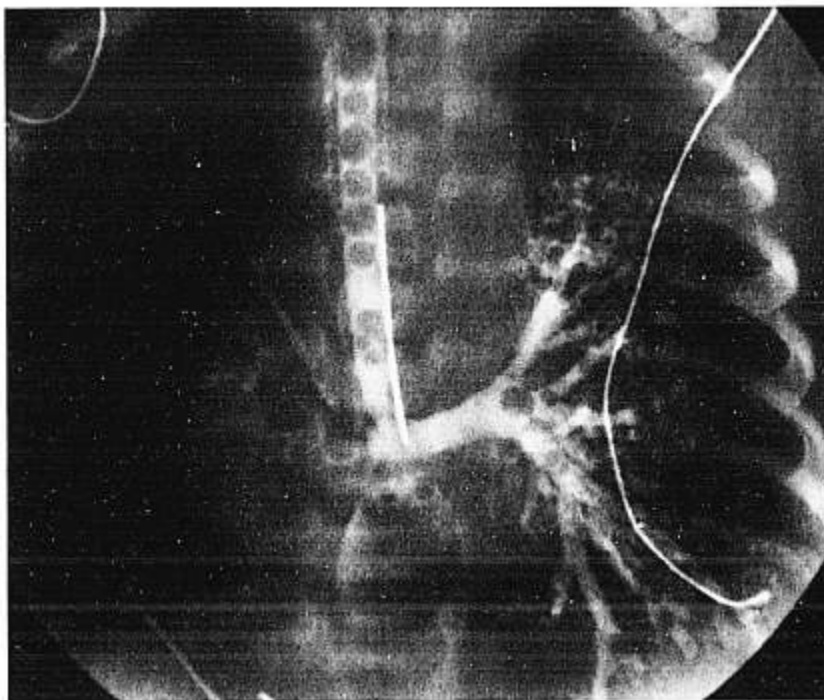


FIG. 1. Revealing absence of identifiable trachea, dextrocardia, right apical pneumothorax and the oro-esophageal tube ending at the juncture of the esophagus and bronchi. (The endoscope subsequently revealed stenosis at this region.)

FIG. 2. Bronchogram revealing bronchi originating from esophagus and proper placement of tube allowing maximum ventilation.



and the esophagus. Type II consists of the absence of a distal trachea but the presence of a "carina" formed by the fusion of the two bronchi in the midline with subsequent communication with the esophagus. Type III consists of an independent communication between each bronchus and the esophagus. No distal carina or trachea is present.

Altman,<sup>3</sup> in 1972, reported a total of 18 cases of tracheal agenesis in the world literature. Of these cases, only four were type III or true bronchoesophageal fistulas. The remainder had an intact carina or distal trachea present. The case presented in this report represents a type III anomaly.

Regardless of the variety of bronchoesophageal fistula, the criteria for establishing the clinical diagnosis and the techniques for resuscitation are similar. The neonate may have the following history or presentation: polyhydramnios is common in the mother; the neonate often presents with initially adequate respiratory efforts without an audible cry that quickly become respiratory distress; and, copious secretions are often present in the oropharynx on delivery. Depending on the type of anomaly, the resuscitator is faced with a neonate whose lungs are difficult to effectively ventilate by mask, the inability to pass an ETT a significant distance below the vocal cords, and subsequent inability to ventilate *via* the ETT. Although these patients can present very difficult airways to manage with mask ventilation, we recommend esophageal intubation only under the most unusual and extreme conditions. Even then, this should be attempted only after the

neonate is hemodynamically stable and adequately oxygenated and after establishing without a doubt that successful tracheal intubation has been ineffective and the inability to ventilate the lungs is not due to a more common cause than tracheal agenesis.

Even if effective resuscitation is instituted, prolonged survival will be dependent on successful surgical reconstruction of the airway. To date, prosthetic tracheal replacement and other reconstructive techniques have generally proven unsatisfactory.<sup>3-5</sup> Although the prognosis of type II and III lesions are at present poor at best, type I lesions present a very different surgical approach, and one case is reported of an infant surviving 1 month after surgical correction.<sup>4</sup> Because type I, II, and III lesions all present in the same fashion, these neonates need to be resuscitated as if they are type I lesions until proven otherwise. Obviously, advances in surgical correction cannot take place if the neonates are not initially resuscitated.

In summary, effective initial and continuous airway resuscitation and management are described in a neonate whose bronchi originated individually from the esophagus. This rare anomaly might have been unrecognized without an autopsy if ventilation had been unsuccessful and the child had died at birth. Long-term survival of infants with tracheal agenesis awaits the development of effective surgical techniques. Anesthesiologists, often the initial resuscitators, require well-developed skills at mask ventilation and should possess knowledge of the multitude of anatomic possibilities that will allow the infant the best possible chances for survival.

## REFERENCES

1. Bray RJ, Lamb WH: Tracheal stenosis or agenesis in association with tracheo-oesophageal fistula and oesophageal atresia. *Anaesthesia* 43:654-658, 1988
2. Floyd J, Campbell DC, Dominy DE: Agenesis of the trachea. *Am Rev Respir Dis* 86:557-560, 1962
3. Altman RP, Randolph JG, Shearin RB: Tracheal agenesis: Recognition and management. *J Pediatr Surg* 7:112-118, 1972
4. Buchino JJ, Meagher DP, Cox JA: Tracheal agenesis: A clinical approach. *J Pediatr Surg* 17:132-137, 1982
5. Fonkalsrud EW, Martelle RR, Maloney JV: Surgical treatment of tracheal agenesis. *J Thorac Cardiovasc Surg* 45:520-525, 1963

Anesthesiology  
73:1282-1285, 1990

## Venous Air Embolism during Hepatic Resection

YOSHIO HATANO, M.D.,\* MASAHIRO MURAKAWA, M.D.,† HAJIME SEGAWA, M.D.,‡  
YUKIO NISHIDA, M.D.,‡ KENJIRO MORI, M.D.§

Venous air embolism (VAE) is classically considered unlikely to occur in patients undergoing abdominal procedures while in the supine position unless the inferior vena cava (IVC) or the pelvic veins are dissected.<sup>1,2</sup> This clinical report and study demonstrate that VAE occurs during hepatic resection without opening the IVC in patients in the supine position.

## CASE REPORT

A 43-yr-old, 50-kg man underwent right lobectomy of the liver for a liver tumor. Abdominal computed tomography (CT) scan and celiac angiography revealed a localized mass in the liver that was thought to be a hepatoma. The patient had a 3-yr history of liver cirrhosis and a 2-yr history of diabetes mellitus. He also had a 10-yr history of mild hypertension that did not require medication. The patient was classified as ASA physical status 2.

The patient received diazepam (10 mg po) and atropine (0.5 mg im). Intravenous catheters were inserted, and the left radial artery was cannulated. Lead II of the ECG was displayed on an oscilloscope. A pulmonary artery catheter was inserted through the right internal jugular vein under local anesthesia. Pulmonary arterial pressure (PAP) and right atrial pressure (RAP) were continuously monitored; cardiac output (CO) by the thermodilution method and pulmonary capillary wedge pressure (PCWP) were measured intermittently.

Anesthesia was induced with diazepam (10 mg iv) and fentanyl (0.2 mg iv) followed by thiopental (300 mg iv). The trachea was intubated after neuromuscular blockade was induced by pancuronium. Anesthesia was maintained with N<sub>2</sub>O (67%), enflurane (0.4-1%) in oxygen, and intermittent doses of fentanyl (total dose, 0.4 mg). Muscle relaxation

was maintained with pancuronium, and the lungs were mechanically ventilated. Hepatic resection using electrocautery was started after clamping the branches of the portal vein and the right hepatic artery running into the right lobe of the liver.

Ninety minutes after the start of hepatic resection, an abrupt increase in PAP (from 18/9 to 32/13 mmHg) was noted. At that time, CO was 9.9 l/min, and blood gas analysis revealed hypoxemia and hypercapnia (PaO<sub>2</sub>, 86 mmHg; PaCO<sub>2</sub>, 52 mmHg). Administration of N<sub>2</sub>O was discontinued, and the patient's lungs were hyperventilated with 100% oxygen. Moments later, systemic arterial pressure (SAP) decreased from 169/87 to 128/70 mmHg, and blood gas analysis showed worsening hypoxia and hypercapnia (PaO<sub>2</sub>, 35 mmHg; PaCO<sub>2</sub>, 68 mmHg). Venous air embolism was suspected, and the infusion tubing was checked, but they were filled with fluid. Removal of air was carefully attempted, and a small amount of frothy air was aspirated from the pulmonary artery but not from the right atrium.

Hyperventilation was continued with 100% oxygen. The SAP increased to 185/103 mmHg, and hypoxia and hypercapnia resolved within 10 min (PaO<sub>2</sub>, 489 mmHg; PaCO<sub>2</sub>, 42 mmHg). The PAP gradually decreased and returned to the previous level 40 min later. During this episode, there were no remarkable changes in PCWP, RAP, and heart rate. No ECG wave form changes or arrhythmia were observed.

The postoperative course in ICU was satisfactory, and no neurologic deficit or pulmonary edema was seen.

## ADDITIONAL STUDIES

After this initial case, we prospectively examined the relationship between VAE and surgery for hepatic resection in 13 patients. Before surgery, all patients gave informed consent to participate in data collection protocols approved by the Ethical Committee on Human Experimentation. All patients were classified as ASA physical status 2. No patients had cardiopulmonary disease.

All patients received diazepam (5 or 10 mg po) and atropine (0.5 mg im). A peripheral vein and the left radial artery were cannulated. Lead II of the ECG was displayed on an oscilloscope. Anesthesia was induced with thiopental (4 or 5 mg/kg), and pancuronium was administered to facilitate tracheal intubation. Anesthesia was maintained with N<sub>2</sub>O (33-50%) and enflurane (0.4-2%) in oxygen,

\* Associate Professor of Anesthesia.

† Assistant of Anesthesia.

‡ Resident in Anesthesia.

§ Professor and Chairman of Anesthesia.

Received from the Department of Anesthesia, Kyoto University Hospital, Kyoto, Japan. Accepted for publication July 13, 1990.

Address reprint requests to Dr. Hatano: Department of Anesthesia, Kyoto University Hospital, 54, Shogoin-Kawahara-cho, Sakyo-ku, Kyoto 606, Japan.

Key words: Complication: embolism. Embolism: air. Surgery: hepatic resection.