

REFERENCES

1. Bray RJ, Lamb WH: Tracheal stenosis or agenesis in association with tracheo-oesophageal fistula and oesophageal atresia. *Anaesthesia* 43:654-658, 1988
2. Floyd J, Campbell DC, Dominy DE: Agenesis of the trachea. *Am Rev Respir Dis* 86:557-560, 1962
3. Altman RP, Randolph JG, Shearin RB: Tracheal agenesis: Recognition and management. *J Pediatr Surg* 7:112-118, 1972
4. Buchino JJ, Meagher DP, Cox JA: Tracheal agenesis: A clinical approach. *J Pediatr Surg* 17:132-137, 1982
5. Fonkalsrud EW, Martelle RR, Maloney JV: Surgical treatment of tracheal agenesis. *J Thorac Cardiovasc Surg* 45:520-525, 1963

Anesthesiology
73:1282-1285, 1990

Venous Air Embolism during Hepatic Resection

YOSHIO HATANO, M.D.,* MASAHIRO MURAKAWA, M.D.,† HAJIME SEGAWA, M.D.,‡
YUKIO NISHIDA, M.D.,‡ KENJIRO MORI, M.D.§

Venous air embolism (VAE) is classically considered unlikely to occur in patients undergoing abdominal procedures while in the supine position unless the inferior vena cava (IVC) or the pelvic veins are dissected.^{1,2} This clinical report and study demonstrate that VAE occurs during hepatic resection without opening the IVC in patients in the supine position.

CASE REPORT

A 43-yr-old, 50-kg man underwent right lobectomy of the liver for a liver tumor. Abdominal computed tomography (CT) scan and celiac angiography revealed a localized mass in the liver that was thought to be a hepatoma. The patient had a 3-yr history of liver cirrhosis and a 2-yr history of diabetes mellitus. He also had a 10-yr history of mild hypertension that did not require medication. The patient was classified as ASA physical status 2.

The patient received diazepam (10 mg po) and atropine (0.5 mg im). Intravenous catheters were inserted, and the left radial artery was cannulated. Lead II of the ECG was displayed on an oscilloscope. A pulmonary artery catheter was inserted through the right internal jugular vein under local anesthesia. Pulmonary arterial pressure (PAP) and right atrial pressure (RAP) were continuously monitored; cardiac output (CO) by the thermodilution method and pulmonary capillary wedge pressure (PCWP) were measured intermittently.

Anesthesia was induced with diazepam (10 mg iv) and fentanyl (0.2 mg iv) followed by thiopental (300 mg iv). The trachea was intubated after neuromuscular blockade was induced by pancuronium. Anesthesia was maintained with N₂O (67%), enflurane (0.4-1%) in oxygen, and intermittent doses of fentanyl (total dose, 0.4 mg). Muscle relaxation

was maintained with pancuronium, and the lungs were mechanically ventilated. Hepatic resection using electrocautery was started after clamping the branches of the portal vein and the right hepatic artery running into the right lobe of the liver.

Ninety minutes after the start of hepatic resection, an abrupt increase in PAP (from 18/9 to 32/13 mmHg) was noted. At that time, CO was 9.9 l/min, and blood gas analysis revealed hypoxemia and hypercapnia (PaO₂, 86 mmHg; PaCO₂, 52 mmHg). Administration of N₂O was discontinued, and the patient's lungs were hyperventilated with 100% oxygen. Moments later, systemic arterial pressure (SAP) decreased from 169/87 to 128/70 mmHg, and blood gas analysis showed worsening hypoxia and hypercapnia (PaO₂, 35 mmHg; PaCO₂, 68 mmHg). Venous air embolism was suspected, and the infusion tubing was checked, but they were filled with fluid. Removal of air was carefully attempted, and a small amount of frothy air was aspirated from the pulmonary artery but not from the right atrium.

Hyperventilation was continued with 100% oxygen. The SAP increased to 185/103 mmHg, and hypoxia and hypercapnia resolved within 10 min (PaO₂, 489 mmHg; PaCO₂, 42 mmHg). The PAP gradually decreased and returned to the previous level 40 min later. During this episode, there were no remarkable changes in PCWP, RAP, and heart rate. No ECG wave form changes or arrhythmia were observed.

The postoperative course in ICU was satisfactory, and no neurologic deficit or pulmonary edema was seen.

ADDITIONAL STUDIES

After this initial case, we prospectively examined the relationship between VAE and surgery for hepatic resection in 13 patients. Before surgery, all patients gave informed consent to participate in data collection protocols approved by the Ethical Committee on Human Experimentation. All patients were classified as ASA physical status 2. No patients had cardiopulmonary disease.

All patients received diazepam (5 or 10 mg po) and atropine (0.5 mg im). A peripheral vein and the left radial artery were cannulated. Lead II of the ECG was displayed on an oscilloscope. Anesthesia was induced with thiopental (4 or 5 mg/kg), and pancuronium was administered to facilitate tracheal intubation. Anesthesia was maintained with N₂O (33-50%) and enflurane (0.4-2%) in oxygen,

* Associate Professor of Anesthesia.

† Assistant of Anesthesia.

‡ Resident in Anesthesia.

§ Professor and Chairman of Anesthesia.

Received from the Department of Anesthesia, Kyoto University Hospital, Kyoto, Japan. Accepted for publication July 13, 1990.

Address reprint requests to Dr. Hatano: Department of Anesthesia, Kyoto University Hospital, 54, Shogoin-Kawahara-cho, Sakyo-ku, Kyoto 606, Japan.

Key words: Complication: embolism. Embolism: air. Surgery: hepatic resection.

and the lungs were mechanically ventilated to maintain PaCO₂ between 35 and 40 mmHg. A thermodilution pulmonary catheter was inserted through the right internal jugular vein. The skin was sealed with transparent wound dressing (Cutifilm, BDF Beiersdorf, Amsterdam, NV) to avoid air entrainment through the skin incision. Partial pressure of end-tidal CO₂ (PETCO₂) was measured (OIR-7101 and TG-701P, Nihon Koden Co., Tokyo, Japan). A precordial Doppler probe (Model 915-L, Parks Medical Electronics Inc., OR) was affixed, and its position over the right atrium was verified from the change in signal produced by a 2-ml bolus injection of 5% glucose solution. The SAP, PAP, RAP, and PETCO₂ were continuously monitored and recorded (Omnirecorder, Nihon-denki Sanei Co., Tokyo, Japan) throughout the surgical procedure.

During hepatic resection using electrocautery, the branches of the portal vein and hepatic artery supplying the lobes of the liver undergoing the resection were clamped. One or two of the three main hepatic veins from the resected lobe of the liver were also clamped; the hepatic veins from the nonresected lobes were not clamped.

All instances of air embolism suggested by either an increase in PAP and RAP, a decrease in PETCO₂, or precordial Doppler sound change were treated by promptly packing the open surface of the liver with saline-soaked sponges. Nitrous oxide was discontinued, and efforts were made to aspirate blood and air from the RA and PA ports of the PA catheter.

RESULTS

The patient profiles and the changes in monitored variables during hepatic resection are summarized in table 1. Patient 1 was described above.

Before hepatic resection, hemodynamic and respiratory

indices of all patients were stable. During hepatic resection using electrocautery, Doppler air sounds were barely identifiable because of radio frequency noise interference.

Patient 4 showed an abrupt decrease in PETCO₂ from 44 to 27 mmHg with a slight increase in PAP during extended left hepatic lobectomy. A small amount of air (approximately 0.5 ml) was detected in 50 ml of blood carefully aspirated from the PA port, but not from the RA port, of the catheter. There was no significant blood loss until this episode; PaCO₂ and PaO₂ values were within normal range, and SAP did not significantly change during this episode.

In patient 6, an abrupt increase in PAP from 37/25 (systolic/diastolic) to 46/33 mmHg and RAP from 15 (mean) to 23 mmHg was noted during extended right hepatic lobectomy. A slight decrease in PETCO₂ from 27 to 25 mmHg occurred simultaneously, but no changes in SAP and heart rate were observed. No air was aspirated from the PA catheter. The increase in PAP and RAP lasted for approximately 5 min, during which the administration of N₂O was discontinued and the lungs were hyperventilated with oxygen.

Four patients (2, 7, 13, and 14) showed a slow decrease in PETCO₂ >5 mmHg in association with a significant decrease in PAP and SAP during hepatic resection. In all these patients, a marked blood loss exceeding 2,000 ml was simultaneously noted during hepatic resection; for example, in patient 13 in whom a blood loss of more than 3,000 ml was observed during hepatic resection with a duration of 50 min, PETCO₂ gradually decreased from 35 to 23 mmHg concomitant with a decrease in PAP from 28/15 to 15/8 mmHg and in SAP from 118/69 to 74/48 mmHg. No air was aspirated from the pulmonary catheter in these patients.

TABLE 1. The Changes in Monitored Variables during Hepatic Resection

No.	Age (yr)	Sex	Diagnosis	Operation	SAP*	PAP†	RAP†	PETCO ₂ †	Air Aspiration
1	43	M	Hepatoma	Right lobectomy	D	I	—	—	Yes
2	59	M	Hepatoma	Trisegmentectomy	D	D	D	D	No
3	68	M	Cholangiocarcinoma	Left lobectomy	—	D	D	—	—
4	58	M	Hepatoma	Left lobectomy	D	—	—	D	Yes
5	70	F	Cholangiocarcinoma	Right lobectomy	D	D	D	—	—
6	48	F	Hepatoma	Right lobectomy	—	I	I	—	No
7	67	M	Hepatoma	Right lobectomy	D	D	D	D	No
8	60	F	Metastatic tumor	Trisegmentectomy	D	D	D	—	—
9	39	M	Hepatoma	Right lobectomy	—	D	D	—	—
10	62	F	Hemangioma	Trisegmentectomy	—	—	—	—	—
11	59	M	Hepatoma	Right lobectomy	—	—	—	—	—
12	57	M	Hepatoma	Trisegmentectomy	D	D	D	—	—
13	74	M	Hepatoma	Right lobectomy	D	D	—	D	No
14	62	M	Hepatoma	Left lobectomy	D	D	—	D	No

* Change greater than 20 mmHg and †change greater than 5 mmHg were considered to be significant.

D = decrease; I = increase; — = no significant change from the value at the start of hepatic resection.

SAP = systemic arterial pressure; PAP = pulmonary arterial pressure; RAP = right atrial pressure; PETCO₂ = partial pressure of end-tidal CO₂.

The remaining seven patients studied showed no significant change in PET_{CO_2} and PAP during hepatic resection. None of the patients studied exhibited ECG changes, hypoxia, or hypercapnia. Their postoperative courses were uneventful, and none showed neurologic deficit or pulmonary complications.

DISCUSSION

When the possibility of VAE is anticipated, early diagnosis of embolization is necessary for immediate treatment.³ In patient 1, the possibility of VAE was not considered preoperatively; thus, a Doppler device was not used and the PET_{CO_2} was not specifically monitored. The occurrence of pulmonary air embolism was not suspected until a marked increase in PAP was associated with other clinical manifestations such as a decrease in SAP, severe hypoxia, and hypercarbia. A correct diagnosis was definitely made by the presence of the froth in the blood that was carefully and slowly aspirated from the pulmonary artery catheter.

A correctly positioned precordial Doppler device has been shown to be the most sensitive method for detecting embolic air⁴; however, the Doppler is not useful during cases when electrocautery is used because of radio frequency interference.³ The continuous measurement of PAP and PET_{CO_2} is less sensitive than the precordial Doppler methods but can provide early information before the manifestations due to the air embolism become clinically severe as seen in patient 1.⁵ Constant PAP and PET_{CO_2} monitoring were therefore employed for the early detection of embolism in the subsequent 13 patients studied.

In two (4 and 6) of the 13 patients studied, unequivocal evidence of VAE was seen during hepatic resection, although the manifestation caused by the air embolism remained within the subclinical range. In patient 6, an abrupt increase in PAP and RAP in association with a slight decrease in PET_{CO_2} occurred during hepatic resection. It is unlikely that the increase in PAP and RAP was due to an increase in the sympathetic discharge caused by operative manipulation or to an increase in preload, since PAP and RAP had been stable from the start of hepatic resection until the abrupt increase in these pressures. Although no air was aspirated from the pulmonary artery catheter, the occurrence of VAE could be further supported by the fact that PAP and RAP returned toward the previous values shortly after hyperventilation with oxygen. By contrast, in patient 4, an abrupt decrease in PET_{CO_2} was a major manifestation observed during hepatic resection. The decrease was associated with a slight increase in PAP, but SAP remained stable. Only a small amount of air was aspirated from the pulmonary artery catheter, which was consistent with other observations of Munson *et al.*⁶ and Marshall and Bedford.⁷

In other patients, a reduction in PET_{CO_2} was seen during hepatic resection accompanied by decreases in PAP and SAP. No air was aspirated from the pulmonary catheter in these patients. Thus, it is possible that a decrease in blood pressure due to the bleeding led to an increase in the physiologic dead space and a reduction in expired CO_2 level in these cases.⁸

During VAE, the change in cardiopulmonary function is influenced by the rate of air infusion. Adornato *et al.*⁹ demonstrated that a bolus injection of air impairs the function of the mitral valve and abruptly reduces CO. In contrast, with slow infusion, the air passes through the right side of the heart and occludes the pulmonary circulation, causing an abrupt increase in PAP and a compensatory increase in CO associated with a decrease in systemic vascular resistance. In this situation, an increase in PAP can provide a semiquantitative estimate of the volume of the air.¹⁰ In our three patients with an increase in PAP, slow entrainment of different volumes of air might have occurred. The two patients with only a slight increase in PAP showed no clinical manifestation associated with air embolism. The initial patient with a marked increase of PAP, however, demonstrated a decreased SAP and pulmonary dysfunction as evidenced by severe transient hypoxia and hypercarbia, indicating a large volume of air in the pulmonary arterial tree.

A necessary condition for the development of VAE is the presence of an open vein, with the pressure in the vein less than ambient pressure. In our 14 patients, accidental opening of the extrahepatic large veins did not occur during hepatic resection. To minimize blood loss, the branches of the portal vein and hepatic artery supplying the resected region of the liver and the hepatic vein from the resected site were clamped. In this situation, the air might enter into the venous system of the non-resected region through the many small veins opening to

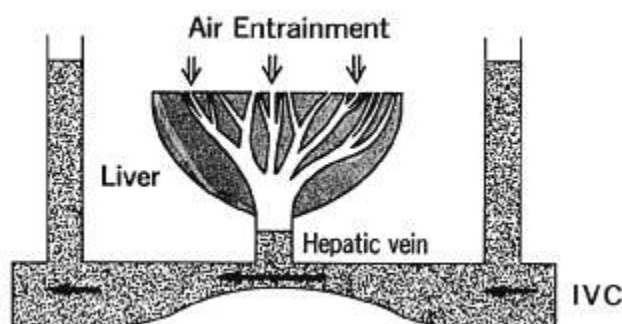


FIG. 1. The Venturi effect. During hepatic resection, the IVC was manipulated or compressed, a maneuver that narrows the portion of the IVC under the junction of hepatic veins. In such a situation, the venous pressure of the constricted portion of the IVC becomes lower than that of the nonconstricted portion, and becomes even subatmospheric when blood passes through the narrowed portion with a high flow rate. The air might be drawn inward by the large number of small hepatic veins open to the atmosphere.

the large section of the liver. These intrahepatic veins exposed during resection are thin walled and anatomically difficult to collapse. During resection, the IVC was manipulated or compressed, which narrowed the portion of the IVC under the junction of hepatic veins. The air might have been drawn inward *via* the large number of small hepatic veins open to the atmosphere, aided by a Venturi effect (fig. 1)

In summary, these cases demonstrate that VAE can occur during hepatic resection in patients in the supine position even if the opening of a large vein does not occur. This study does not define the frequency of VAE during hepatic resection, but it does suggest that this is not a rare event. Therefore, the possibility of VAE must always be considered during hepatic resection and appropriate monitoring is recommended.

REFERENCES

1. Strunin L, Davies JM: The liver and anaesthesia. *Can Anaesth Soc J* 30:208-217, 1983

Anesthesiology
73:1285-1287, 1990

Tracheal Intubation Is Not Invariably Confirmed by Capnography

STEVEN M. DUNN, M.D.,* PHILLIP S. MUSHLIN, M.D., Ph.D.,† LEONARD J. LIND, M.D.,‡
DANIEL RAEMER, Ph.D.§

Capnography is a highly reliable method for confirming tracheal intubation. Continued presence of a CO₂ waveform almost invariably confirms tracheal intubation, and absence of a capnogram strongly suggests esophageal intubation. We could find only one previous report in which

2. Naulty JS, Meisel LB, Datta S, Ostheimer GW: Air embolism during radical hysterectomy. *ANESTHESIOLOGY* 57:420-422, 1982
3. Shapiro HM: Neurosurgical anesthesia and intracranial hypertension, Anesthesia. Edited by Miller RD. New York, Churchill Livingstone, 1986, pp 1563-1620
4. Michenfelder JD, Miller RH, Gronert GA: Evaluation of an ultrasonic device (Doppler) for the diagnosis of venous air embolism. *ANESTHESIOLOGY* 36:164-167, 1972
5. English JB, Westenskow D, Hodges MR, Stanley TH: Comparison of venous air embolism monitoring methods in supine dog. *ANESTHESIOLOGY* 48:425-429, 1978
6. Munson ES, Paul WL, Perry JC, De Padua CB, Rhoton AL: Early detection of venous air embolism using a Swan-Ganz catheter. *ANESTHESIOLOGY* 42:223-226, 1975
7. Marshall WK, Bedford RF: Use of a pulmonary-artery catheter for detection and treatment of venous air embolism: A prospective study in man. *ANESTHESIOLOGY* 52:131-134, 1980
8. Greenway RE, Heeneman H, Keeri-Szanto M: Circulatory monitoring using a carbon dioxide analyzer during planned hypotension: A clinical note. *Can Anaesth Soc J* 24:282-285, 1977
9. Adornato DC, Gildenberg PL, Ferrario CM, Smart J, Frost EAM: Pathophysiology of intravenous air embolism in dogs. *ANESTHESIOLOGY* 49:120-127, 1978
10. Verstappen FTJ, Bernards JA, Kreuzer FB: Effects of pulmonary gas embolism on circulation and respiration in the dog II. Effects on respiration. *Pflugers Arch* 368:97-104, 1977

* Assistant Professor, Department of Anesthesiology, Tufts University School of Medicine; Anesthesiologist, Baystate Medical Center.

† Assistant Professor, Department of Anesthesiology, Harvard Medical School; Anesthesiologist, Brigham and Women's Hospital.

‡ Assistant Professor, Department of Anesthesiology, Harvard Medical School; Anesthesiologist, Brigham and Women's Hospital.

§ Assistant Professor, Department of Anesthesiology, Harvard Medical School; Biomedical Engineer, Brigham and Women's Hospital.

Received from the Department of Anesthesiology, Tufts University School of Medicine; Department of Anesthesiology, Harvard Medical School; Baystate Medical Center, Springfield, Massachusetts; and Brigham and Women's Hospital, Boston, Massachusetts. Accepted for publication July 16, 1990.

Address reprint requests to Dr. Dunn: Department of Anesthesiology, 759 Chestnut Street, Baystate Medical Center, Springfield, Massachusetts 01199.

Key words: Anesthetic techniques: intubation. Measurement techniques: capnography.

a CO₂ waveform was absent despite proper tracheal tube placement and subsequent adequate ventilation.¹ This occurrence related to inadvertent application of PEEP to a loosely fitted (uncuffed) tracheal tube that caused expiratory gases to escape around the tube. The incidents reported here describe two markedly different problems in which decisions based on capnography alone would have led to a misdiagnosis. In each situation, patient safety required expeditious intubation and was jeopardized by unexpected difficulties both in laryngoscopy and subsequent confirmation of intubation.

CASE REPORTS

Case 1. An obese 67-yr-old woman (weight, 108 kg; height, 1.55 m) underwent embolectomy of a clotted femoral popliteal arterial graft after induction of spinal anesthesia (10 mg hyperbaric tetracaine with 0.2 mg epinephrine). Sensory anesthesia to the T6 dermatomal level was produced with only a transient decrease in blood pressure that responded quickly to a fluid bolus (200 ml) and ephedrine (5 mg). Twenty minutes after surgical incision, heparin (5,000 U) was injected intravenously to prevent thrombosis of the artery during application of the cross-clamp. After removal of the clamp, the surgeons requested that the patient be given 20 mg protamine. A 1-mg test dose of prot-