

- modality for arterial insufficiency of the arm in premature infants. *ANESTHESIOLOGY* 61:203-204, 1984
6. Koman LA, Urbaniak JR: Ulnar artery insufficiency: A guide to treatment. *J Hand Surg [Am]* 6:16-24, 1981
  7. Berger JL, Nimier M, Desmonts JM: Continuous axillary plexus block in the treatment of accidental intraarterial injection of cocaine (letter). *N Engl J Med* 318:930, 1988
  8. Macmillan RR, West DM, Desai KM: Brachial plexus block in upper limb ischaemia. *Anaesthesia* 37:215-216, 1982
  9. Yaster M, Maxwell LG: Pediatric regional anesthesia. *ANESTHESIOLOGY* 70:324-338, 1989
  10. Winnie AP: Interscalene brachial plexus block. *Anesth Analg* 49:455-466, 1970
  11. Dalens B, Vanneville G, Tanguy A: A new parascalene approach to the brachial plexus in children: Comparison with supraclavicular approach. *Anesth Analg* 66:1264-1271, 1987
  12. Farrar MD, Scheybani M, Nolte H: Upper extremity block: Effectiveness and complications. *Reg Anesth* 6:133-134, 1981
  13. Vester-Andersen T, Christiansen C, Hansen A, Sorensen M, Meisler C: Interscalene brachial plexus block: Area of analgesia, complications and blood concentrations of local anesthetics. *Acta Anaesthesiol Scand* 25:81-84, 1981
  14. Merrill DG, Brodsky JB, Hentz RV: Vascular insufficiency following axillary block of the brachial plexus. *Anesth Analg* 60:162-164, 1981
  15. Swerdlow M: Complications of local anesthetic neural blockade, Neural Blockade. Edited by Cousins MJ, Bridenbaugh PO. Philadelphia, JB Lippincott, 1980, pp 526-542
  16. Selander D: Axillary plexus block: Paresthetic or perivascular. *ANESTHESIOLOGY* 66:726-728, 1987
  17. McGregor AD, Jones WK, Perlman D: Blood flow in the arm under brachial plexus anaesthesia. *J Hand Surg [Br]* 10:21-24, 1985
  18. Cross GD, Porter JM: Blood flow in the upper limb during brachial plexus anaesthesia. *Anaesthesia* 43:323-326, 1988
  19. Dalens B: Regional anesthesia in children. *Anesth Analg* 68:654-672, 1989
  20. Moore JR, Weiland AJ: Avoidance of vascular complication in replantation, *The Hand and Wrist*. Edited by Sandzen SC. Baltimore, Williams & Wilkins, 1985, pp 58-64

Anesthesiology  
74:370-373, 1991

## Nominal Hemoptysis Heralds Pseudoaneurysm Induced by a Pulmonary Artery Catheter

LAWRENCE B. YELLIN, M.D.,\* JOSEPH J. FILLER, M.D.,† RODGER E. BARNETTE, M.D.‡

Massive hemoptysis secondary to pulmonary artery rupture is a rare but often fatal complication of pulmonary artery catheters (PACs).<sup>1</sup> Several cases in the literature warn of the danger in ignoring nominal hemoptysis as an early sign of pulmonary artery rupture by a PAC.<sup>2,3</sup> In all of these cases, the hemoptysis was accompanied by a new infiltrate or nodule on chest x-ray (CXR). We report a case of delayed fatal hemoptysis secondary to rupture of a PAC-induced pseudoaneurysm, which was heralded by a small amount of hemoptysis in association with a normal postinsertion CXR.

### CASE REPORT

An 82-yr-old male was transferred to our hospital for coronary artery bypass graft surgery (CABG). At the time of cardiac catheterization (1 day prior to surgery), a 7-Fr thermodilution PAC was inserted without incident *via* the right femoral vein. Pulmonary artery pressures were found to be normal. The patient received heparin and nitroglycerin infusions and was transferred to our hospital for urgent CABG surgery. The heparin was discontinued 4 h prior to surgery.

Upon the patient's arrival in the operating room, a radial artery catheter and a right internal jugular introducer were inserted. The baseline activated clotting time (ACT), performed prior to insertion of the central venous introducer, was 115 s. The CXR on admission to our institution revealed the femoral PAC to be in the left main pulmonary artery. In order to have the ability intraoperatively to manipulate the PAC, it was elected to insert a PAC from the right internal jugular site. A 7.5-Fr oximetric PAC (Opticath®, Abbott Critical Care Systems) was floated through the right internal jugular introducer to a wedged position and secured to the skin, at the 47-cm mark, after deflation of the balloon. Initial pulmonary artery pressures were 21/10 mmHg. At no time was the balloon on the PAC reinflated after initial placement. Anesthesia was induced with fentanyl, 50 µg/kg, and vecuronium 0.15 mg/kg was used for neuromuscular blockade.

After induction, at the surgeons' request, a rolled sheet was placed transversely under the patients shoulders. Immediately after the patient was repositioned, the PAC waveform was interpreted by the attending anesthesiologist to reflect a wedged position, and the PAC promptly was withdrawn 5 cm until a characteristic pulmonary artery trace was obtained. Five minutes after surgical positioning of the patient, blood was noted in the endotracheal tube (ETT), and a volume of less than 10 ml was suctioned from the trachea. Observation of the patient for 15-20 min did not reveal additional blood in the airway and a decision

\* Resident.

† Assistant Professor, Department of Anesthesiology.

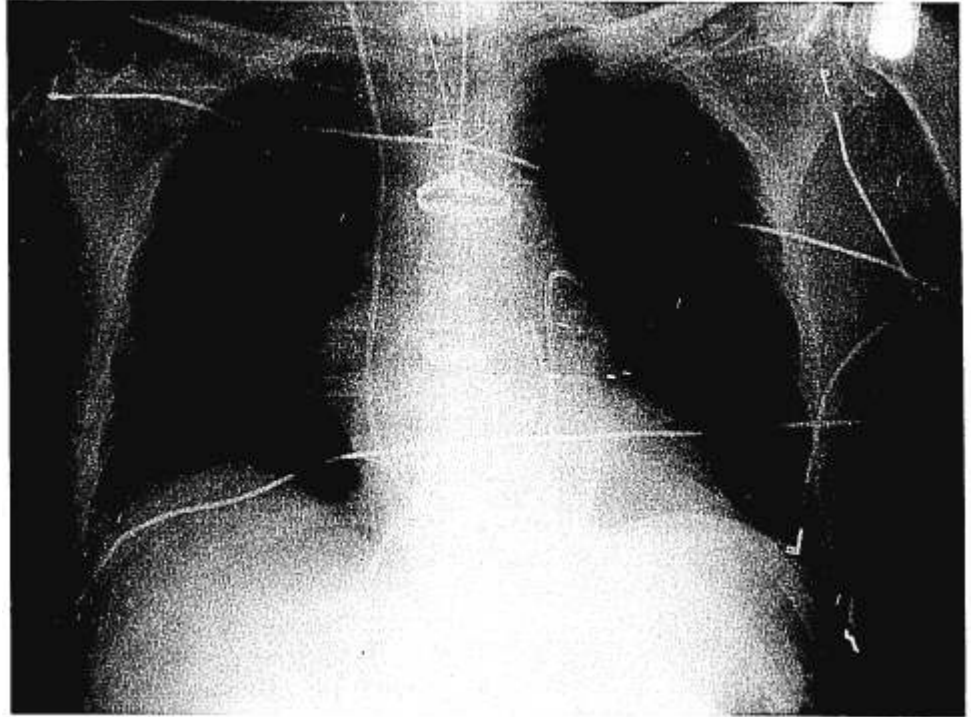
‡ Associate Professor, Departments of Anesthesiology and Internal Medicine.

Received from the Division of Critical Care Medicine, Department of Anesthesiology, and the Department of Internal Medicine, Temple University Health Sciences Center, Philadelphia, Pennsylvania. Accepted for publication October 16, 1990. Performed at Temple University Hospital, 1990.

Address reprint requests to Dr. Barnette: Temple University Hospital, Department of Anesthesiology, 3401 North Broad Street, Philadelphia, Pennsylvania 19140.

Key words: Anesthetic techniques: pulmonary artery catheterization. Complications: hemoptysis; pseudoaneurysm. Pulmonary artery catheter.

FIG. 1. Postoperative portable chest x-ray.



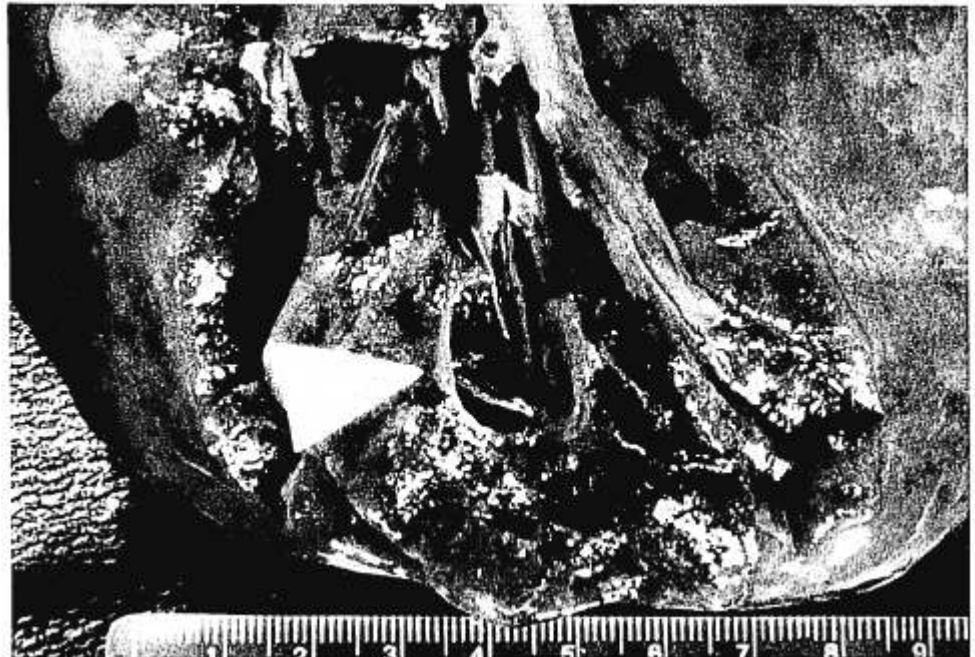was made to proceed with surgery due to the critical nature of the coronary disease. The coronary revascularization proceeded uneventfully, and no additional blood was noted from the patient's ETT at any time during the case.

The patient separated from CPB without difficulty and was transported to the surgical intensive care unit (SICU) with his trachea intubated and lungs manually ventilated. The immediate postoperative CXR (fig. 1) obtained in the SICU showed the femoral PAC to be in the left main pulmonary artery; the PAC inserted from the right in-

ternal jugular site was in the pulmonary outflow tract. Pulmonary artery pressures were normal in the postoperative period. There was no infiltrate or other parenchymal abnormality noted in either lung field.

The balloon on the PAC was not inflated at any time during the postoperative period, and both PACs were removed on the morning of postoperative day 2. The patient was weaned easily from the ventilator, and his trachea extubated 12 h after admission to the SICU. The routine CXR obtained on the morning of postoperative day 2 also was without abnormality. During the early evening of postoperative

FIG. 2. Arrowhead indicates a ruptured pulmonary artery pseudoaneurysm in communication with a subsegmental bronchus of the lower lobe of the right lung.



day 2, while he was sitting in a chair in the SICU, the patient was observed to have a sudden onset of massive hemoptysis followed by bradycardia and hypotension. Despite immediate resuscitative efforts and intubation with a double-lumen ETT the patient expired.

On postmortem examination a ruptured pseudoaneurysm of the right lower lobe pulmonary artery was found. (fig. 2)

## DISCUSSION

Rupture of the pulmonary artery is a recognized complication of pulmonary artery catheterization. There are several cases in the literature describing the occurrence of pulmonary artery perforation by a PAC, and the frequency of this rare but often fatal complication is estimated to be 0.06–0.2% of cases. Mortality is reported at 45–64%, and morbidity in the absence of mortality is significant.<sup>4–6</sup>

Certain factors have been cited as predisposing a patient to pulmonary artery injury from PACs.<sup>7</sup> These include age greater than 60 yr and pulmonary hypertension, both of which are associated with degenerative changes in the vessel wall causing its increased fragility. The presence of systemic anticoagulation has been mentioned,<sup>7</sup> but it is likely that this predisposes to more severe manifestations of injury rather than to pulmonary artery injury itself. Distal location of the PAC tip and excessive manipulation and migration of the PAC also have been implicated as causes of pulmonary artery rupture.<sup>8</sup> The actual mechanism of injury is multifactorial and may include eccentric inflation of the balloon, driving the PAC tip through the arterial wall; inflation of the balloon in the presence of pulmonary hypertension; and over-distention of the balloon, causing pulmonary artery rupture. The actual pressure exerted on pulmonary arterial walls has been investigated by Hardy *et al.*, who found that balloon-generated intraluminal pressures as low as 975 mmHg may cause pulmonary artery rupture.<sup>7</sup> Techniques and equipment for limiting generation of dangerous pressures during inflation of PAC balloons have been described.<sup>9</sup> During cardiac surgery—the most common clinical situation associated with pulmonary artery perforation—injury may occur during manipulation of the heart, while the heart is empty and the PAC is cold and less pliable, allowing for easy distal migration.<sup>8</sup>

PAC-induced pseudoaneurysm formation also is uncommon but differs from arterial rupture in pathology and clinical course. A pseudoaneurysm, or false aneurysm, is a dilatation of a vessel or vascular space in which disruption of the normal endothelial lining has occurred.<sup>10</sup> The wall of the aneurysm is not composed of elements of the blood vessel wall. Containment of blood within the vascular space is achieved by compression from tissues or hematoma or both, surrounding the perforated vessel.<sup>11,12</sup> A layer of fibrin may be present and aid in containment of the hemorrhage. These PAC-induced pseudoaneu-

rysms are of tenuous nature: they have been reported to result in massive hemoptysis hours to weeks after initial injury.<sup>13,14</sup> The initial injury is often heralded by an episode of hemoptysis, which may be either quite small<sup>2</sup> or massive.<sup>8</sup>

Since the first, in 1982,<sup>15</sup> there have been several reports of pseudoaneurysm formation secondary to traumatic injury from a PAC.<sup>3,10,7,13,14</sup> A minority of these cases were associated with nominal hemoptysis heralding a pulmonary artery disruption by a PAC. In all of the reported cases, there was CXR evidence of injury manifested as alveolar infiltrate or nodular density. This has led certain authors to state that characteristic CXR findings are always present after PAC-induced formation of a pseudoaneurysm.<sup>2,14</sup> We conclude, on the basis of the current case, that a nominal amount of hemoptysis, in association with repeated normal CXRs, may not rule out pulmonary artery disruption. Our case further delineates the need to maintain a high index of suspicion whenever hemoptysis of any amount occurs in a patient with a PAC.

We recommend with others<sup>8,13</sup> that survivors of an initial episode of hemoptysis believed related to placement of or balloon inflation of a PAC be considered for a contrast-enhanced computed tomography (CT) scan or pulmonary angiography, or both, at the earliest possible time. Definitive treatment, including surgery or therapeutic embolization,<sup>8,13–15</sup> should be undertaken immediately if a pseudoaneurysm is demonstrated. There is high risk in conservative or expectant management because of the threat of delayed rupture. In one series, 50% of patients with pulmonary artery pseudoaneurysm formation presented with further hemoptysis within 24 h and 90% with further hemoptysis within 3 days.<sup>14</sup>

In summary, we report a case in which a PAC-induced pseudoaneurysm was heralded by a small amount of hemoptysis in association with repeated normal CXRs. Delayed recurrent pulmonary hemorrhage occurred approximately 36 h after initial injury. Aggressive investigation and intervention is recommended in patients with suspected PAC-induced pseudoaneurysm formation.

## REFERENCES

1. Pellegrini RV, Marcelli G, Di Marco RF, Bekoe S, Grant K, Marangoni AG: Swan-Ganz catheter induced pulmonary hemorrhage. *J Cardiovasc Surg* 28:646–649, 1987
2. Rosenbaum L, Rosenbaum SH, Askanazi J: Small amounts of hemoptysis as an early warning sign of pulmonary artery rupture by a pulmonary artery catheter. *Crit Care Med* 9:319–320, 1981
3. Klibaner MI, Hayes JA, Dobnick D, McCormick JR: Delayed fatal pulmonary hemorrhage complicating use of a balloon flotation catheter. *Angiology* 36:358–362, 1985

§ Muller BJ, Gallucci A: Pulmonary artery catheter induced pulmonary artery rupture in patients undergoing cardiac surgery. *Can Anaesth Soc J* 32:258–264, 1985

4. Hannan AT, Brown M, Bigman G: Pulmonary artery catheter induced hemorrhage. *Chest* 85:128-131, 1984
5. McDaniel DD, Stone JF, Faltas AN, Khambatta HJ, Thys DM, Antunes AM, Bregman D: Catheter induced pulmonary artery hemorrhage: Diagnosis and management in cardiac operations. *J Thorac Cardiovasc Surg* 82:1-5, 1981
6. Shah KB, Rao TLK, Laughlin S, El-Etr AA: A review of pulmonary artery catheterization in 6245 patients. *ANESTHESIOLOGY* 61: 271-275, 1984
7. Hardy J-F, Morissette M, Taillefer J, Vaclair R: Pathophysiology of rupture of the pulmonary artery by pulmonary artery balloon-tipped catheters. *Anesth Analg* 62:925-930, 1983
8. Carlson TA, Goldenberg IF, Murray PD, Tadavarthy SM, Walker M, Gobel FL: Catheter induced delayed recurrent pulmonary artery hemorrhage. *JAMA* 261:1943-1945, 1989
9. Walling PT, Paulsen AW, Rorech-Maleck D: A pressure and volume-limited inflation syringe. *ANESTHESIOLOGY* 71:283-288, 1989
10. Bartter T, Irwin RS, Phillips DA, Benotti JR, Worthington-Kirsch RL: Pulmonary artery pseudoaneurysm: A potential complication of pulmonary artery catheterization. *Arch Int Med* 148: 471-473, 1988
11. Anderson WAD, Scotti TM: *Synopsis of Pathology*. St. Louis, CV Mosby, 1968, p 312
12. Ackerman LV, Butcher HR: *Surgical Pathology*. Fourth Edition. St. Louis, CV Mosby, 1968, p 948
13. Davis SD, Neithamer CD, Schreiber TS, Sos TA: False pulmonary artery aneurysm induced by Swan-Ganz catheter: Diagnosis and embolotherapy. *Radiology* 164:741-742, 1987
14. Dieden JD, Louis FA, Renner JW: Pulmonary artery false aneurysms secondary to Swan-Ganz pulmonary artery catheters. *AJR* 149:901-906, 1987
15. Kron IL, Piegrass W, Carabello B: False aneurysm of the pulmonary artery: A complication of pulmonary artery catheterization. *Ann Thorac Surg* 33:629-630, 1982

Anesthesiology  
74:373-375, 1991

## Successful Anesthetic Management of a Patient with Hypokalemic Familial Periodic Paralysis Undergoing Cardiac Surgery

GUILLERMO LEMA, M.D.,\* JORGE URZUA, M.D.,† SERGIO MORAN, M.D.,‡ ROBERTO CANESSA, M.D.§

Hypokalemic familial periodic paralysis is a rare disease, with obvious anesthetic implications. There are few reports commenting on the anesthetic management for patients with this disease when undergoing general surgery,<sup>1-3</sup> and we have found only one report of such a patient subjected to cardiac surgery with extracorporeal circulation.<sup>4</sup> This patient's course was complicated early in the postoperative period by an episode of paralysis, which necessitated prolonged mechanical ventilation.<sup>4</sup>

We report a case of a patient with known hypokalemic familial periodic paralysis, who required coronary revascularization. An impending episode of paralysis on the 1st postoperative day was aborted by aggressive management of plasma potassium concentration.

### CASE REPORT

A 53-yr-old man was admitted with a history of progressive chest pain on exertion that was unresponsive to medical treatment with cal-

cium channel blockers. Beta-adrenergic blockers had been avoided, since they may precipitate symptoms in patients with some types of familial periodic paralysis.<sup>5</sup> Selective coronary angiogram showed critical stenoses of two major vessels with preserved ventricular function.

The patient stated that from infancy he had suffered from acute episodes of intense muscular weakness, either associated with stress or infectious diseases or of no apparent cause. Those episodes frequently were of such severity that he was completely unable to move or even to call for help. He knew that several of his relatives, including his father, brother, and cousin, had experienced similar episodes. Diagnosis of hypokalemic familial periodic paralysis had been made several years ago based on a clear association with decreased plasma potassium concentrations: therefore, therapy consisting of potassium supplements and oral acetazolamide was instituted, and for the last 3 yr he had not experienced symptoms of the disease.

His physical examination was normal; he demonstrated adequate muscular tone and strength. Laboratory tests and radiologic examinations were normal. Plasma potassium was 4.2 mEq/l.

The patient received 1 mg flunitrazepam the night before surgery and meperidine 1 mg/kg intramuscularly (im) before transfer to the operating room. After percutaneous insertion of peripheral venous, radial arterial, and internal jugular catheters, anesthesia was induced with 20 µg/kg fentanyl and 0.1 mg/kg pancuronium. Halothane 0.5-1% in oxygen was added as required for maintenance of anesthesia. No additional muscle relaxants were used. Monitoring included modified V5 ECG lead, continuous arterial and central venous pressures waveforms, urine output, and temperature. Blood gases and plasma potassium concentration were frequently measured throughout the operation and postoperative period and maintained within normal range. Intravenous glucose was avoided, since it is known to precipitate paralysis in these patients.<sup>1,2,6,7</sup>

Cardiopulmonary bypass was carried out under normothermia, since it has been reported that hypothermia may precipitate paralysis.<sup>4</sup> Saint

\* Assistant Professor of Anesthesiology.

† Professor of Anesthesiology; Professor of Engineering.

‡ Professor of Surgery.

§ Instructor of Anesthesiology.

Received from the Departments of Anesthesiology and Cardiovascular Diseases, Catholic University School of Medicine, Santiago de Chile. Accepted for publication October 25, 1990.

Address reprint requests to Dr. Lema: Department of Anesthesiology, Catholic University, Marcoleta 367, P. O. Box 114-D, Santiago, Chile.