

Anesthesiology  
74:621-622, 1991

## Capnography in a Patient after Single Lung Transplantation

E. LYNNE WILLIAMS, M.B., B.S., F.F.A.R.C.S.,\* W. SCOTT JELLISH, PH.D., M.D.,† PAUL A. MODICA, M.D.,‡  
CALVIN C. ENG, M.D.,§ RENE TEMPELHOFF, M.D.¶

Long-term clinical success has been achieved after single lung transplantation (SLT) in humans with end-stage pulmonary fibrosis and emphysema. After SLT, patients have a well-perfused, normally compliant allograft and an abnormally compliant native lung with increased pulmonary vascular resistance. In this case report, we present capnography findings that illustrate these phenomena in a patient who had recently undergone SLT.

### CASE REPORT

A 58-yr-old man with progressive bilateral upper and left lower extremity weakness due to spinal cord compression presented for anterior cervical discectomy. Three weeks earlier, he had undergone left lung resection with SLT for severe emphysema. His posttransplantation course was uneventful, except for an exacerbation of his long-standing cervical cord symptoms. Prior to SLT, he required supplemental O<sub>2</sub>, whereas on the day before the proposed discectomy his respiratory function had improved to the point that he was able to walk without becoming dyspneic. At this time, his arterial blood gas (ABG) on room air was: pH 7.40; CO<sub>2</sub> tension (P<sub>a</sub>CO<sub>2</sub>) 47 mmHg; and O<sub>2</sub> tension (P<sub>a</sub>O<sub>2</sub>) 95 mmHg. Ventilation-perfusion scintigraphy showed normal ventilation and perfusion to the left lung, which contributed 73% of the total ventilation and received 80% of the total pulmonary blood flow. In contrast, a marked decrease was found in the ventilation and perfusion of the right lung (particularly in its upper two thirds), which received 20% of the total pulmonary blood flow and contributed 27% of the total ventilation.

One hour prior to surgery, the patient received diazepam 5 mg orally (po), metoclopramide 10 mg po, and ranitidine 150 mg po. In the operating room, topical anesthesia with Cetacaine® spray was applied to the mouth, pharynx, and right nostril. After sedation with droperidol 5 mg intravenously (iv), diazepam 10 mg iv, and fentanyl 50 µg iv, transtracheal injection of 3 ml 4% lidocaine was performed. Nasal fiberoptic tracheal intubation then was accomplished atraumatically without alteration in the patient's gross neurologic status. Anesthesia then was induced with thiopental 100 mg iv, fentanyl 200 µg iv, and vecuronium 20 mg iv. Maintenance of anesthesia consisted of isoflurane 0.1-0.3% end-tidal (ET), fentanyl infusion 2 µg · kg<sup>-1</sup> · h<sup>-1</sup>, and atracurium as indicated by ulnar nerve stimulation. Fiberoptic

bronchoscopy showed that the surgical anastomosis of the allograft to the left main bronchus was intact and was healing well.

Intermittent positive pressure ventilation was then initiated with an Ohmeda II Plus® (Madison, Wisconsin) anesthesia machine at a tidal volume (V<sub>T</sub>) of 700 ml and a respiratory rate (RR) of 8 breaths per min, which produced a peak inspiratory pressure (PIP) of 26 cmH<sub>2</sub>O. Expiratory gases were monitored with a mass spectrometer (Ohmeda 6000 Multi-Gas Monitor®). At this time, the ET CO<sub>2</sub> tension (P<sub>ET</sub>CO<sub>2</sub>) was 31 mmHg, and an unusual expiratory capnogram was noted (fig. 1). An ABG analysis was performed at an inspired oxygen fraction (F<sub>I</sub>O<sub>2</sub>) of 0.32 and revealed: pH 7.35; P<sub>a</sub>CO<sub>2</sub> 51 mmHg; and P<sub>a</sub>O<sub>2</sub> 217 mmHg. Shortly thereafter, at the same F<sub>I</sub>O<sub>2</sub> and V<sub>T</sub>, the RR was increased to 13 breaths per min. This increased the PIP to 33 cmH<sub>2</sub>O; decreased the ET CO<sub>2</sub> to 25 mmHg; and changed the capnogram to that shown in figure 2. At this time, an ABG analysis showed: pH 7.45; P<sub>a</sub>CO<sub>2</sub> 37 mmHg; and P<sub>a</sub>O<sub>2</sub> 137 mmHg. The RR then was decreased to the previous 8 breaths per min, which produced a capnogram similar to that in figure 1. In addition, the PIP returned to its earlier value of 26 cmH<sub>2</sub>O.

Anterior discectomies were performed at the C4-C5 and C6-C7 levels without complication, and the patient made an uneventful anesthetic recovery. One week later his neurologic status was improved, and evidence of cervical cord compression was decreased. His post-transplantation pulmonary function remained stable.

### DISCUSSION

Biphasic capnogram waveforms secondary to severe kyphoscoliosis<sup>1</sup> and mainstem bronchial intubation<sup>2</sup> have been observed previously in patients in whom the pattern of expiration, as determined by alveolar time constants, was distinctly different in each lung. In our report, similar capnographic findings produced by two different populations of alveoli are described in a patient after SLT. As shown in figure 1, we believe that the first peak represents expired CO<sub>2</sub> from the allograft, which has normal compliance, good perfusion, and good ventilation-perfusion ratios (V/Q). The second peak most likely reflects expired CO<sub>2</sub> from the native lung, because the slanted upstroke is characteristic of the mismatched V/Q ratios and differing alveolar time constants in emphysema.<sup>3,4</sup> Independent of the perfusion characteristics of the two lungs, the differences in their compliance alone could account for the observed biphasic capnogram, with the transplanted lung emptying more rapidly and the more compliant native lung emptying last.

After an increase in RR, the capnogram showed only a single curve (fig. 2). This probably represents preferential exhalation of CO<sub>2</sub> from the transplanted allograft with minimal contribution of expired CO<sub>2</sub> from the native emphysematous lung. The increase in RR apparently produced a decrease in both the P<sub>a</sub>CO<sub>2</sub> and P<sub>ET</sub>CO<sub>2</sub> - P<sub>a</sub>CO<sub>2</sub> difference. This is consistent with increased al-

\* Fellow in Anesthesiology.

† Instructor in Anesthesiology.

‡ Assistant Professor of Anesthesiology.

§ Resident in Anesthesiology.

¶ Assistant Professor of Anesthesiology and Neurological Surgery; Director of Neuroanesthesia.

Received from the Department of Anesthesiology, Division of Neuroanesthesia, Washington University School of Medicine, St. Louis, Missouri. Accepted for publication November 15, 1990.

Address reprint requests to Dr. Modica: Box 8054, 660 S. Euclid Avenue, St. Louis, Missouri 63110.

Key words: Monitoring: capnography. Surgery: single lung transplantation. Ventilation: intermittent positive pressure.

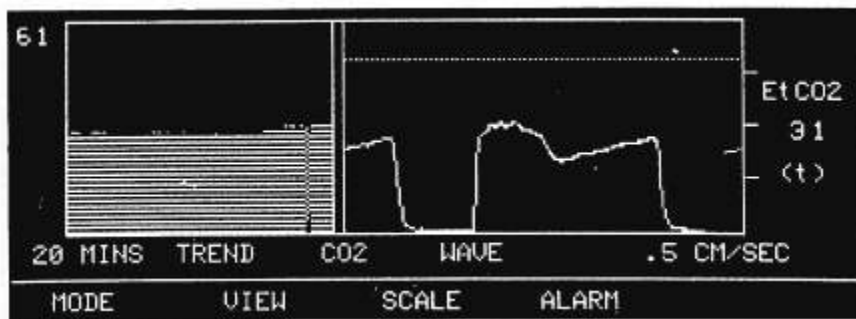


FIG. 1. CO<sub>2</sub> tracings at a respiratory rate of 8 breaths per min and a tidal volume of 700 ml. (Left) The trend of ET<sub>CO<sub>2</sub></sub> over the previous 20 min. (Right) A biphasic capnogram at an ET<sub>CO<sub>2</sub></sub> of 31 mmHg and a graph speed of 0.5 cm/s.

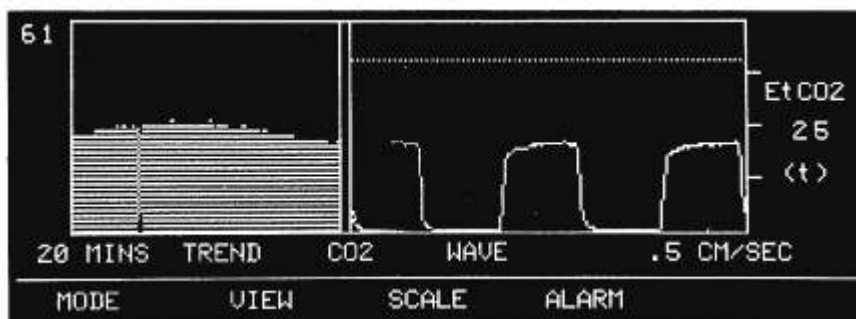


FIG. 2. CO<sub>2</sub> tracings at a respiratory rate of 13 breaths per min and a tidal volume of 700 ml. (Left) The 20-min trend of ET<sub>CO<sub>2</sub></sub>, which has been decreasing for approximately 10 min. (Right) A normal-appearing capnogram at an ET<sub>CO<sub>2</sub></sub> of 25 mmHg and a graph speed of 0.5 cm/s.

veolar ventilation of the allograft and diminished dead space ventilation in the native lung. In this case, as in those of other reports of SLT for emphysema, there was decreased ventilation and perfusion in the native lung, which directed ventilation and perfusion to the allograft.<sup>5,6</sup> Changes in these relationships usually are secondary to complications of the transplant, such as infection or rejection,<sup>5</sup> and not to the change in RR, as we report in this case.

The increase in RR led to an increase in PIP (although there was no alteration in  $V_T$ ) and surprisingly, also produced a decrease in  $Pa_{O_2}$ . This decrease in  $Pa_{O_2}$  was due probably to increased V/Q mismatching associated with hyperinflated areas in the native lung. In contrast to most regions of the emphysematous lung, these hyperinflated areas have low compliance, which can lead to an increase in intrapulmonary pressure (as reflected by the observed increase in PIP) when minute volume is increased.<sup>7</sup> If airway pressure continues to increase in the emphysematous lung, the loss of elastic recoil may also lead to progressive air-trapping and breath-stacking, which can rupture bullae or blebs. In addition, this "auto-PEEP" effect produced by hyperinflation of the native lung also may produce an increase in pulmonary vascular resistance in these areas and a shunting of blood to the more normal regions of the same lung, which may be relatively atelectatic.

In recent years, the relative success of SLT in the treatment of end-stage emphysema has been attributed to improvements in technique, more aggressive immunosuppression, and treatment of infection.<sup>5</sup> As SLT becomes more common, these patients will present for other forms

of surgery, as illustrated by this case. The capnograms in figures 1 and 2 indicate that there are differences in respiratory function between the native and allograft lungs, such that there is preferential ventilation of the allograft. Since the native lung requires more time for exhalation, care should be taken to avoid high RRs and high inspiratory to expiratory ratios when intermittent positive pressure ventilation is administered to SLT patients. This may lead to breath-stacking and air-trapping and thereby produce hyperinflation with possible collapse of the allograft or rupture of emphysematous bullae with pneumothorax.

#### REFERENCES

1. Nichols KP, Benumof JL: Biphasic carbon dioxide excretion waveform from a patient with severe kyphoscoliosis. *ANESTHESIOLOGY* 71:986-987, 1989
2. Gilbert D, Benumof JL: Biphasic carbon dioxide elimination waveform with right mainstem bronchial intubation. *Anesth Analg* 69:829-832, 1989
3. Carlon GC, Ray C, Jr, Midownik S, Kopek I, Groeger JS: Capnography in mechanically ventilated patients. *Crit Care Med* 16:550-556, 1988
4. Paulus DA: Capnography, *International Anesthesiology Clinics: Risk Management in Anesthesia*. Edited by Pierce EC, Jr. Boston, Little, Brown and Co., 1989, pp 167-175
5. Trulock EP, Egan TM, Kouchoukos NT, Kaiser LR, Pasque MK, Ettinger N, Cooper JD, Washington University Lung Transplant Group: Single lung transplantation for severe chronic obstructive pulmonary disease. *Chest* 96:738-742, 1989
6. Veith FJ, Koerner SK, Seigelman SS, Torres M, Bardfield PA, Attai LA, Boley SJ, Takaro T, Gliedman ML: Single lung transplantation in experimental and human emphysema. *Ann Surg* 178:463-476, 1973
7. West JB: *Respiratory Physiology, The essentials*. Baltimore, Williams & Wilkins, 1990, pp 87-113