

CASE REPORTS

Anesthesiology
74:780-782, 1991

Brachial Plexus Compression from a Malpositioned Chest Tube after Thoracotomy

DEVANAND MANGAR, M.D.,* DENNIS L. KELLY, M.D.,† DONOVAN O. HOLDER, M.D.,†
ENRICO M. CAMPORESI, M.D.‡

Brachial plexus injury is usually manifested by complaints of pain, weakness, numbness, and tingling of the shoulder, arms, and hand. Various etiologies of injury include median sternotomy,¹⁻³ internal jugular vein cannulation,⁴⁻⁵ occult fractures of the first and second ribs, and improperly applied sternal retractors.⁴⁻⁵

We report a case of brachial plexus symptoms secondary to inappropriate placement of a chest tube. The presentation of the symptoms mimicked the injury observed after malpositioning of a patient.

CASE REPORT

An otherwise healthy 35-yr-old, 78-kg, 180-cm man presented with a T7-T8 herniated nucleus pulposus with spinal cord impingement, which was documented by magnetic resonance imaging and myelogram. He also complained of back pain radiating posteriorly down both legs, urinary frequency, and difficulty terminating micturition. The scheduled procedure was a T7-T8 discectomy *via* right thoracotomy with bone grafting and somatosensory evoked potential (SSEP) monitoring. Preoperative physical exam was otherwise within normal limits. The hematocrit was 43.5%.

Anesthesia was induced with 375 mg thiopental and 0.75 $\mu\text{g} \cdot \text{kg}^{-1}$ alfentanil. Atraumatic orotracheal intubation with a 39-French, cuffed left-sided double-lumen tube followed the administration of 70 mg atracurium. Anesthesia using controlled mechanical ventilation (rate 8 breaths per min, tidal volume 900 ml) was maintained with a 50%:50% $\text{N}_2\text{O}:\text{O}_2$ mixture, 0.75-1.25 $\mu\text{g} \cdot \text{kg}^{-1} \cdot \text{min}^{-1}$ alfentanil infusion (total 27.5 mg), and muscle relaxation with metocurine (total 32 mg). The duration of surgery was 4 h.

A 20-G right radial artery catheter was inserted after induction. The patient was positioned on a beanbag in the left lateral decubitus. The bed was then flexed to bend the patient to the left, thereby widening the right flank. The kidney rest was elevated to assist in the positioning of the patient. All pressure points were checked and were well padded. The arms were not hyperabducted, and there was no evidence of stretching of the brachial plexus. Breath sounds were bi-

laterally equal after definitive positioning. A right posterolateral thoracotomy incision was made in the sixth intercostal space.

The right lung was collapsed 45 min postincision for 3 h. SSEP monitoring intraoperatively revealed no changes from the beginning of the case. A segment of the seventh rib was used for fusion after the herniated disc was excised. The right lung was reinflated without complication. A chest tube was inserted under direct vision by the surgeons and passed to the apex of the lungs, and the chest was closed. Using the loss-of-resistance technique, the anesthesiologist inserted an intrapleural catheter without complication in the fourth intercostal space and midaxillary line after the chest was closed. Muscle relaxation was then reversed with 5 mg neostigmine and 1 mg glycopyrrolate in divided doses, and the trachea was extubated after spontaneous ventilation resumed.

In the recovery room, movement of all four extremities was noted. Twenty milliliters 0.375% bupivacaine with 1:200,000 epinephrine was injected in the intrapleural catheter and repeated every 8 h for pain control. Thirty minutes after arriving in the recovery room, the patient complained of pain in his right hand, arm, and forearm, along with numbness in the area of the ulnar and median nerve innervation. The neurologic examination of the right arm was significant for decreased flexion at the distal interphalangeal joints (C7-T1), decreased abduction and adduction of the fingers (C8-T1), and decreased sensation to pinprick along the C5-T1 nerve distribution. There was increased pain to arm movement especially with attempted adduction, flexion, and medial rotation of the humerus.

The patient was discharged to the intensive care unit (ICU) for continued neurologic observation. While in the ICU, his major complaint was pain in the right shoulder, arm, and forearm, as well as decreased grip and hand numbness. X-rays revealed no evidence of shoulder dislocation. Dexamethasone 2 mg was administered every 6 h and discontinued 2 days later. The right radial arterial catheter was removed on postoperative day (POD) 1. During the period of intraarterial pressure monitoring (intra- and postoperatively), there was no evidence of vascular compromise or compression.

The patient experienced more pain in the right upper extremity than at the primary incision. He indicated to us that after the intrapleural catheter bupivacaine injection, the pain in his right upper extremity had lessened. Since there was no increase in pain intensity and no further numbness upon injection, intraneural injection was ruled out. We decided to review his chest x-ray to determine whether the intrapleural catheter had been inadvertently inserted into the axilla. The chest x-ray showed adequate placement of the intrapleural catheter. The chest tube, however, appeared at the edge of the pleural space and was curved toward the mediastinum, above the level of the first rib. There was no evidence of brachial plexus traction secondary to humeral dislocation (fig. 1).

Upon palpation of the patient's right axilla, he experienced excruciating pain. He claimed that he could not move his right upper extremity at all, secondary to pain. On the advice of the radiologist and the cardiothoracic surgeon, the chest tube was withdrawn approximately 5 cm (POD 1) (fig. 2). The patient immediately stated that the pressure sensation and pain in the right upper extremity was relieved. The next day (POD 2) he was able to move his arm and forearm and exhibited a stronger grip. Pin-prick evaluation revealed decreased sensation in the radial and ulnar nerve distribution and intact sensation

* Instructor, Department of Anesthesiology, University of South Florida.

† Resident, Department of Anesthesiology, State University of New York Health Science Center.

‡ Professor and Chairman, Professor of Physiology, Department of Anesthesiology, State University of New York Health Science Center.

Received from the Department of Anesthesiology, University of South Florida, Tampa, Florida, and the Department of Anesthesiology, State University of New York Health Science Center, Syracuse, New York. Accepted for publication December 4, 1990.

Address reprint requests to Dr. Mangar: Department of Anesthesiology, University of South Florida, 12901 Bruce B. Downs Boulevard, Medical Center Box 59, Tampa, Florida 33612.

Key Words: Anesthesia: thoracic. Complications: brachial plexus injury. Equipment: thoracotomy tube.

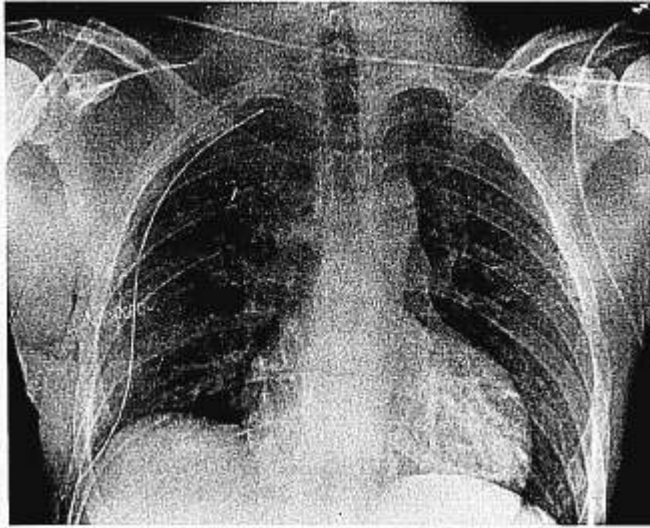


FIG. 1. Position of chest tube after surgery.

in the median nerve distribution. The chest tube was removed on POD 4. By POD 8, the patient's grip was intact, and he had decreased pin-prick sensation only in the ulnar nerve distribution, which persisted until his discharge. The patient was discharged 15 days later. Follow-up done 3 weeks after discharge revealed residual paresthesia in the area of the right ulnar nerve distribution.

DISCUSSION

Brachial plexus injury is associated predominantly with open heart surgery, rib fractures, and excessive retraction and malpositioning of the arms. Complaints of pain, weakness, numbness, and tingling of the shoulders, arms, and hand are common complaints, and the most common site of injury is in the distribution of C8-T1. The most severe form of postoperative brachial plexus palsy is characterized by flaccidity and numbness of the entire arm.

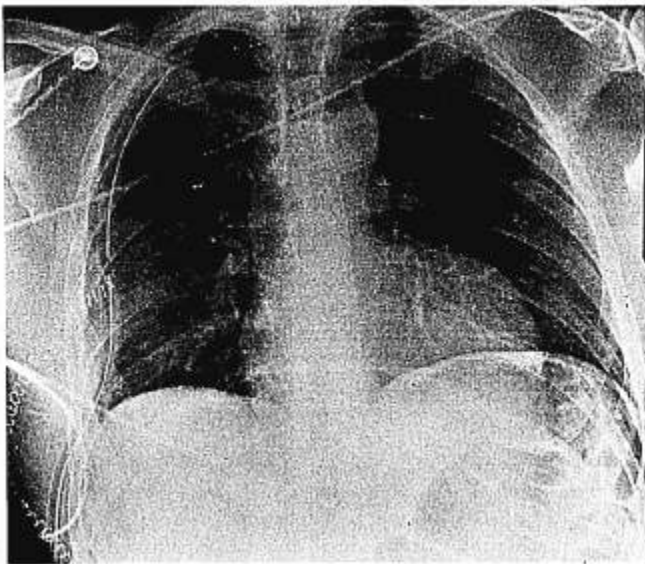


FIG. 2. Chest tube position after being pulled 5 cm.

Less severe forms involve one or more roots or cords with paralysis of the innervated muscle group. Sensory loss is less frequent, probably because of overlapping innervation, but paresthesia is common. Injury to the plexus during noncardiac surgery is rare, with an estimated incidence of 0.03%, and tends to involve the more cephalad plexus roots.¹⁰

In 1899 Horsley,¹¹ and later Jackson and Keats,¹⁰ postulated that stretch is the most common mechanism of brachial plexus injury. In the latter report, compression was noted in two positions: head down with abduction of the arm plus shoulder braces, and abduction of the arm to more than 90° at or above the table.

In our patient, a brachial plexus injury was noted within 30 min after arrival in the recovery room. The etiology was first believed to be secondary to intraoperative positioning, despite the detailed attention with which plexus, vascular traction, and compression were ruled out. Vascular compromise, such as subclavian artery compression, was unlikely because of an intact intraarterial blood pressure tracing on the right.

We believe that this patient's pain and injury was secondary to malpositioning of the thoracostomy tube, which

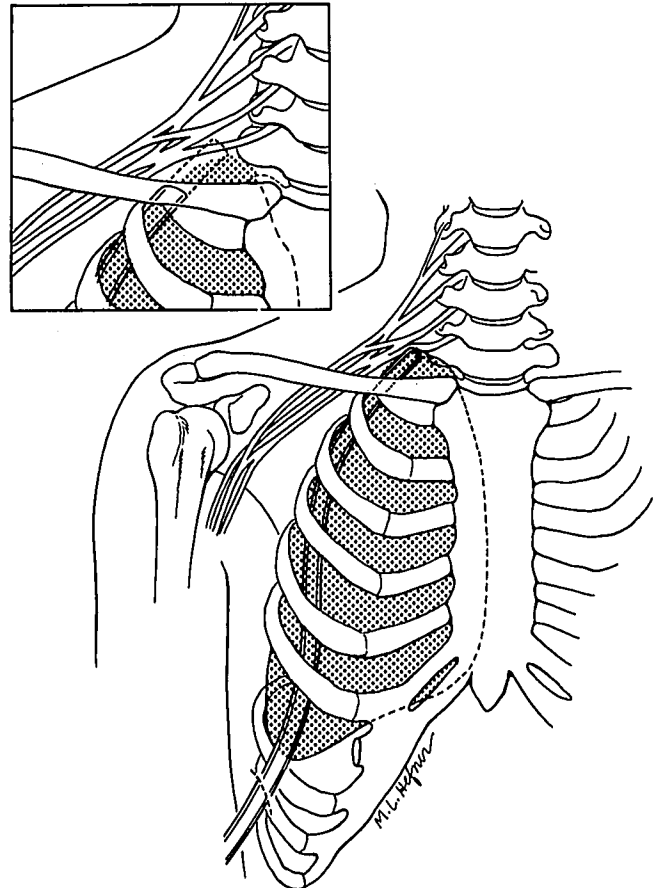


FIG. 3. Compression of brachial plexus due to pushing up of the tube through the pleura.

may have compressed the plexus at the root or trunk level (fig. 3). After the chest tube was repositioned, by withdrawing it approximately 5 cm, the pain was immediately relieved. Partial ulnar nerve injury persisted for more than 3 weeks, ruling out neuropraxia. Also considered in our differential diagnosis was the adequate placement of the thoracostomy tube when the patient was in the left lateral decubitus; however, when the patient was placed supine, the tube may have further compressed the neural bundle. We propose that the mechanism of injury was secondary to the chest tube placement rather than patient positioning. As noted by Kroll *et al.*,¹² the exact mechanism of nerve injury is often unclear; however, since anesthesiologists share in the task of positioning, any problem with patient care in associated brachial plexus palsy should be a joint postoperative effort.

REFERENCES

1. Seyfer AE, Grammer NY, Bogumill GP, Provost JM, Chandry U: Upper extremity neuropathies after cardiac surgery. *J Hand Surg* 10A:16-19, 1985
2. Kirsh MM, Magee KR, Gago O, Kahn DR, Sloan H: Brachial plexus injury following median sternotomy incision. *Ann Thorac Surg* 11:315-319, 1971
3. Tomlinson DL, Hirsch IA, Kodali SV, Slogoff S: Protecting the brachial plexus during median sternotomy. *J Thorac Cardiovasc Surg* 94:297-301, 1987
4. Paschall RM, Mandel S: Brachial plexus injury from percutaneous cannulation of the internal jugular vein. *Ann Emerg Med* 12: 58-60, 1983
5. Briscoe CE, Bushman JA, McDonald WI: Extensive neurological damage after cannulation of the internal jugular vein. *Br Med J* 1:314, 1974
6. Vander Salm TJ, Cereda JM, Cutler BS: Brachial plexus injury following median sternotomy. *J Thorac Cardiovasc Surg* 80: 447-452, 1980
7. Vander Salm TJ, Cutler BS, Okike ON: Brachial plexus injury following median sternotomy: II. *J Thorac Cardiovasc Surg* 83: 914-917, 1982
8. Hanson MR, Breuer AC, Furlan AJ, Lederman RJ, Wilbourn AJ, Cosgrove DM, Loop FD, Estafanous FG: Mechanism and frequency of brachial plexus injury in open-heart surgery: A prospective analysis. *Ann Thorac Surg* 36:675-679, 1983
9. Baisden CE, Greenwald LV, Symbas PN: Occult rib fractures and brachial plexus injury following median sternotomy for open-heart operations. *Ann Thorac Surg* 38:192-194, 1984
10. Jackson L, Keats AS: Mechanism of brachial plexus palsy following anesthesia. *ANESTHESIOLOGY* 26:190-194, 1965
11. Horsley V: On injuries to peripheral nerves. *Practitioner* 63:131-144, 1899
12. Kroll DA, Caplan RA, Posner K, Ward RJ, Cheney FW: Nerve injury associated with anesthesia. *ANESTHESIOLOGY* 73:203-207, 1990

Anesthesiology
74:782-784, 1991

Response of Fetal Heart Rate to Maternal Administration of Esmolol

THOMAS J. LOSASSO, M.D.,* DONALD A. MUZZI, M.D.,* ROY F. CUCCHIARA, M.D.†

Increases in blood pressure (BP) in the patient with an intracranial arteriovenous malformation (AVM) may precipitate intracranial hemorrhage. Esmolol, an ultra-short-acting β -adrenergic blocking agent, has been shown to effectively blunt the increase in systemic BP associated with tracheal intubation and emergence from anesthesia after intracranial surgery.^{1,2}

The effect of esmolol on fetal heart rate (FHR) after maternal administration has not been reported previously. We describe the use of esmolol in a 22-week pregnant woman undergoing resection of a cerebellar AVM and its effect on FHR.

CASE REPORT

A 31-yr-old woman (gravid 2, para 1) had an intrauterine pregnancy at 22 weeks complicated by a subarachnoid hemorrhage. The patient was scheduled for a suboccipital craniectomy for excision of a cerebellar AVM. By ultrasound, the weight of the fetus was estimated to be 350 g.

Maternal BP on the ward prior to surgery ranged between 90/50 and 110/65 mmHg. The patient arrived in the operating room oriented without neurologic deficit. The patient was monitored with electrocardiogram, BP cuff, pulse oximeter, indwelling radial artery catheter, and mass spectrometer. FHR was monitored continuously intraoperatively and for the first 24 h postoperatively using a Hewlett-Packard 8041A FHR monitor. It is our practice to blunt the hemodynamic response to tracheal intubation and to treat emergence hypertension in the patient with an intracranial AVM by using short-acting agents such as esmolol and nitroprusside. Because the fetal response to esmolol was unknown, we elected to administer esmolol prior to inducing anesthesia to determine its effect on FHR in this patient. The patient was positioned supine with left uterine displacement. Prior to the administration of any anesthetic agents, maternal BP was 142/62 mmHg and heart rate (HR) was 94 beats per min. FHR ranged between 139-144 beats per min, and variability was present (fig. 1, awake control 1).

* Consultant in Anesthesiology.

† Professor of Anesthesiology.

Received from the Department of Anesthesiology, Mayo Clinic, Rochester, Minnesota. Accepted for publication December 13, 1990.

Address reprint requests to Dr. Losasso: Department of Anesthesiology, Mayo Clinic, Rochester, Minnesota 55905.