

## Internal Jugular Vein Cannulation Guided by Echocardiography

CHRISTOPHER A. TROIANOS, M.D.,\* JOSEPH S. SAVINO, M.D.†

The internal jugular vein (IJV) is commonly used as a site for intraoperative access to the central circulation because of its accessibility during surgery, direct route into the right atrium, and predictable location. Additionally, the IJV will accommodate large-bore intravenous cannulae for fluid administration or monitoring. Cannulation of the IJV using external landmarks is associated with a success rate of 95%.<sup>1</sup> Unfortunately, landmarks may not be as useful in locating the IJV in anesthetized patients and in patients with abnormal anatomy (*e.g.*, previous neck surgery, obesity, or tortuous carotid artery). There is morbidity and mortality associated with arterial puncture during cannulation of the IJV.<sup>1-4</sup> Theoretically, the risk is increased in patients with carotid disease or coagulopathy. A series of three cases is reported in which standard intraoperative echocardiography equipment was used to guide cannulation of the IJV in patients at increased risk from carotid artery puncture.

## CASE REPORTS

*Case 1.* A 46-yr-old, 66-kg, 183-cm, ASA physical status 4 man presented for repair of type A ascending aortic dissection. The dissection was reported to involve the aortic arch and descending aorta. Past medical history included hypertension, smoking, renal failure, cadaveric renal transplant, and pericardiectomy for uremic pericarditis.

Intraarterial monitoring was established and control of arterial blood pressure was obtained with an infusion of sodium nitroprusside *via* a peripheral intravenous catheter prior to surgery. After induction of anesthesia and tracheal intubation, several attempts were made to cannulate the IJV with an 18-G, 6.35-cm radiopaque catheter over a 20-G introducer needle. The needle was inserted at the apex of the angle formed by the division of the sternocleidomastoid muscle and directed toward the ipsilateral nipple. During one of these attempts, the right carotid artery was cannulated. Despite localization of the carotid artery, first by direct palpation and then by unintentional cannulation, the IJV could not be located.

An echocardiographic unit (Sonos 500 ultrasound imaging system, Hewlett-Packard) was used to locate the IJV. A 5.0-MHz phased-array transducer with a 1.1 × 1.4-cm foot pad was covered by a sterile condom and applied to the skin with ultrasound transmission gel. The transducer was placed over the division of the sternocleidomastoid muscle. The

two dimensional (2-D) images permitted identification of the carotid artery and IJV in both short and long axis (figs. 1 and 2). The IJV was differentiated from the carotid artery by evaluating the orientation of the two vessels on the image screen and noting the compressibility of the vein and pulsation of the artery. The aortic dissection was noted to extend posteriorly into the carotid artery (figs. 1 and 2). The transducer was positioned so that the IJV was visualized in the center of the image screen in short axis. The cannulating needle was advanced into the IJV by directing the needle toward the center line of the transducer and by observing the advancing needle on the image screen. Confirmation of central venous cannulation was made by observing the catheter in the lumen of the IJV on the ultrasound image and by connecting the catheter to a pressure transducer, observing the wave form, and measuring the pressure.<sup>1</sup> The Seldinger technique was used to insert a 8.5-Fr introducer sheath which allowed passage of a pulmonary artery catheter.

*Case 2.* A 70-yr-old, 75-kg, 180-cm, ASA physical status 4E woman presented for emergent repeat coronary artery bypass grafting because of intractable angina refractory to intravenous heparin, intravenous nitroglycerin, and intraaortic balloon counterpulsation. Past medical history included cerebrovascular disease, bilateral carotid endarterectomies, vertigo related to head position, hypertension, degenerative joint disease, and paroxysmal atrial fibrillation.

A decision was made to insert a pulmonary artery catheter prior to induction of general anesthesia. Intravenous heparin therapy was continued because of the risk of coronary artery thrombus formation. Despite a palpable division of the sternocleidomastoid muscle and carotid artery pulse, the right IJV could not be located with a 25-G finder needle after multiple attempts using a medial approach. The intraoperative echocardiographic unit was used in the manner described in case 1. The 2-D images permitted identification of the right IJV and carotid artery by the compressibility of the vein, expansion of the vein with Valsalva's maneuver, and pulsation of the artery. The right IJV was located anterior but medial to the carotid artery, presumably as a result of previous carotid surgery. With ultrasound guidance, the cannulating needle was directed into the IJV, avoiding the carotid artery. Confirmation of central venous cannulation was made as in case 1, and the Seldinger technique was used to insert a 8.5-Fr introducer sheath, which allowed passage of a pulmonary artery catheter.

*Case 3.* A 77-yr-old, 48-kg, 157-cm, ASA physical status 4 woman presented for elective mitral valve replacement and coronary artery bypass grafting. Past medical history included transient right-eye blindness 4 yr prior to admission and total right carotid artery occlusion by Doppler studies. Preanesthetic evaluation revealed bounding carotid artery pulses and bruits bilaterally and a history of right-neck surgery for cervical fusion. The right IJV was chosen for cannulation because of total right internal carotid artery occlusion and the presence of a bruit in the left carotid system.

Two-dimensional ultrasound and Doppler were used to locate the IJV and carotid artery and to evaluate the presence of flow in the right carotid system. The ultrasound transducer was applied as described in case 1, and the 2-D images permitted identification of the right IJV and carotid artery. Plaques were noted on the 2-D image of the carotid artery, and pulsed Doppler analysis revealed the presence of blood flow. These findings were later confirmed by formal carotid Doppler studies. Using ultrasound imaging, the cannulating needle was directed

\* Cardiothoracic Anesthesia Fellow.

† Assistant Professor of Anesthesia.

Received from the Department of Anesthesia, Hospital of the University of Pennsylvania, Philadelphia, Pennsylvania.

Address reprint requests to Dr. Troianos: Department of Anesthesiology, Mercy Hospital of Pittsburgh, 1400 Locust Street, Pittsburgh, Pennsylvania 15219.

Key words: Anesthesia techniques: internal jugular vein cannulation. Monitoring: echocardiography; ultrasound. Vein: internal jugular.

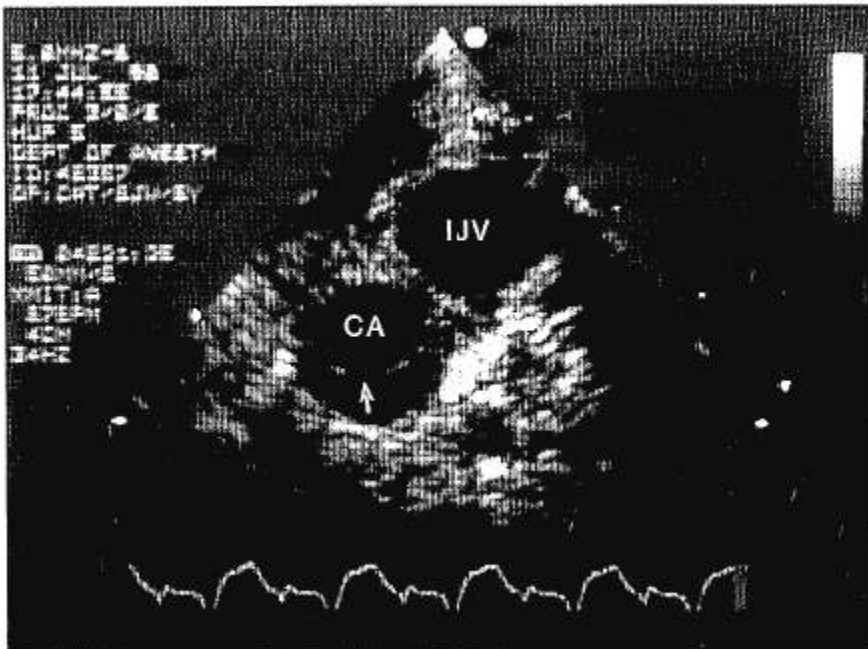


FIG. 1. Two-dimensional ultrasound image of the right internal jugular vein (IJV) and carotid artery (CA). Arrow in the false lumen indicates intimal flap from aortic dissection extending into the carotid artery. Short axis view: top is anterior; right is lateral.

into the IJV with a single pass, and the carotid was avoided. Confirmation of central venous cannulation was made as in case 1, and the Seldinger technique was used to insert a 8.5-Fr introducer sheath, which allowed passage of a pulmonary artery catheter.

#### DISCUSSION

Doppler ultrasound has been used for locating the IJV by identification of the Doppler signal characteristic of

carotid and jugular venous blood flow.<sup>5,6</sup> Two-dimensional ultrasound using a portable ultrasound imaging system is associated with a reduction in the number of attempts needed to locate the IJV, compared to the conventional technique of inspecting external landmarks and palpating the carotid pulse.<sup>7,8</sup> Most transesophageal echocardiography units are equipped with transcutaneous or epicardial probes and therefore are capable of external

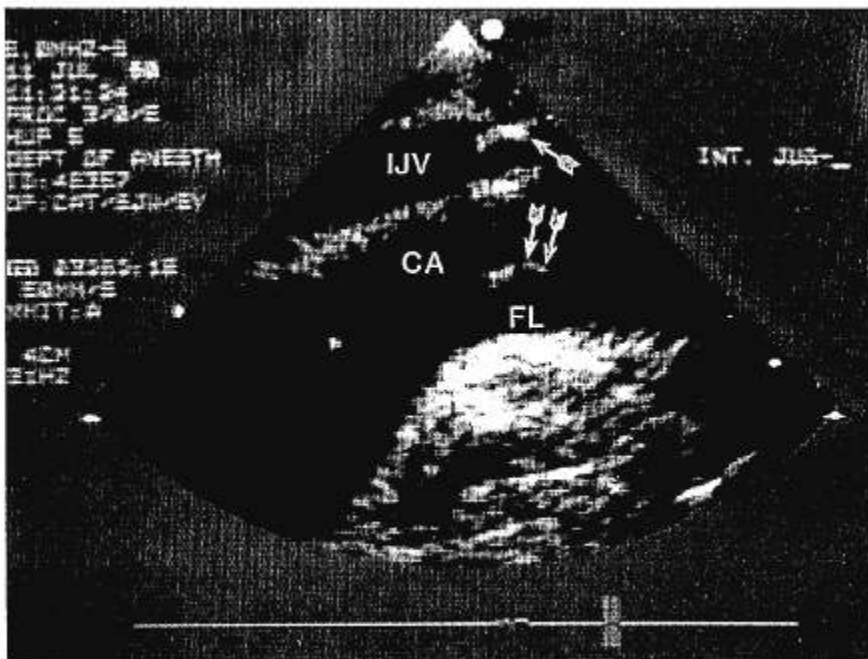


FIG. 2. Two-dimensional ultrasound image of the right internal jugular vein (IJV) and carotid artery (CA). Single arrow indicates catheter entering IJV. Double arrow indicates intimal flap (FL) from aortic dissection extending into CA. Long axis view: top is anterior; right is cephalad.

ultrasound imaging. The cases described in this report demonstrate the utility of ultrasound imaging with echocardiography equipment for cannulation of the IJV. We have used similar imaging techniques in other patients for whom cannulation could not be readily accomplished using external landmarks and in those who had carotid disease or coagulopathy, where avoidance of carotid artery puncture was especially important.

The use of standard intraoperative echocardiography equipment may be valuable for patients at increased risk of complications associated with IJV cannulation as well as for patients in whom traditional methods of locating the IJV have not succeeded. In our experience, the location of the IJV is less predictable in patients who have had prior carotid artery surgery. Intraoperative echocardiography is being used in an increasing number of cardiac surgical patients, and many hospitals have acquired an echocardiographic system dedicated to the operating room. Although the expense of an echocardiographic unit exceeds that of smaller ultrasound units, no additional expense is required for operating room suites that already use intraoperative echocardiography. We conclude that the conventional echocardiography system can be used to facilitate safe cannulation of the IJV.

## REFERENCES

1. Jobs DR, Schwartz AJ, Greenhow DE, Stephenson LW, Ellison N: Safer jugular vein cannulation: Recognition of arterial puncture and preferential use of the external jugular route. *ANESTHESIOLOGY* 59:353-355, 1983
2. McEnany MT, Austen WG: Life-threatening hemorrhage from inadvertent cervical arteriotomy. *Ann Thorac Surg* 24:233-236, 1977
3. Wisheart JD, Hassan MA, Jackson JW: A complication of percutaneous cannulation of the internal jugular vein. *Thorax* 27:496-499, 1972
4. Ellison N, Jobs DR, Schwartz AJ: Cannulation of the internal jugular vein: A cautionary note (correspondence). *ANESTHESIOLOGY* 55:336-337, 1981
5. Ullman JI, Stoelting RK: Internal jugular vein location with the ultrasound Doppler blood flow detector. *Anesth Analg* 57:118, 1978
6. Legler D, Nugent M: Doppler localization of the internal jugular vein facilitates central venous cannulation. *ANESTHESIOLOGY* 60:481-482, 1984
7. Troianos CA, Jobs DR, Ellison N: Ultrasound guided cannulation of the internal jugular vein (abstract). *ANESTHESIOLOGY* 73:A451, 1990
8. Mallory DL, McGee WT, Shawker TH, Brenner M, Bailey KR, Evans RG, Parker MM, Farmer JC, Parillo JE: Ultrasound guidance improves the success rate of internal jugular vein cannulation. *Chest* 98:157-160, 1990