

# Myocardial Perfusion as Assessed by Thallium-201 Scintigraphy during the Discontinuation of Mechanical Ventilation in Ventilator-dependent Patients

William E. Hurford, M.D.,\* Karen E. Lynch, R.N.,† H. William Strauss, M.D.,‡  
Edward Lowenstein, M.D.,§ Warren M. Zapol, M.D.¶

Patients who cannot be separated from mechanical ventilation (MV) after an episode of acute respiratory failure often have co-existing coronary artery disease. The authors hypothesized that increased left ventricular (LV) wall stress during periods of spontaneous ventilation (SV) could alter myocardial perfusion in these patients. Using thallium-201 ( $^{201}\text{Tl}$ ) myocardial scintigraphy, the authors studied the occurrence of myocardial perfusion abnormalities during periods of SV in 15 MV-dependent patients (nine women, six men; aged  $71 \pm 7$  yr, mean  $\pm$  SD). Fourteen of these patients were studied once with  $^{201}\text{Tl}$  myocardial scintigraphy during intermittent mechanical ventilation (IMV) and again on another day, after at least 10 min of SV through a T-piece. One patient was studied during SV only. Thirteen of 14 of the patients (93%) studied during MV had abnormal patterns of initial myocardial  $^{201}\text{Tl}$  uptake, but only 1 patient demonstrated redistribution of  $^{201}\text{Tl}$  on delayed images. The remainder of the abnormalities observed during MV were fixed defects. SV produced significant alterations of myocardial  $^{201}\text{Tl}$  distribution or transient LV dilation, or both, in 7 of the 15 patients (47%). Four patients demonstrated new regional decreases of LV myocardial thallium concentration with redistribution of the isotope on delayed images. The patient studied only during SV also had myocardial  $^{201}\text{Tl}$  defects with redistribution. Five patients (3 also having areas of  $^{201}\text{Tl}$  redistribution) had transient LV dilation during SV. The change from MV to SV was accompanied by increased spontaneous minute ventilation ( $3.5 \pm 2.6$  to  $8.4 \pm 3.7$  l/min) and mean arterial blood pressure ( $90 \pm 2$  to  $98 \pm 3$  mmHg), and decreased  $\text{pH}_a$  ( $7.41 \pm 0.02$  to  $7.37 \pm 0.03$ ) ( $P < 0.05$  by paired  $t$  test for each comparison); the  $\text{PaO}_2$ ,  $\text{PaCO}_2$ , heart rate, 12-lead ECG, tidal volume, vital capacity, and maximum inspiratory pressure were unchanged. The frequent occurrence of new regions of altered myocardial  $^{201}\text{Tl}$  uptake and LV dilation during SV suggests that myocardial perfusion often is altered and myocardial ischemia may be present during SV in MV-dependent patients. (Key words: Heart: blood flow. Lungs: respiratory failure. Ventilation, mechanical: ventilator dependence.)

\* Assistant Professor of Anaesthesia, Harvard Medical School; Assistant Anesthetist, Department of Anesthesia.

† Research Nurse, Department of Anesthesia.

‡ Professor of Radiology, Harvard Medical School; Radiologist, Department of Radiology.

§ Professor of Anaesthesia, Harvard Medical School; Anesthetist-in-Chief, Department of Anesthesia and Critical Care, Beth Israel Hospital, Boston, Massachusetts.

¶ Professor of Anaesthesia, Harvard Medical School; Anesthetist, Department of Anesthesia.

Received from the Departments of Anesthesia and Radiology, Harvard Medical School at the Massachusetts General Hospital, Boston, Massachusetts. Accepted for publication February 8, 1991. Supported by the Foundation for Anesthesia Education and Research, with a specific grant obtained from the BOC Health Care Company, and United States Public Health Service grant HL23591.

Address reprint requests to Dr. Hurford: Department of Anesthesia, Massachusetts General Hospital, Boston, Massachusetts 02114.

THE CARDIOVASCULAR STRESSES of discontinuing mechanical ventilation (MV) may play a major role in preventing the successful separation of MV-dependent patients from the ventilator. Frequently, pulmonary and respiratory muscle function appear adequate. Nevertheless, these patients may remain dependent upon MV for weeks after an episode of acute respiratory failure.<sup>1</sup> Current techniques of withdrawing MV usually use decreasing levels of intermittent mandatory ventilation (IMV) or increasingly longer periods of spontaneous ventilation (SV) alternating with IMV or controlled ventilation.\*\* The change from MV to SV can produce a rapid decrease of intrapleural pressure in MV-dependent patients.<sup>1</sup> Increased abdominal pressure also may occur as a result of increased diaphragmatic and abdominal muscular activity.<sup>2</sup> These changes can produce a sudden increase of left ventricular (LV) preload and afterload. As a result of these changes, central blood volume may increase, leading to increased LV cavity size, altered myocardial perfusion, and possibly myocardial ischemia or dysfunction, particularly in patients with concomitant coronary disease.

To better define the role of altered myocardial perfusion during withdrawal of MV, we performed thallium-201 ( $^{201}\text{Tl}$ ) myocardial scintigraphy during periods of MV and SV in 15 MV-dependent patients. Thallium-201 myocardial scintigraphy is used widely to evaluate the extent and severity of coronary artery disease and myocardial ischemia.<sup>3-6</sup> Thallium-201 is a potassium analog concentrated within myocytes by both passive diffusion and an active process requiring adenosine triphosphate.

Over the normal range of coronary artery blood flow rates in normal hearts, a linear relationship exists between the myocardial uptake of  $^{201}\text{Tl}$  and regional myocardial blood flow at the time of the  $^{201}\text{Tl}$  injection.<sup>7,8</sup> Infarcted areas (scars) fail to accumulate  $^{201}\text{Tl}$  and are detected as defects on scintigraphic images. Hypoperfused but viable areas initially exhibit decreased  $^{201}\text{Tl}$  uptake compared with normal myocardium, but continue to accumulate  $^{201}\text{Tl}$  over time. Normal regions, on the other hand, eliminate  $^{201}\text{Tl}$  as the blood concentration of  $^{201}\text{Tl}$  decreases.

Differences of  $^{201}\text{Tl}$  concentration between areas with

\*\* Morganroth MI, Grum CM: Weaning from mechanical ventilation. *Journal of Intensive Care Medicine* 3:109-120, 1988.

normal and decreased myocardial blood flow that are apparent on images acquired soon after  $^{201}\text{Tl}$  injection will be reduced on scintigraphic images acquired 3 to 4 h later. Myocardial regions initially characterized by reduced  $^{201}\text{Tl}$  uptake, in comparison with other zones, and demonstrating less disparity with well-perfused regions on subsequent later imaging exhibit a phenomenon termed "redistribution." Decreased myocardial  $^{201}\text{Tl}$  uptake in these areas is believed to reflect decreased myocardial perfusion, compared with the myocardial oxygen demand of the region. This phenomenon of redistribution is used to differentiate transiently ischemic from infarcted myocardium.<sup>9</sup>

Transient LV dilation, often resulting from severe and extensive myocardial ischemia, also can be detected by  $^{201}\text{Tl}$  scintigraphy and probably represents severe underlying multivessel coronary artery disease.<sup>10,11</sup> During exercise  $^{201}\text{Tl}$  scintigraphy, transient LV dilation had a sensitivity of 60% and a specificity of 95% for identifying patients with multivessel critical stenoses.<sup>10</sup> Also, in a study by Chouraqui and coworkers, transient LV dilation observed during dipyridamole  $^{201}\text{Tl}$  scintigraphy had a sensitivity of 87% for identifying patients with multivessel coronary artery disease.<sup>11</sup>

The ability of  $^{201}\text{Tl}$  scintigraphy to detect ischemic areas depends on the relationship between myocardial oxygen demand and available coronary blood flow.<sup>4</sup> Usually only critical coronary artery lesions or prior myocardial infarction are detectable by  $^{201}\text{Tl}$  scans performed during basal resting conditions. In clinical studies, exercise often is used to increase myocardial oxygen demand and accentuate regional differences of coronary artery blood flow. Myocardial blood flow in normally perfused areas will increase in response to the greater oxygen demand. Areas supplied by a stenotic coronary artery, on the other hand, may be unable to increase flow to match the greater oxygen demands of the myocardium. In our study, discontinuing MV and permitting patients to breathe spontaneously were used as the hemodynamic stimulus to increase myocardial oxygen demand. We hypothesized that if this was a clinically significant hemodynamic stress, areas of  $^{201}\text{Tl}$  redistribution or LV dilation would be detected by  $^{201}\text{Tl}$  scintigraphy performed during SV. If these changes reflect transient myocardial ischemia, patients exhibiting new regions of  $^{201}\text{Tl}$  redistribution or LV dilation after a brief period of SV might have impaired ability to separate successfully from MV.

## Materials and Methods

### PATIENT SELECTION

Fifteen medical and postsurgical patients were studied with  $^{201}\text{Tl}$  myocardial scintigraphy. These patients ful-

filled the following criteria: 1) they were not pregnant, they were at least 18 yr old, and their lungs had been mechanically ventilated for at least 7 days; 2) they had a spontaneous ventilatory rate between 10 and 30 breaths per min and a tidal volume greater than 4 ml/kg when separated from ventilatory support; 3) they had stable or improving acute pulmonary disease as evidenced by a stable or improving clinical course, chest roentgenograms, and arterial blood gas tensions; 4) they were hemodynamically stable as evidenced by the ability to sustain a systolic blood pressure greater than 90 mmHg without the use of vasopressors; 5) their tracheas were intubated with appropriately sized endotracheal tubes; and 6) they demonstrated prior documented ability to breathe spontaneously for at least 10 min during previous attempts to withdraw MV. The study was approved by the Massachusetts General Hospital Subcommittee on Human Studies, and all subjects and/or their relatives provided informed consent.

### DEMOGRAPHICS AND PHYSIOLOGIC DATA

Historic data collected included age, sex, diagnosis, and medical history (including any history of smoking, asthma, chronic obstructive pulmonary disease, or coronary artery disease), day of hospitalization, day of intubation, and medication record.

The physiologic data we measured during MV and SV included the heart rate and 12-lead electrocardiogram (nominal frequency response 0.05–100 Hz), arterial blood pressure measured with an arm cuff, arterial blood gas tensions, pH, and lactate levels. Respiratory parameters measured during MV were the inspired oxygen concentration, mandatory ventilatory rates and tidal volumes, as well as peak and end-expiratory airway pressures. The patient's spontaneous tidal volume, vital capacity, and maximal inspiratory force were measured before and immediately after the trial of SV.

We recorded whether the patient eventually was separated successfully from MV, whether the patient survived to be discharged from the hospital, the hospital charges, the duration of tracheal intubation and MV, and the length of hospital stay. The patients' hospital charges were the sum of the dollar amounts that the patient was billed for hospitalization, including charges for the hospital bed, operating room, radiologic studies, respiratory therapy, materials services, pharmaceutical products, laboratory tests, and transfusion therapy. Physician charges were not included.

### THALLIUM-201 MYOCARDIAL SCINTIGRAPHY

Each patient was studied with  $^{201}\text{Tl}$  myocardial scintigraphy during MV and, on a separate day (to limit background activity), after 10 min of spontaneous breathing. Although the order of the scintigraphic studies was ran-

domized, most patients (11 of 14) first were studied after SV. All patients fasted at least 4 h before each study. For each study, 2 mCi (74 MBq) thallous-201 chloride was injected intravenously. At least 7 min after injection of the radioisotope, images were collected in the anterior, 45-degree left anterior oblique (LAO), and 70-degree LAO projections with a mobile gamma camera (Series 420 Mobile; Ohio Nuclear, Solon, OH) using a general all-purpose collimator. Each view was collected for 8 min. The imaging was repeated 3 h after the injection of <sup>201</sup>Tl to document myocardial redistribution of the radioisotope.<sup>4</sup> Repeat images were matched to those previously acquired by duplicating the patient's position and camera orientation and by comparing brief preliminary images with those already acquired.

During SV, the patient breathed spontaneously through a T-piece to eliminate the resistance of demand valves. After 7 min of SV, 2 mCi of thallous-201 chloride was injected. Five milliliters of arterial blood was withdrawn from a radial artery for analysis of blood gas tensions, pH, and lactate levels. After a total of 10 min of SV, the mandatory ventilatory rate and positive end-expiratory pressure were returned to their previous levels. Initial and delayed imaging were performed as described above while the patient received MV. During SV, the heart rate, respiratory rate, and blood pressure were monitored. The arterial oxyhemoglobin saturation (SpO<sub>2</sub>) was monitored continuously by pulse oximetry, and the inspired oxygen concentration was increased if the arterial SpO<sub>2</sub> decreased to less than 90%. A 12-lead electrocardiogram was recorded before and at the end of the 10-min period of SV. The ST-segments of the electrocardiograms were evaluated according to standard criteria for evidence of myocardial ischemia (planar or downsloping ST-segment depression ≥ 1 mV or ST-segment elevation ≥ 2 mV compared with baseline tracings, and persisting for at least 60 ms beyond the J point in one or more leads).<sup>12</sup>

#### INTERPRETATION OF THALLIUM-201 SCINTIGRAMS

Scintigraphic images were interpreted with the use of both qualitative and quantitative methods. For qualitative analysis, each <sup>201</sup>Tl scan was interpreted by two observers without their knowledge of the patients' ventilatory patterns. The scans were analyzed on two separate occasions at least 6 weeks apart. Scans showing no initial <sup>201</sup>Tl defects were considered normal. Those showing perfusion defects were further characterized as demonstrating redistribution of the radiolabel if the defect was less apparent on subsequent delayed images. Transient LV dilation was considered to be present when there was a definite reduction in the size of the left ventricle between the initial image and the redistribution image acquired 3 h later. In

this study, the consensus opinion of both observers had to agree on both occasions for a defect or LV dilation to be considered present.

Quantitative analysis was performed with the use of a computer program (SOPHY®; Cedars Processing, Sopher Medical Systems, Inc.) that defined initial <sup>201</sup>Tl defects by comparing the patient's initial <sup>201</sup>Tl uptake with the lower limit of established normal values.<sup>13,14</sup> The initial <sup>201</sup>Tl images acquired during MV and SV also were compared.

After image processing with an interpolative background subtraction algorithm and nine-point weighted-average smoothing, maximal count, 60-point circumferential profiles (6 degrees per interval) of the initial <sup>201</sup>Tl images were constructed. Each point in the profile represented the maximal number of counts per pixel along a radial line beginning in the center of the left ventricle and ending on the outer surface of the left ventricle. The profiles were normalized so that the maximal <sup>201</sup>Tl activity in each image equaled 100% and were aligned so that the LV apex corresponded to 90 degrees in each view. Thallium activity was plotted clockwise from 0 to 360 degrees as the percentage of maximum counts *versus* angle. Three myocardial regions were defined for each view (fig. 1). The arc from 210 to 330 degrees was considered to represent the LV inflow and outflow tracts and was excluded from additional analysis. A <sup>201</sup>Tl defect was defined as any 18-degree segment (three contiguous radii) of the profile falling at least 2 SD below the mean initial distributions of a population of normal subjects.<sup>14</sup> Data for this population were preprogrammed as part of the computer software.

Although the lower limit of normal usually is within 75% of the maximum uptake in each view, it extends from as low as 55% of the maximum uptake at the apex in the 45-degree LAO view to as high as 80% of the maximum uptake for the inferior wall on the anterior view. Findings from a study were considered abnormal if there

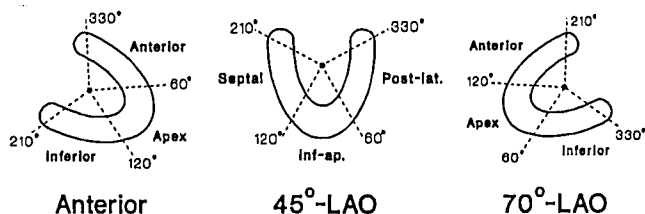


FIG. 1. Each myocardial <sup>201</sup>Tl image was divided into three regions for quantitative analysis. Circumferential profiles of maximal <sup>201</sup>Tl activity were plotted clockwise as a function of angle (6° per interval) from 0 to 360°. The profiles were normalized so that the maximal <sup>201</sup>Tl activity in each image equalled 100% and aligned so that the apex corresponded to 90° in each view. The arc from 210 to 330° represents the LV inflow and outflow tracts and was not interpreted. LAO = left anterior oblique; Post-lat. = posterolateral; Inf = inferior.

TABLE 1. Redistributing Myocardial Thallium-201 Defects and LV Dilation During MV and SV

Patient	Age, yr	Sex	Diagnosis	History of CAD	Days of MV Before SV Study	Thallium Defects		Outcome
						MV	SV	
1	85	F	Pneumonia	No	57	None	None	Died
2	60	F	COPD; pneumonia	No	13	None	None	Died
3	71	F	COPD; pneumonia	Yes	19	None	Apical, septal, and posterolateral; dilated LV cavity	Died
4	69	F	Pneumonia	No	68	None	Septal and anterior	Died
5	73	M	s/p AAA	No	23	Not done	Inferior and inferoapical	Died
6	72	F	Incarcerated hernia	No	20	None	None	Discharged
7	72	F	s/p AAA	Yes	9	None	None	Discharged
8	69	F	PVD	Yes	14	None	Septal and inferior; dilated LV cavity	Died
9	71	M	ASMI	Yes	24	None	None	Discharged
10	75	F	? CHF; pneumonia	Yes	26	None	None	Died
11	69	F	s/p Gastrectomy	No	33	None	None	Discharged
12	83	M	s/p Gastrectomy	Yes	10	Anterior	Anterior; dilated LV cavity	Died
13	62	M	s/p Esophagogastrectomy	No	23	None	None; dilated LV cavity	Died
14	60	M	Ileal perforation	No	48	None	None	Died
15	69	M	Pseudomembraneous enterocolitis	Yes	28	None	None; dilated LV cavity	Discharged

MV = mechanical ventilation; SV = spontaneous ventilation; CAD = coronary artery disease; COPD = chronic obstructive pulmonary disease; AAA = abdominal aortic aneurysm; PVD = peripheral vascular

disease; ASMI = anteroseptal myocardial infarction; CHF = congestive heart failure; s/p = status post.

were at least two abnormal 18-degree arcs in any of the three views. Operator interactions with the program were limited to locating the center and outer border of the left ventricle and aligning the LV apex.

For the purposes of this study, a "positive" scan during separation from MV was defined as demonstrating areas of decreased initial  $^{201}\text{Tl}$  uptake during SV by both qualitative and quantitative interpretations, with redistribution of the label on delayed imaging and/or transient LV dilation during SV. All other scans were considered to be "negative" for significant scintigraphic changes during SV. A negative  $^{201}\text{Tl}$  scan may have displayed initial defects of  $^{201}\text{Tl}$  uptake but did not exhibit redistribution of the label on delayed imaging (fixed defects) or transient LV dilation, and, thus, was unaffected by the ventilatory mode. The interpretations of the thallium scans were not shared with the patients' primary physicians.

#### STATISTICAL ANALYSIS

All results are expressed as the mean  $\pm$  SD. Differences between parameters measured during MV and SV were analyzed by the paired Student's *t* test.  $P < 0.05$  was considered significant. Outcome data were analyzed by the chi-squared test. ††

## Results

### PATIENT CHARACTERISTICS

Nine women and six men were studied (age  $71 \pm 7$  yr; range, 60–84 yr; table 1). The patients' lungs had been ventilated mechanically for 9–68 days. Seven patients had a history of coronary artery disease documented either by a history of myocardial infarction or evidence of prior myocardial infarction on their electrocardiograms. Only 1 patient (patient 9) was admitted initially for cardiac symptoms. Most patients had been receiving cardiac medications (calcium channel blockers, 9 patients; digoxin, 7 patients; oral nitrates, 5 patients; beta-adrenergic blockers, 3 patients). Ten patients were treated previously for chronic obstructive pulmonary disease. Two of these patients (patients 2 and 3) were admitted for pneumonia that exacerbated the symptoms of their chronic obstructive pulmonary disease. At the time of the study, 11 of the patients were receiving inhaled bronchodilators and 6 were receiving theophylline preparations.

### PHYSIOLOGIC CHANGES DURING SV

The results of the hemodynamic and respiratory measurements obtained during MV and SV are shown in table 2. These patients had a spontaneous respiratory rate of  $32 \pm 8$  breaths per min, a spontaneous tidal volume of  $280 \pm 140$  ml, and a maximal inspiratory force of  $-24 \pm 6$  cmH<sub>2</sub>O. The physiologic changes associated with the

†† Hintze JL. NCSS Version 5.01. Kaysville, JL Hintze, 1987.

TABLE 2. Hemodynamic and Respiratory Measurements during MV and SV

Variable	MV	SV
Heart rate (beats per min)	92 ± 14	98 ± 18*
Systolic arterial pressure (mmHg)	144 ± 16	150 ± 27
Diastolic arterial pressure (mmHg)	63 ± 11	73 ± 13*
Mean arterial pressure (mmHg)	90 ± 8	98 ± 12*
Spontaneous respiratory rate (breaths per min)	15 ± 12	32 ± 8*
Spontaneous tidal volume (ml)	270 ± 80	280 ± 140
Spontaneous minute ventilation (l/min)	3.3 ± 2.8	8.4 ± 3.7*
Vital capacity (ml)	640 ± 270	530 ± 260
Maximum inspiratory force (cmH <sub>2</sub> O)	-27 ± 9	-24 ± 6
PaO <sub>2</sub> (mmHg)	101 ± 23	101 ± 54
PaCO <sub>2</sub> (mmHg)	44 ± 9	48 ± 8
pH <sub>a</sub>	7.41 ± .06	7.37 ± .06*
Arterial lactate (mM)†	—	0.88 ± .26

Values are mean ± SD, n = 14.

\* P < 0.05 by paired t test.

† Normal range 0.5–2.2 mM.

transfer from MV to SV were relatively minor. Heart rate increased 6% (from 92 to 98 beats per min). Diastolic and mean arterial pressure increased 14% and 9%, respectively, whereas systolic pressure did not change. The spontaneous respiratory rate and spontaneous minute ventilation increased significantly. Arterial pH decreased slightly (from 7.41 to 7.37) and PaCO<sub>2</sub> increased from 44 to 48 mmHg, but the latter increase was not significant. Arterial lactate concentration remained within the normal range during SV (0.88 ± 0.26 mM; normal range: 0.5–2.2 mM). The 12-lead electrocardiograms obtained after 10 min of SV did not demonstrate new ST-segment changes diagnostic of myocardial ischemia.

#### THALLIUM-201 MYOCARDIAL SCINTIGRAPHY

Fourteen patients were studied with <sup>201</sup>Tl myocardial scintigraphy during MV and after at least 10 min of spontaneous breathing through a T-piece (SV). One patient (patient 5) was studied only once, after 10 min of SV, because MV was discontinued after the first study was performed. Only 1 patient (patient 1) had initially normal <sup>201</sup>Tl uptake during both MV and SV (fig. 2). By our quantitative criteria, the remaining 13 patients (93%) had abnormal initial patterns of myocardial <sup>201</sup>Tl uptake during both MV and SV. During MV, 12 of these patients demonstrated only fixed <sup>201</sup>Tl defects. One patient (patient 12) demonstrated redistribution of <sup>201</sup>Tl on delayed imaging during MV. This patient had a similar redistributing <sup>201</sup>Tl defect and transient LV dilation during SV.

Ten minutes of SV produced significant alterations of myocardial <sup>201</sup>Tl distribution or transient LV dilation (a "positive" scan with discontinuation of MV) in 7 of the

15 patients (47%) (table 1). In 4 of these patients, new regions of decreased myocardial <sup>201</sup>Tl uptake developed during SV, compared with the scans performed during MV, with redistribution of the label on delayed images. Figure 3 displays the circumferential profiles of the initial <sup>201</sup>Tl scans of 1 such patient. The 1 patient in whom a baseline <sup>201</sup>Tl study was not performed during MV (pa-

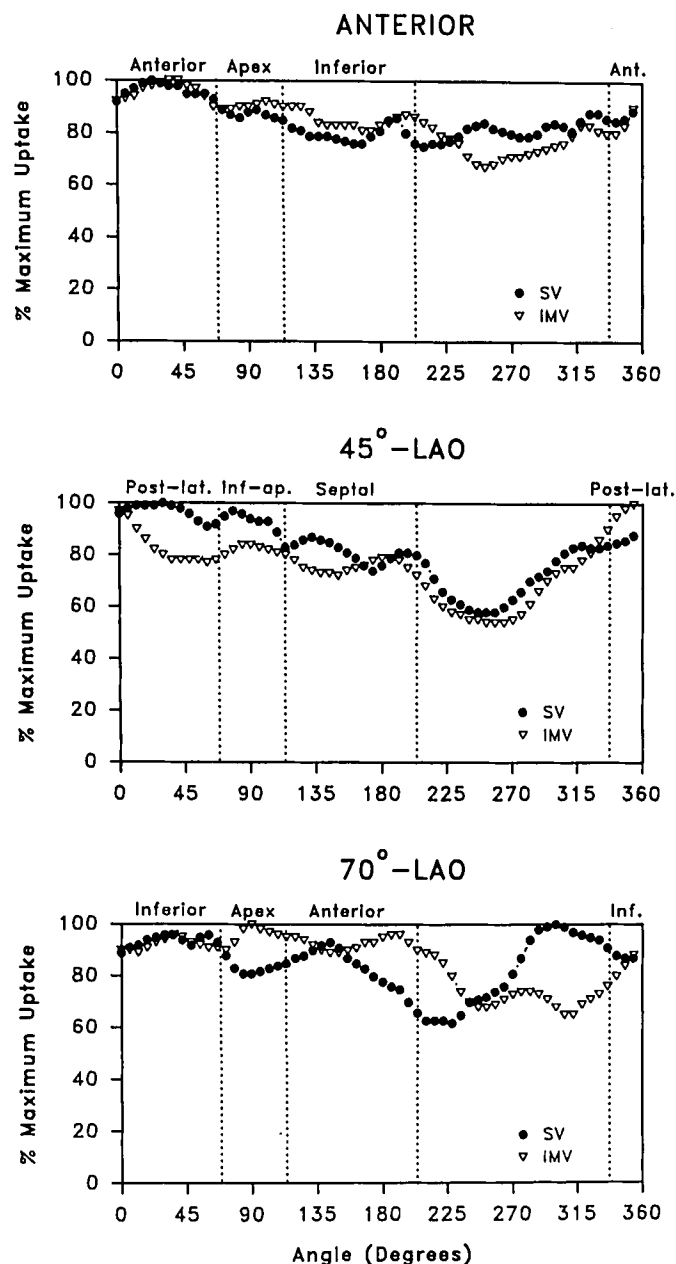


FIG. 2. Circumferential profiles of initial <sup>201</sup>Tl uptake in patient 1 during spontaneous ventilation (circles) and during intermittent mechanical ventilation (triangles). This patient had normal initial <sup>201</sup>Tl uptake during both spontaneous and mechanical ventilation. There were no regional differences of <sup>201</sup>Tl uptake in any myocardial region.

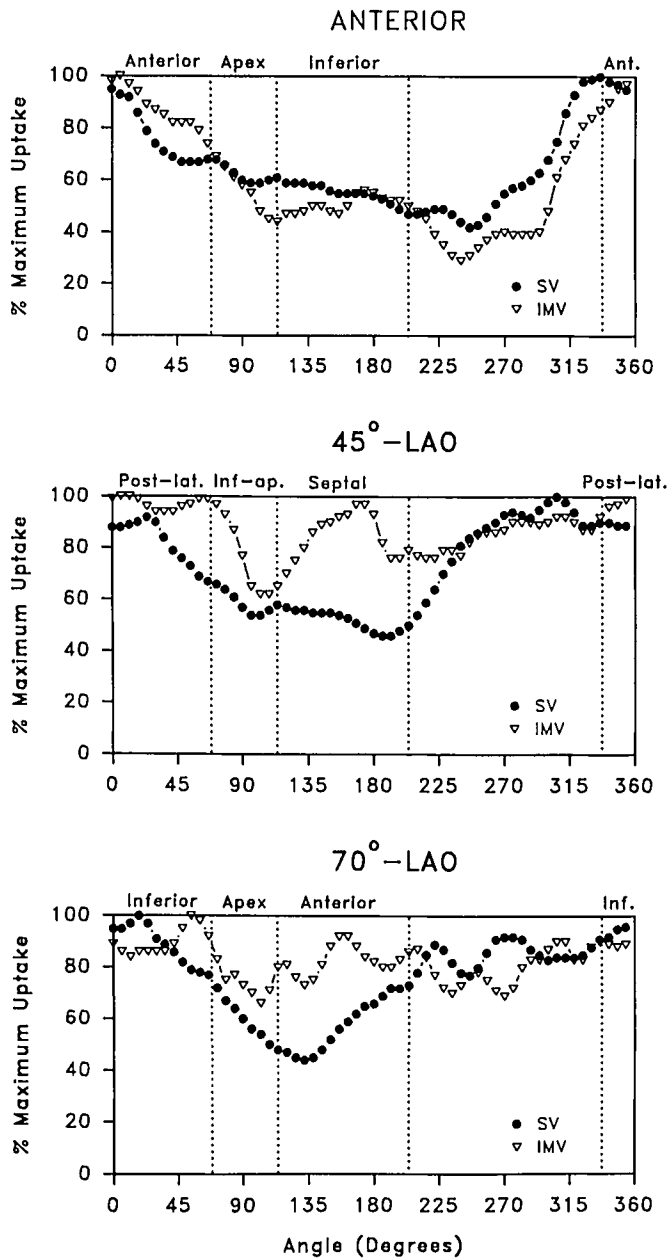


FIG. 3. Circumferential profiles of initial  $^{201}\text{Tl}$  uptake in patient 4 during spontaneous ventilation (circles) and during intermittent mechanical ventilation (triangles). Decreased  $^{201}\text{Tl}$  uptake was evident within inferior and apical myocardial regions on the scan performed during mechanical ventilation. During SV, additional areas of decreased  $^{201}\text{Tl}$  uptake were evident in the septum and anterior wall. On delayed imaging,  $^{201}\text{Tl}$  redistribution in these areas was noted.

tient 5) demonstrated reversible myocardial  $^{201}\text{Tl}$  defects during SV. Five of the patients we studied (33%) had transient increases of LV cavity size during SV. Three of these patients also demonstrated focal regions of decreased  $^{201}\text{Tl}$  uptake with redistribution of the radiolabel

on delayed images during their SV study. Transient LV dilation was not identified in any of the  $^{201}\text{Tl}$  scans performed during MV.

The remaining seven patients (47%) demonstrated an abnormal initial  $^{201}\text{Tl}$  uptake during MV and SV, but

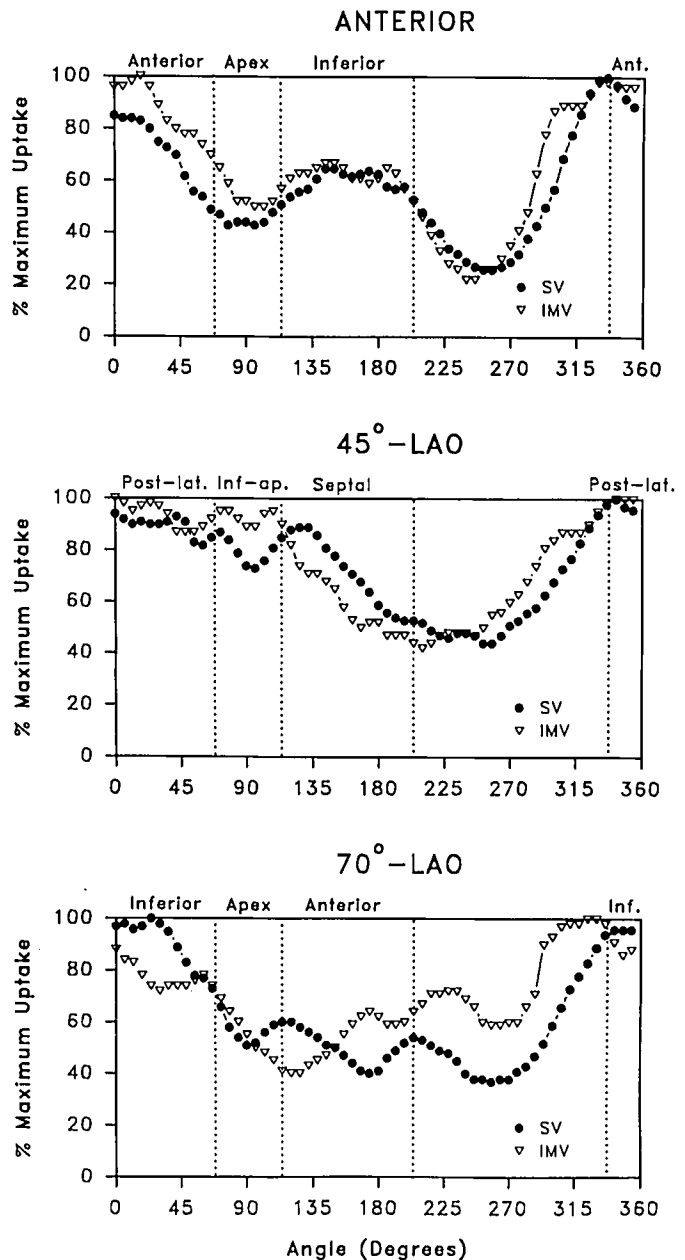


FIG. 4. Circumferential profiles of initial  $^{201}\text{Tl}$  uptake in patient 11 during spontaneous ventilation (circles) and during intermittent mechanical ventilation (triangles). Decreased  $^{201}\text{Tl}$  uptake was evident within apical, inferior, septal, and anterior regions on both scans. Myocardial  $^{201}\text{Tl}$  uptake on the scans acquired during spontaneous and mechanical ventilation was identical. Qualitative analysis of delayed images revealed no evidence of  $^{201}\text{Tl}$  redistribution.

TABLE 3. Outcome Variables

Variable	All Patients	Negative Thallium	Positive Thallium
Number	15	8	7
Age (yr)	71 ± 7 (60-84)	70 ± 8 (60-84)	71 ± 6 (62-83)
Days of mechanical ventilation	61 ± 41 (24-144)	44 ± 22 (25-84)	81 ± 50 (24-144)
Days hospitalized	70 ± 39 (24-144)	53 ± 22 (25-89)	90 ± 47 (24-144)
Hospital cost (\$×1000)	117 ± 72 (12-253)	75 ± 44 (12-156)	165 ± 69 (67-253)*
Mortality (%)	67	50	86

Values are mean ± SD, with ranges in parentheses. A positive <sup>201</sup>Tl scan showed areas of decreased initial <sup>201</sup>Tl uptake during SV with redistribution of the label on delayed imaging and/or transient left

ventricular dilation during SV. All other scans were considered to be negative.

\* *P* = 0.01 compared to those with negative <sup>201</sup>Tl scans.

without redistribution (fixed defects) and without differences between SV and MV images (a "negative" scan with discontinuation of MV). Figure 4 depicts the circumferential profiles of one such patient (patient 11).

### OUTCOME

The lungs of the patients we studied were ventilated mechanically for 24-144 days (table 3). Ten of the patients subsequently died in the hospital before being weaned from the ventilator. In these patients, death usually followed a decision to limit or curtail medical therapy. No postmortem examinations were obtained. The five patients who survived no longer required MV eventually, and were discharged from the hospital. The hospital charges of the seven patients with positive <sup>201</sup>Tl scans during SV averaged 120% greater than those of patients with negative scans (*P* = 0.01) (table 3). The number of days of MV, number of days hospitalized, and overall mortality were not statistically different for patients with positive or negative <sup>201</sup>Tl scans during SV. A prior history of cardiac or chronic pulmonary disease was not predictive of an abnormal <sup>201</sup>Tl scan during MV or SV, and it was not related to outcome.

### Discussion

Our study suggests that acute regional alterations of myocardial perfusion, as detected by quantitative <sup>201</sup>Tl myocardial scintigraphy, frequently occur when MV-dependent patients breathe spontaneously. Changing the ventilatory pattern from MV to SV was associated with the appearance of <sup>201</sup>Tl defects that later demonstrated redistribution or acute LV dilation in 7 of the 15 patients (47%) we examined (see table 1). That the hospital charges were more than twice as high in such patients (table 3) suggests that such alterations of myocardial perfusion could be associated with a prolonged recovery (longer hospitalizations or patients who are more ill). In our study, the small number of patients examined precludes conclusions from being made concerning differences in mortality, duration of MV, or length of hospitalization.

Our findings suggest that the hemodynamic and ventilatory changes associated with discontinuing MV were sufficient to increase myocardial oxygen demand (evidenced by the increased heart rate, arterial blood pressure, and LV cavity size during SV). During SV, the appearance of regions of decreased myocardial <sup>201</sup>Tl uptake that later redistributed (5 of 15 patients) indicates these regions were relatively hypoperfused as compared with adjacent zones of myocardium that had similarly increased oxygen demands. Although the transient LV dilation we detected by <sup>201</sup>Tl scintigraphy during SV (5 of 15 patients) could reflect increased LV filling, it is more likely that this change represents transient ischemic dilation of the ventricle. Acquisition of each <sup>201</sup>Tl image required 8 min and began only after the hemodynamic and ventilatory stress (SV) was terminated. Accordingly, each <sup>201</sup>Tl image is a "time exposure" reflecting LV size and motion during that time period. Changes of LV size resulting from transient increases of LV preload or afterload would have had to persist throughout the imaging period (well after the reinstatement of MV) to be detected. Because transient LV dilation reflects an increase in LV size that persisted after the return to MV, it more likely results from transient myocardial ischemia and hypokinesis.<sup>10,11</sup>

According to recent studies, successful separation from the ventilator of MV-dependent patients whose pulmonary and respiratory muscle function appear adequate to sustain SV can be impaired by cardiac dysfunction. Lemaire *et al.* prospectively studied hemodynamics, respiratory mechanics, and ventricular volumes of 15 MV-dependent patients with respiratory mechanics similar to those of the patients that we studied.<sup>1</sup> When these patients breathed spontaneously, their mean transmural LV filling pressure, as gauged by the pulmonary artery occlusion pressure (PAOP) or LV end-diastolic pressure (LVEDP), increased from 7.5 ± 5 mmHg to 24.5 ± 13 mmHg (mean ± SD). Furthermore, both LV and right ventricular volumes, as measured by radionuclide angiocardiology, increased significantly. Three patients with preexisting LV wall motion abnormalities during MV demonstrated worsening of wall motion abnormalities during SV. After

10 min of SV, the esophageal pressure was reduced, whereas cardiac index, heart rate, and central venous, pulmonary artery, and mean systemic blood pressures were increased.

The increases of PAOP and LVEDP associated with the discontinuation of MV suggest that LV volume overload may result from redistribution of the blood volume from peripheral to central cardiopulmonary compartments.<sup>2</sup> Reduced intrathoracic pressure during SV also can increase LV afterload.<sup>15-18</sup> These hemodynamic stresses produced by spontaneous, as opposed to positive-pressure, ventilation could result in altered myocardial perfusion and LV dysfunction.<sup>1,19,20</sup>

Are areas demonstrating decreased initial <sup>201</sup>Tl uptake and redistribution ischemic? An abnormal <sup>201</sup>Tl distribution depends on the presence of inhomogeneous blood flow at the time of <sup>201</sup>Tl injection, and not on the presence of myocardial ischemia *per se*.<sup>4</sup> Conceivably, areas with decreased <sup>201</sup>Tl uptake could represent regions with normal myocardial blood flow that are surrounded by zones of abnormally increased flow. Such a situation might occur when a coronary vasodilator is administered that increases myocardial blood flow without concomitantly increasing myocardial oxygen demand.

In our study, however, we increased several determinants of myocardial oxygen demand (heart rate, arterial blood pressure, and LV size) by discontinuing MV. Myocardial blood flow should have increased throughout the left ventricle in response to the increased oxygen demand. Areas supplied by stenotic coronary arteries (resulting from coronary atherosclerosis or spasm) might be unable to increase myocardial blood flow sufficiently. Thallium-201 uptake in such areas initially would be reduced in comparison with that of adjacent normal regions and, unlike infarcted regions with no blood flow, demonstrate redistribution on subsequent delayed imaging. The zones demonstrating <sup>201</sup>Tl redistribution we observed in 5 of the 15 patients we studied during SV therefore most likely represent areas of hypoperfusion relative to the oxygen demands of the myocardium. Documentation of concomitant LV wall motion abnormalities or measurements of myocardial metabolism in such patients would provide useful confirmation of myocardial dysfunction or ischemia.

In our study, we did not observe any electrocardiographic changes diagnostic of myocardial ischemia during SV. Seven of the 15 patients we studied had received digoxin, which might have obscured the diagnosis of ischemia by ST-segment criteria. Also, because the electrocardiograms were not recorded continuously throughout the study, transient ST-segment changes may have been missed.

Others have reported that electrocardiographic criteria appear relatively insensitive to the occurrence of myo-

cardial ischemia, as compared with other methods.<sup>6,12</sup> Le-maire *et al.*, examining lead II electrocardiograms of the 15 MV-dependent patients they studied, reported a lack of electrocardiographic changes despite an increased PAOP and LVEDP and worsening of LV wall motion abnormalities during SV.<sup>1</sup> Häggmark *et al.*, studying 53 patients with coronary artery disease who were undergoing major vascular surgery, reported that electrocardiography detected only 31 of 89 episodes (44%) of myocardial ischemia diagnosed by cardiokymography, electrocardiography, or myocardial lactate production.<sup>12</sup> Kleinman *et al.* reported a 45% incidence of positive <sup>201</sup>Tl scans after tracheal intubation in patients undergoing coronary artery bypass surgery even though the ST-segments of the V<sub>5</sub> electrocardiogram remained normal during this period.<sup>6</sup> Similarly, Smith *et al.* reported new systolic LV wall motion abnormalities, suggesting myocardial ischemia, in 24 of 50 patients undergoing major vascular or cardiac surgery, whereas ST-segment changes were documented in only 6 of the patients.<sup>21</sup> Also, multiple studies have documented that stress electrocardiography is much less sensitive than thallium scintigraphy when it is used to diagnose coronary artery disease.<sup>22</sup>

The high incidence of abnormal initial <sup>201</sup>Tl scans (fixed defects) performed during MV in our study (13 of 14 patients studied on MV) is not surprising, given the age of our patients and 7 patients with a history of coronary artery disease.<sup>22</sup> We believe the large number of abnormal initial <sup>201</sup>Tl images during MV resulted from a high frequency of coronary artery disease in our MV-dependent patient population.<sup>23</sup> Some of the fixed defects also may be imaging artifacts created when photons are attenuated by breast and chest wall tissue overlying the heart. The appearance of additional <sup>201</sup>Tl defects or LV dilation during SV (see table 1) probably reflects an increased LV cavity size and wall stress and a concomitantly increased oxygen demand in areas of myocardium supplied by stenotic coronary arteries.

Visual interpretation of scintigraphic <sup>201</sup>Tl images can be subject to considerable variability.<sup>24</sup> Using multiple observers or quantitative computer-driven programs can reduce variability and increase the sensitivity and specificity of the test.<sup>25</sup> To reduce the likelihood of overreading the scans, we required that initial <sup>201</sup>Tl defects be present according to quantitative criteria and that the interpretations of the observers agreed on two separate occasions. The observers also were blinded as to the patients' ventilatory patterns and outcome. With this conservative approach, it is possible that the actual incidence of additional perfusion abnormalities after the discontinuation of MV is higher than the value reported in our study (46%). Changes in the position of the patient and the orientation of the heart may confound precise interpretation of <sup>201</sup>Tl scans.<sup>26,27</sup> Our ability to minimize positional changes is



evidenced by the close correlations of the quantitative analyses of our <sup>201</sup>Tl scans (see figs. 2-4).

The survival rate of MV-dependent patients remains poor. Spicher and White retrospectively examined the courses of 250 patients who required a minimum of 10 days of mechanical ventilatory support and reported an overall survival rate of 39.2% at hospital discharge.<sup>28</sup> Elderly patients or those with preexisting cardiac or pulmonary disease had the worst prognosis. Similar findings have been reported by others.<sup>29,30</sup> ‡‡ Our study confirms the poor prognosis of MV-dependent patients (see table 3). After an average of 61 days of MV and \$117,000 of hospital charges, only 33% were separated successfully from MV and discharged from the hospital. The patients in our study were elderly, often had a prior history of coronary artery disease or chronic obstructive pulmonary disease, and required prolonged ventilatory support. Healthier or younger patients might have had less difficulty separating from MV and might have displayed less dramatic changes of coronary perfusion during SV.

We conclude that the increased hemodynamic and ventilatory stress of SV after the discontinuation of MV was sufficient to induce changes of myocardial <sup>201</sup>Tl uptake or transient LV dilation, strongly suggesting myocardial ischemia, in 7 of the 15 MV-dependent patients (47%) we studied. These changes probably result from both an increased LV preload and afterload occurring with the discontinuation of MV. Such changes may be clinically important and could impair successful separation from MV. Pharmacologic and other interventions aimed at improving coronary artery blood flow and reducing LV wall stress during SV may play a beneficial role in the recovery of patients dependent on MV. Lemaire *et al.* reported that 9 of the 15 ventilator-dependent patients they studied could be removed successfully from MV after 10 days of diuretic therapy.<sup>1</sup> Their patients' body weights decreased an average of 5 kg during this time. The efficacy of therapies such as diuretic administration, aimed at reducing hypervolemia, possibly in combination with vasodilator drugs such as nitrates or calcium channel-blocking agents, merits additional study.

The authors thank Frances Keech, RNMT, for her expert imaging and technical assistance; Alan Fischman, M.D., for his assistance with <sup>201</sup>Tl scan interpretation; Richard Moore, Ph.D., for programming and computer analysis; and Donna Wilson, RN, RRT, for assistance with patient recruitment and care.

‡‡ Swinburne AJ, Fedullo AJ, Shayne DS: Mechanical ventilation: Analysis of increasing use and patient survival. *Journal of Intensive Care Medicine* 3:315-320, 1988.

## References

1. Lemaire F, Teboul J-L, Cinotti L, Giotto G, Abrouk F, Steg G, Macquin-Mavier I, Zapol WM: Acute left ventricular dysfunction

- during unsuccessful weaning from mechanical ventilation. *ANESTHESIOLOGY* 69:171-179, 1988
2. Permutt S: Circulatory effects of weaning from mechanical ventilation: The importance of transdiaphragmatic pressure. *ANESTHESIOLOGY* 69:157-160, 1988
3. Bailey IK, Griffith LSC, Rouleau J, Strauss HW, Pitt B: Thallium-201 myocardial perfusion imaging at rest and during exercise. Comparative sensitivity to electrocardiography in coronary artery disease. *Circulation* 55:79-87, 1977
4. Pohost GM, Alpert NM, Ingwall JS, Strauss HW: Thallium redistribution: Mechanisms and clinical utility. *Semin Nucl Med* 10:70-93, 1980
5. Boucher CA, Brewster DC, Darling RC, Okada RD, Strauss HW, Pohost GM: Determination of cardiac risk by dipyridamole-thallium imaging before peripheral vascular surgery. *N Engl J Med* 312:389-394, 1985
6. Kleinman B, Henkin RE, Glisson SN, El-Etr AA, Bakhos M, Sullivan HJ, Montoya A, Pifarre R: Qualitative evaluation of coronary flow during anesthetic induction using thallium-201 perfusion scans. *ANESTHESIOLOGY* 64:157-164, 1986
7. Strauss HW, Harrison K, Langan JK, Lebowitz E, Pitt B: Thallium-201 for myocardial imaging: Relation of thallium-201 to regional myocardial perfusion. *Circulation* 51:641-645, 1975
8. Kaul S: Evaluation of myocardial perfusion using planar thallium 201 imaging at rest and during exercise, *Comparative Cardiac Imaging: Function, Flow, Anatomy, and Quantitation*. Edited by Brundage BH. Rockville, Aspen Publishers, 1990, pp 181-209
9. Pohost GM, Zir LM, Moore RH, McKusick KA, Guiney TE, Beller GA: Differentiation of transiently ischemic from infarcted myocardium by serial imaging after a single dose of thallium-201. *Circulation* 55:294-302, 1977
10. Weiss AT, Berman DS, Lew AS, Nielsen J, Potkin B, Swan HJC, Waxman A, Maddahi J: Transient ischemic dilation of the left ventricle on stress thallium-201 scintigraphy: A marker of severe and extensive coronary artery disease. *J Am Coll Cardiol* 9: 752-759, 1987
11. Chouraqui P, Rodrigues EA, Berman DS, Maddahi J: Significance of dipyridamole-induced transient dilation of the left ventricle during thallium-201 scintigraphy in suspected coronary artery disease. *Am J Cardiol* 66:689-694, 1990
12. Häggmark S, Hohner P, Ostman M, Friedman A, Diamond G, Lowenstein E, Reis S. Comparison of hemodynamic, electrocardiographic, mechanical, and metabolic indicators of intraoperative myocardial ischemia in vascular surgical patients with coronary artery disease. *ANESTHESIOLOGY* 70:19-25, 1989
13. Garcia E, Maddahi J, Berman D, Waxman A: Space/time quantitation of thallium-201 myocardial scintigraphy. *J Nucl Med* 22:309-317, 1981
14. Van Train KF, Berman DS, Garcia EV, Berger HJ, Sands MJ, Friedman JD, Freeman MR, Pryzlak M, Ashburn WL, Norris SL, Green AM, Maddahi J: Quantitative analysis of stress thallium-201 myocardial scintigrams: a multicenter study. *J Nucl Med* 27:17-25, 1986
15. Buda AJ, Pinsky MR, Ingels NB Jr, Daughters GT II, Stinson EB, Alderman EL: Effect of intrathoracic pressure on left ventricular performance. *N Engl J Med* 301:453-459, 1979
16. Scharf SM, Bianco JA, Tow DE, Brown R: The effects of large negative intrathoracic pressure on left ventricular function in patients with coronary artery disease. *Circulation* 63:871-874, 1981
17. Mathru M, Rao TLK, El-Etr AA, Pifarre R: Hemodynamic response to changes in ventilatory patterns in patients with normal and poor left ventricular reserve. *Crit Care Med* 10:423-426, 1982

18. Robotham JL: Hemodynamic events: A physiologic approach, Chronic Obstructive Pulmonary Disease; Contemporary Issues in Pulmonary Disease. Edited by Montenegro HD. New York, Churchill Livingstone, 1984, pp 183-217
19. Beach T, Millen E, Grenvik A: Hemodynamic response to discontinuance of mechanical ventilation. *Crit Care Med* 1:85-90, 1973
20. Chin WDN, Cheung HW, Driedger AA, Cunningham DG, Sibbald WJ: Assisted ventilation in patients with preexisting cardiopulmonary disease: The effect on systemic oxygen consumption, oxygen transport, and tissue perfusion variables. *Chest* 88:503-511, 1985
21. Smith JS, Cahalan MK, Benefiel DJ, Byrd BF, Lurz FW, Shapiro WA, Roizen MF, Bouchard A, Schiller NB: Intraoperative detection of myocardial ischemia in high-risk patients: Electrocardiography versus two-dimensional transesophageal echocardiography. *Circulation* 72:1015-1021, 1985
22. Diamond GA, Forrester JS: Analysis of probability as an aid in the clinical diagnosis of coronary-artery disease. *N Engl J Med* 300:1350-1358, 1979
23. Gewirtz H, Beller GA, Strauss HW, Dinsmore RE, Zir LM, McKusick KA, Pohost GM: Transient defects of resting thallium scans in patients with coronary artery disease. *Circulation* 59:707-713, 1979
24. McLaughlin PR, Martin RP, Doherty P, Daspit S, Goris M, Haskell W, Lewis S, Kriss JP, Harrison DC: Reproducibility of thallium-201 myocardial imaging. *Circulation* 55:497-503, 1977
25. Okada RD, Boucher CA, Kirshenbaum HK, Kushner FG, Strauss HW, Block PC, McKusick KA, Pohost GM: Improved diagnostic accuracy of thallium-201 stress test using multiple observers and criteria derived from interobserver analysis of variance. *Am J Cardiol* 46:619-624, 1980
26. Makler PT Jr, McCarthy DM, Velchik MG, Alavi A: Sources of variability in quantitative thallium analysis. *Invest Radiol* 20:803-807, 1985
27. Horowitz SF, Machac J, Levin H, Matza D: Effect of variable left ventricular vertical orientation on planar myocardial perfusion images. *J Nucl Med* 27:694-700, 1986
28. Spicher JE, White DP: Outcome and function following prolonged mechanical ventilation. *Arch Intern Med* 147:421-425, 1987
29. Davis H II, Lefrak SS, Miller D, Malt S: Prolonged mechanically assisted ventilation: An analysis of outcome and charges. *JAMA* 243:43-45, 1980
30. Witek TJ Jr, Schachter EN, Dean NL, Beck GJ: Mechanically assisted ventilation in a community hospital: Immediate outcome, hospital charges, and follow-up of patients. *Arch Intern Med* 145:235-239, 1985