

TABLE 1. Number of Patients with Hypoxic Episodes in the PACU

Sp _o ₂ (%)	Measured at Two Fixed Points				Original Data (Continuous Observation during the whole PACU Stay ¹)	
	10 min after arrival		60 min after arrival			
	Number	%	Number	%	Number	%
≤90	12	6	7	3.5	111	55
≤85	2*	1	0	0	56*	28
≤80	1†	0.5	0	0	26†	13

* Also counted among the patients at Sp_o₂ ≤ 90%.

† Also counted among the patients at Sp_o₂ ≤ 85%.

The incidence of hypoxemia in our study is still somewhat greater than that found by Canet *et al.*, and several factors, including the way in which oxygen was administered, may explain the difference.

JAKOB TRIER MOLLER, M.D.
Department of Anesthesia
University of Copenhagen
Herlev Hospital
DK-2730 Herlev, Denmark

REFERENCES

- Moller JT, Witttrup M, Johansen SH: Hypoxemia in the post-anesthesia care unit: an observer study. *ANESTHESIOLOGY* 73: 890-895, 1990
- Canet J, Ricos M, Vidal F: Early postoperative arterial oxygen desaturation. Determining factors and response to oxygen therapy. *Anesth Analg* 69:207-212, 1989

Anesthesiology
74:1162-1163, 1991

Anesthetic Management of a Patient with Cornelia de Lange Syndrome

To the Editor:—Recently, I was confronted with a patient with Cornelia de Lange Syndrome. This syndrome was described in 1933, and initially Cornelia de Lange called it "typus degenerativus Amstelodamensis".¹ It later was called "Amsterdam dwarfism". Reference to the recent review article on anesthetic management of disproportionate dwarfism by Berkowitz *et al.*² will not be helpful in a patient with Cornelia de Lange Syndrome since these patients have a normal proportion in build of body and limbs³ and dwarfism is not invariable¹; i.e., the term "Amsterdam dwarfism" lacks accuracy.¹ These patients have some growth and mental retardation, microbrachycephaly, and hirsutism.⁴ The syndrome was not found in American literature until 1963. It affects 1 in 30,000 to 1 in 60,000 live births.* The basic pathology is believed to be hypoplasia of the mesenchyme.† The etiology is believed to be genetic, with suggestions of autosomal recessive or dominant inheritance.^{1,5,6} A most important feature is a striking delay in the maturation of structure and function of most organ systems, including the central nervous system.⁶ These patients' "leprechaunoid" facies is striking.⁷ Two thirds die before age 1 yr.⁸ Death occurs from aspiration in infancy,^{5,6} and from infections and bowel obstruction later on.^{5-8,†} Depression of the immune system is reported.^{6,†} Our patient, at age 30%, is one of the oldest. They may have self-destructive tendencies,^{5,8,*} and it was this characteristic that brought our patient to the hospital for amputation of an infected deformed distal upper extremity.

Preanesthetic considerations include immaturity of organ systems with possible unpredictable responses to drugs. This may be anticipated from some limited endocrine studies and autopsy findings, suggesting hypopituitarism with abnormal function and structure of the thyroid and adrenal glands.⁹ Schlesinger *et al.*⁹ suggested that antibiotics and

steroids be given to cover infections and the stress of surgery. Problems during induction include the potential for aspiration due to frequent pressure of hiatal hernia and difficulty with tracheal intubation. Intubation may be difficult due to a short neck, often webbed; a high-arched palate, sometimes clefted; and a small mouth with micrognathia. Care must be taken in resumption of oral intake due to chewing and swallowing difficulties and the potential for aspiration.^{5,8,*} In infants, apneic episodes are not uncommon.^{8,9}

Reported anesthetic experience with these patients is sparse and sometimes fraught with problems, including death.^{1,10,†} Our patient exhibited some unpredictable or sensitive responses to drugs. He had a past history of agitation after haloperidol and chlorpromazine, and hypotension when first given chlordiazepoxide. He became somnolent after 10 mg metoclopramide given preoperatively. His anesthetic requirements appeared minimal. Although severely retarded and uncooperative in surgery, he was well sedated, and his trachea was intubated with little technical difficulty after only 0.5 mg midazolam and 1 ml fentanyl. Ten milligrams dexamethasone was given. Hypnosis resulted after 60% nitrous oxide in oxygen. An additional 1 mg midazolam, 1 ml fentanyl, and 3 mg vecuronium provided uneventful general anesthesia for the hour-long orthopedic procedure. Relaxant reversal was accomplished with 0.3 mg glycopyrrolate and 1.5 mg neostigmine. Tracheal extubation and recovery were uneventful.

WILLIAM W. SARGENT, M.D., M.S.
Staff Anesthesiologist
St Luke's Hospital
915 East First Street
Duluth, Minnesota 55805

REFERENCES

- Filippi G: The de Lange syndrome: Report of 15 cases. *Clin Genet* 35:343-363, 1989
- Berkowitz ID, Raja SN, Bender KS, Kopits SE: Dwarfs: patho-

* O'Donnell D, Davis PJ, King NM: Management problems associated with Cornelia de Lange syndrome. *Special Care in Dentistry* Jul-Aug 5(4):160-163, 1985

† Takeshita T, Akita S, Kawahara M: Anesthetic management of a patient with Cornelia de Lange syndrome. *Anesthesia Progress* 34:63-65, 1987

- physiology and anesthetic implications. *ANESTHESIOLOGY* 73: 739-759, 1990
- Schlesinger B, Clayton B, Bodian M, Jones KV: Typus degenerativus Amstelodamensis. *Arch Dis Child* 38:349-357, 1963
 - Hawley PP, Jackson LG, Kurnit DM: Sixty-four patients with Brachmann-de Lange syndrome: a survey. *Am J Med Genet* 20:453-459, 1985
 - Smith DW: *Smith's Recognizable Patterns of Human Malformation*. Philadelphia, WB Saunders Co., 1988, pp 80-83
 - Ptacek LJ, Opitz JM, Smith DW, Gerritsen T, Waisman HA: The Cornelia de Lange syndrome. *J Pediatr* 63:1000-1020, 1963
 - Wick MR, Simmons PS, Ludwig J, Kleinberg F: Duodenal obstruction, annular pancreas, and horseshoe kidney in an infant with Cornelia de Lange syndrome. *Minn Med* 65:539-541, 1982

- Joubin J, Pettrone CF, Pettrone FA: Cornelia de Lange syndrome. A review article (with emphasis on orthopedic significance). *Clin Orthop* 171:180-185, 1982
- Silver HK: The de Lange syndrome: Typus Amstelodamensis. *Am J Dis Child* 108:523-529, 1964
- Lumb AB, Carli F: Respiratory arrest after a caudal injection of bupivacaine. *Anaesthesia* 44:324-325, 1989
- Kiryama M, Masuda A, Satone T, Higuchi A, Ito Y: Anesthetic management of a patient with Cornelia de Lange syndrome. *Masui* 33:1392-1394, 1984

(Accepted for publication March 8, 1991.)

Anesthesiology
74:1163-1164, 1991

Bilateral Upper Lobe Obstruction from a Single Double-lumen Tube

To the Editor:—We recently cared for a patient in whom both upper lobe bronchi were simultaneously obstructed by a single double-lumen endobronchial tube (DLT).

Case Report. A 68-yr-old, 188-cm, 100-kg man was scheduled for right thoracotomy. Routine bronchoscopy prior to surgery revealed that his right upper lobe bronchus originated above the carina in the trachea. In the operating room, a 41-Fr left DLT was advanced down his trachea until resistance to further passage was encountered. Both cuffs were then inflated with air, and breath sounds were present bilaterally. Following occlusion of the tracheal lumen, breath sounds were completely absent over the right lung, while the presence of breath sounds over the left chest indicated that the tube was in the left main bronchus. Breath sounds were loudest over the left lower chest. The clamp was removed and reapplied to the bronchial lumen. Breath sounds were now present only over the right lower lung field. At this point the bronchial cuff was deflated. Breath sounds now were present over the entire left lung and over just the right lower lung field.

A fiberoptic bronchoscope was introduced down the tracheal lumen, and the DLT was withdrawn until the blue endobronchial cuff was visible immediately below the carina in the left main bronchus. As the tube was withdrawn, the orifice of the right upper lobe bronchus came into view in the trachea. It was apparent that the inflated tracheal cuff had obstructed the right upper lobe bronchus, while breath sounds could now be heard over the left upper chest, indicating that the bronchial cuff had simultaneously obstructed the orifice of the left upper lobe bronchus (fig. 1). Sequential clamping of each lumen was now followed by clear breath sounds over the entire contralateral lung, and there was obvious improvement in lung compliance, as less pressure was now needed to inflate each lung during one-lung ventilation.

Discussion. Bronchial cuff obstruction of either the left or right upper lobe bronchi from a DLT advanced too far into the main bronchus is a well-known occurrence¹ and is usually easily recognized by careful auscultation.² In order for both upper lobe bronchi to be obstructed with a left DLT, the bronchus to the right upper lobe must originate at or above the carina. Tracheal takeoff of the right upper lobe bronchus was present in 5 of 1,250 (0.4%) patients bronchoscoped,³ and the incidence this anomaly may be as high as 2% in patients with congenital heart disease.¹ Simultaneous bilateral obstruction of both upper lobe bronchi has not been previously reported. This rare complication of DLT placement was suggested by careful auscultation and was confirmed by fiberoptic bronchoscopy.

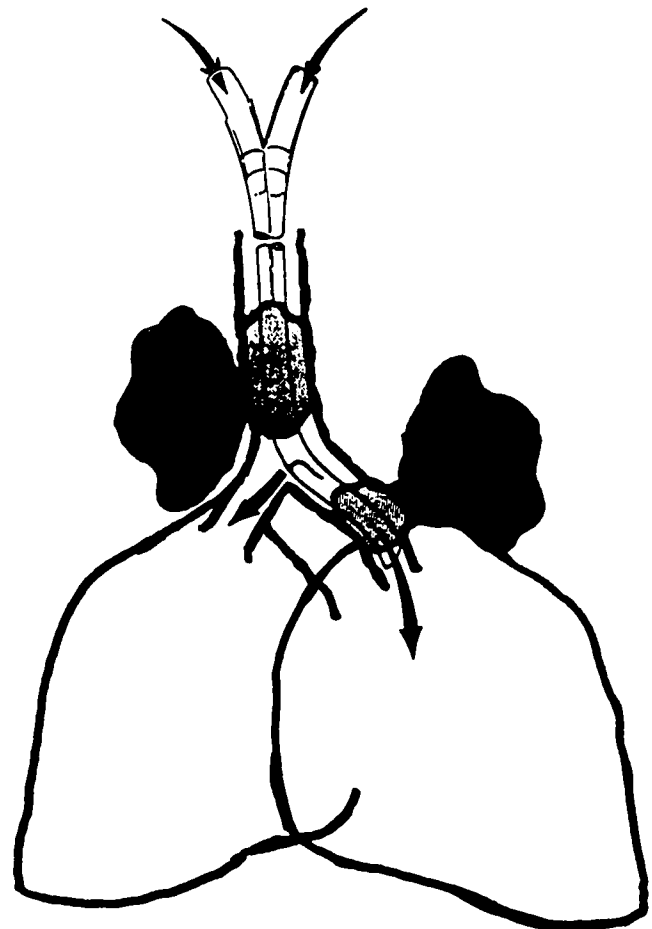


FIG. 1. The left DLT was advanced down the trachea until moderate resistance to further passage was encountered. With the tube in this position while ventilating the patient through both lumens of the DLT, the left upper lobe bronchus was obstructed by the inflated bronchial cuff while the right upper lobe bronchus, which originated in the trachea, was simultaneously obstructed by the inflated tracheal cuff.