

pulse oximetry and capnometry. Moreover, since it takes little time to assess its efficacy, it does not delay other measures, should they be necessary. Finally, it may result in complete reversal of cyanosis and return to a stable and normal hemodynamic situation. This maneuver has the same physiologic impact as surgical aortic cross-clamping and therefore should not be unnecessarily prolonged.

We propose external manual compression of the abdominal aorta as the first therapeutic step in treating intraoperative cyanotic spells associated with TOF. Whether it also can be attempted in other circumstances (such as out of the hospital) is not known.

#### REFERENCES

1. Beynen FM, Tarhan S: Anesthesia for surgical repair of congenital heart defects in children, *Cardiovascular Anesthesia and Postoperative care*. Edited by Tarhan S. Chicago, Yearbook Medical Publishers, 1982, pp 142-149
2. Samuelson PN, Lell WA: Tetralogy of Fallot, *Pediatric Cardiac Anesthesia*. Edited by Lake CL. Norwalk, Appleton & Lange, 1988, pp 222-225
3. Hickey PR, Wessel DL: Anesthesia for congenital heart disease, *Pediatric Anesthesia*. Edited by Gregory GA. New York, Churchill Livingstone, 1989, pp 833-892
4. Nolan SP, Kron IL, Rheuban K: Simple method for treatment of

- intraoperative hypoxic episodes in patients with Tetralogy of Fallot. *J Thorac Cardiovasc Surg* 85:796-797, 1983
5. Greeley WJ, Stanley TE, Ungerleider RM, Kisslo JA: Intraoperative hypoxemic spells in Tetralogy of Fallot: An echographic analysis of diagnosis and treatment. *Anesth Analg* 68: 815-819, 1989
6. Moller JH, Neal WA: Cyanosis and decreased pulmonary blood flow, *Heart Disease in Infancy*. Edited by Moller JH, Neal WA. New York, Appleton-Century-Crofts, 1981, pp 368-369
7. Guntheroth WC, Mortan BC, Mullins GL, Baum D: Venous return with knee-chest position and squatting in Tetralogy of Fallot. *Am Heart J* 75:313-318, 1968
8. O'Donnell TV, McIlroy BC: The circulating effects of squatting. *Am Heart J* 64:347-356, 1962
9. Nudel DB, Berman MA, Talner NS: Effects of acutely increasing systemic vascular resistance on oxygen tension in Tetralogy of Fallot. *Pediatrics* 58:248-251, 1976
10. Bullaboy CA, Derkac WM, Johnson OH, Jennings RB: Tetralogy of Fallot and coarctation of the aorta: Successful repair in an infant. *Ann Thorac Surg* 38:400-401, 1984
11. Ponce FE, Williams LC, Webb HM, Riopel DA, Hohn AR: Propranolol palliation of Tetralogy of Fallot: Experience with long-term drug treatment in pediatric patients. *Pediatrics* 52:100-108, 1973
12. Garson A Jr, Gillette PC, McNamara DG: Propranolol: The preferred palliation for Tetralogy of Fallot. *Am J Cardiol* 47:1098-1104, 1981
13. Shaddy RE, Viney J, Judd VE, McGough EC: Continuous intra-venous phenylephrine infusion for treatment of hypoxemic spells in Tetralogy of Fallot. *J Pediatr* 114:468-470, 1989

Anesthesiology  
75:149-153, 1991

### Transesophageal Echocardiographic Diagnosis of Aortic Dissection during Cardiac Surgery

CHRISTOPHER A. TROIANOS, M.D.,\* JOSEPH S. SAVINO, M.D.,† RICHARD L. WEISS, M.D.‡

Aortic dissection during cardiac surgery is a rare complication that is associated with significant morbidity and mortality. Early recognition and management improves patient outcome.<sup>1</sup> The intraoperative diagnosis of ascending aortic dissection is made when inspection of the proximal aorta reveals bleeding, intramural hematoma, or increasing aortic diameter. Visual inspection without aortotomy provides little information regarding the severity and extent of dissection. Dissection of the aortic

arch and descending aorta during cardiac surgery is not readily apparent.

The proximity of the esophagus to the thoracic aorta and the high-resolution images produced by two-dimensional ultrasound have established transesophageal echocardiography (TEE) as an accepted standard outside of the operating room in the detection and evaluation of thoracic aortic dissection.<sup>2-7</sup> We report three cases that illustrate the utility of TEE in the diagnosis and intraoperative monitoring of acute aortic dissection during cardiac surgery. The patients were monitored with a 5.0-MHz TEE probe (Sonos 500, Hewlett-Packard, Andover, MA).

#### CASE REPORTS

*Case 1.* A 61-yr-old, ASA physical status 4, 55-kg, 157-cm woman presented for repeat aortic and mitral valve replacements and tricuspid valvuloplasty. Past medical history was remarkable for incompetent bioprosthetic aortic and mitral valves leading to severe aortic and mitral regurgitation, congestive heart failure, and pulmonary hypertension. The TEE probe was inserted after anesthetic induction and tracheal

\* Cardiothoracic Anesthesia Fellow.

† Assistant Professor of Anesthesia.

‡ Cardiology Fellow.

Received from the Departments of Anesthesia and Medicine, Hospital of the University of Pennsylvania, 3400 Spruce Street, Philadelphia, Pennsylvania. Accepted for publication March 8, 1991.

Address reprint requests to Dr. Troianos: Department of Anesthesiology, Mercy Hospital of Pittsburgh, 1400 Locust Street, Pittsburgh, Pennsylvania 15219

Key words: Monitoring; transesophageal echocardiography. Surgery, cardiac: aortic dissection.

intubation for the evaluation of valve function and left ventricular wall motion and volume. TEE examination before initiating cardiopulmonary bypass (CPB) revealed a normal ascending and descending thoracic aorta and aortic arch. A left femoral arterial perfusion cannula (20-Fr, William Harvey<sup>®</sup>) was placed prior to sternotomy. CPB was instituted after systemic heparinization and individual cannulation of the superior and inferior vena cavae. Mean right radial arterial pressure was maintained at 50 mmHg with a  $3.5 \text{ l} \cdot \text{min}^{-1}$  CPB flow and appropriate pressure in the arterial perfusion line. Systemic hypothermia was immediately followed by ventricular fibrillation, and the aorta was cross-clamped proximal to the innominate artery with a shodded Craaford clamp.

The aortic valve was replaced *via* a transverse aortotomy. Rewarming was instituted after completion of the planned valvular surgery. After closure of the aortotomy, and with a mean radial arterial pressure of 50 mmHg, the CPB flow was briefly reduced to  $500 \text{ ml} \cdot \text{min}^{-1}$ , and the aortic cross clamp was removed. Radial artery pressure immediately decreased to 10 mmHg and remained there despite reinstitution of full CPB flow ( $3.5 \text{ l} \cdot \text{min}^{-1}$ ). The arterial catheter and tubing connections were intact, and the apparent hypotension was refractory to phenylephrine administration. The aortic root was flaccid, whereas resistance to left femoral arterial perfusion was unchanged. A right femoral artery catheter was inserted and demonstrated a mean pressure of 120 mmHg. Rectal and nasopharyngeal temperatures had steadily increased in parallel after institution of rewarming. However, after aortic unclamping, nasopharyngeal temperature plateaued at  $33^\circ \text{C}$  despite the continued increase in rectal temperature to  $37.5^\circ \text{C}$ .

The TEE probe was repositioned to evaluate the thoracic aorta. The aortic root appeared unchanged from the pre-CPB examination, but the aortic arch demonstrated spontaneous echo-contrast, and no flow could be demonstrated by color Doppler. A single lumen was visualized in the descending aorta, and no intimal flap was discernible. The surgeon cannulated the aortic root (24-Fr Flexible Aortic Arch Cannula, Sarns<sup>®</sup>) and aortocaval CPB was instituted after a 15-s period of circulatory arrest. Radial artery pressure increased to 60 mmHg. TEE demonstrated the disappearance of spontaneous echo-contrast and the reappearance of a color flow Doppler signal in the aortic arch. After reinstitution of blood flow in the aortic root, a large intimal flap extending distally from the aortic arch was discerned with TEE, after which nasopharyngeal temperature increased and electromechanical activity of the heart returned. The total time of hypotension measured in the right radial artery was 40 min.

The patient was separated from CPB with inotropic support, generating a cardiac index of  $1.8 \text{ l} \cdot \text{min}^{-1} \cdot \text{m}^{-2}$  and demonstrating good left ventricular function by TEE. The patient remained comatose from massive cerebral infarction and died 4 days postoperatively secondary to brainstem herniation.

**Case 2.** A 47-yr-old, ASA physical status 2, 104-kg, 193-cm man presented for elective mitral valve surgery because of a flail anterior leaflet secondary to ruptured chordae tendineae. Past medical history was remarkable for hypertension and smoking. His coronary arteries were normal.

The TEE probe was inserted after anesthetic induction and tracheal intubation to enable assessment of the mitral valve for repair. After median sternotomy and systemic heparinization, the anterior wall of the ascending aorta was cannulated (24-Fr Flexible Arterial Cannula, Sarns<sup>®</sup>). A 14-G cardioplegia cannula (DLP, Inc.) was inserted into the aortic root after initiation of CPB and systemic cooling. Ventricular fibrillation was immediately followed by cross clamping of the aorta with a shodded Craaford clamp. Mean arterial pressure was 65 mmHg or less during all cannulations and aortic manipulations.

During the administration of cold potassium cardioplegia, it was noted that there was a high-resistance pressure in the cardioplegia tubing and that the aortic root did not distend appropriately, and elec-

tromechanical activity persisted. Immediate aortotomy revealed a dissection at the site of the cardioplegia cannula. Cardioplegia was infused directly into the coronary ostia, resulting in an isoelectric electrocardiogram. The aortic root could not be visualized after aortotomy by TEE because of air, but TEE demonstrated that the dissection did not extend beyond the cross clamp. A prosthetic mitral valve was placed *via* a left atriotomy, and the ascending aortic dissection was repaired by oversewing with 3-0 polypropylene suture and felt strips.

After closure of the aortotomy, removal of air and removal of the aortic cross clamp, the ascending aorta, aortic arch, and descending aorta were reevaluated by TEE. The dissection was confined to the aortic root with extension to the aortic annulus (fig. 1). TEE demonstrated a structurally intact aortic valve with no valvular incompetence. Before termination of CPB, the transgastric short-axis view of the left ventricle revealed a new segmental wall motion abnormality in the posterior-inferior wall. Acute ST elevation in leads II, III, and AVF was consistent with transmural posterior-inferior ischemia of the left ventricle. The TEE basal short-axis view at the level of the aortic root demonstrated dissection surrounding the right coronary ostium. However, blood flow from the true lumen to the right coronary artery was verified by color flow Doppler, and no communication between the false and true lumens was apparent.

Coronary artery bypass grafting and further surgical interventions were not pursued on the basis of the TEE findings. Coronary perfusion pressure was increased with phenylephrine and nitroglycerin with concomitant monitoring for possible extension of the dissection into the arch and descending aorta. Pharmacologic treatment resulted in normalization of the ST segments and wall motion. The patient was separated from CPB without inotropic support. Postoperatively the patient was hemodynamically stable and had no further evidence of myocardial ischemia or extension of the aortic dissection.

**Case 3.** A 67-yr-old, ASA physical status 4, 40-kg, 160-cm woman presented for elective mitral valve repair and tricuspid valve annuloplasty. Her past medical history included mitral and tricuspid regurgitation, congestive heart failure, pulmonary hypertension, and atrial fibrillation.

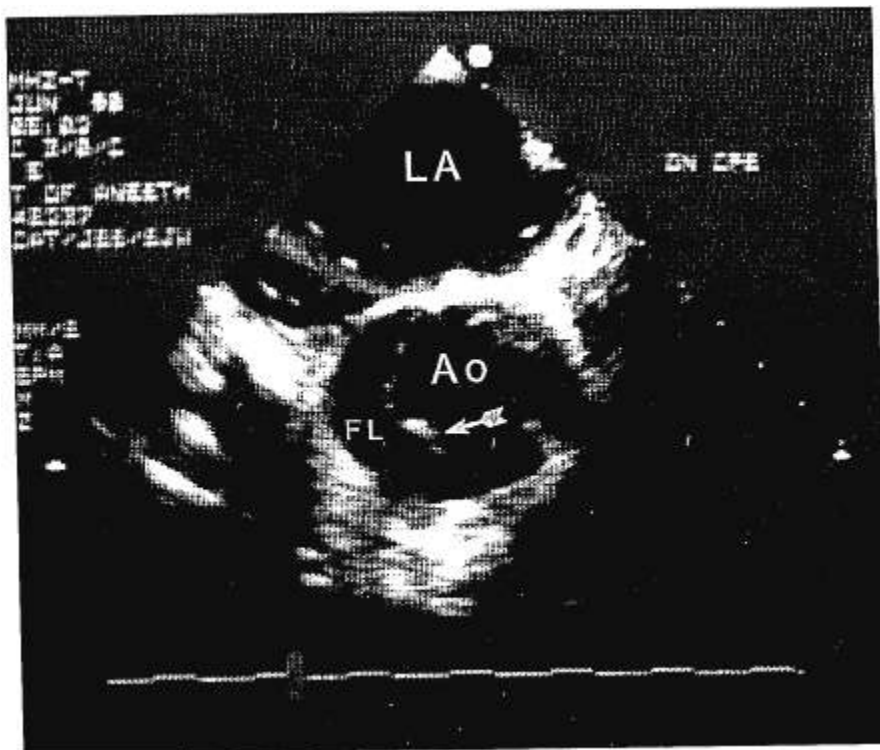
The TEE probe was inserted after anesthetic induction and tracheal intubation to enable assessment of the mitral valve for repair. The patient was prepared for CPB as in case 2. Mean arterial pressure was 65 mmHg or less during all cannulations and aortic manipulations. Before infusion of cardioplegia, the surgeon noted hematoma formation in the anterior wall of the ascending aorta at the site of the cardioplegia cannula. Immediate intervention included aortotomy and infusion of cardioplegia directly into the coronary ostia. Visual inspection suggested that the dissection was limited to the ascending aorta and was proximal to the cross clamp. However, TEE revealed extension of the dissection into the arch and descending thoracic aorta (fig. 2). Mitral and tricuspid valvuloplasties were performed while the dissection was monitored by TEE. After completion of the valvuloplasties, the right femoral artery was cannulated, and CPB was maintained *via* vena caval-femoral artery bypass. The ascending aorta was repaired during deep hypothermic circulatory arrest with a 22-mm soft woven Dacron<sup>®</sup> interposition tube graft. Separation from CPB required inotropic support and intraaortic balloon counterpulsation.

After termination of CPB, TEE demonstrated a decrease in flow in the false lumen of the descending aorta, severe global hypokinesis and competent mitral and tricuspid valves. The patient's cardiovascular status continued to deteriorate despite maximal pharmacologic support, and she died in the operating room.

## DISCUSSION

In a review of 6,943 cardiac surgical procedures, Murphy *et al.*<sup>1</sup> reported a 0.35% incidence of ascending aortic

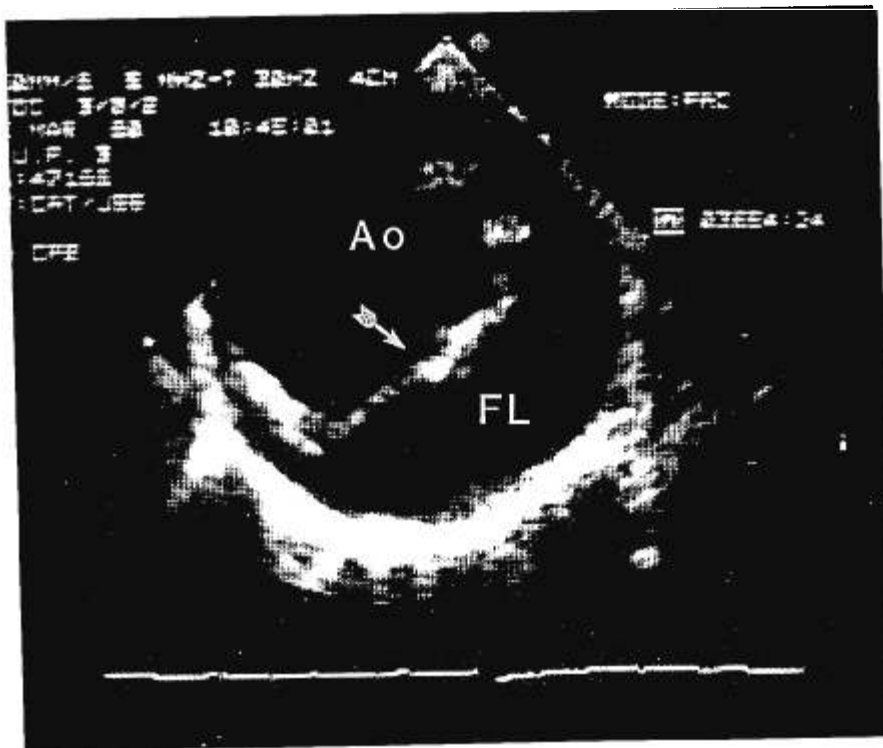
FIG. 1. Two-dimensional echocardiogram, basal short-axis view at the level of the aortic root, demonstrating dissection in the ascending aorta. Ao = true lumen; FL = false lumen; LA = left atrium. *Arrow*: intimal flap. Top is posterior.



dissection. Long-standing hypertension,<sup>8-11</sup> age greater than 50 yr,<sup>9</sup> the presence of cystic medial necrosis,<sup>11-13</sup> severe atherosclerosis of the aortic wall,<sup>10,12</sup> Marfan's syndrome,<sup>9</sup> and history of aortic coarctation<sup>9</sup> are asso-

ciated with an increased risk of aortic dissection. Surgical manipulation of the ascending aorta is the most common initiating event.<sup>1</sup> Aortotomies for the arterial cannula,<sup>13</sup> cardioplegia cannula,<sup>1</sup> and vein graft anastomoses,<sup>10,14</sup> and

FIG. 2. Two-dimensional ultrasound image demonstrating dissection in the descending thoracic aorta. Ao = true lumen; FL = false lumen; *Arrow*: intimal flap. Top is anterior.



clamping and unclamping of the ascending aorta<sup>8,12</sup> may result in intimal injury and dissection. Proximal extension of the dissection with involvement of the coronary ostia and aortic valve place the patient at risk for dissection of the coronary arteries, aortic valve incompetence, and rupture of the aorta into the pericardium. Dissection into the free walls of the heart may lead to an aortoatrial or aortic-right ventricular fistula and atrioventricular block.<sup>15</sup>

The classic symptoms, acute severe interscapular or precordial pain with radiation into the neck or arms,<sup>9</sup> are masked in the anesthetized patient. The diagnosis during surgery is made easily if there is an expanding ascending aorta, hematoma in the aortic wall, or bleeding from areas of incised adventitia or suture lines<sup>1</sup> (e.g., from the site of proximal vein graft anastomosis). Small aortic dissections, the extent of dissection, and dissections of the descending aorta usually are not obvious. Blood pressure discrepancy between different limbs is suggestive (as in case 1) but not specific. Dissection involving the carotid arteries with disruption of cerebral blood flow may result in EEG changes<sup>16</sup> or disparity in nasopharyngeal and peripheral temperatures with systemic rewarming (case 1). Disruption of renal and mesenteric arteries may lead to renal failure and ischemic bowel.<sup>15</sup> Spinal cord infarction may result in postoperative paraplegia.

The traditional methods for the diagnosis and evaluation of aortic dissections are chest x-ray, aortography,<sup>9</sup> computed axial tomography,<sup>12</sup> and transthoracic<sup>17,18</sup> and transesophageal<sup>2-6</sup> two-dimensional<sup>19,20</sup> echocardiography. With the exception of TEE, these methods are impractical in the intraoperative setting. TEE permits the early recognition of aortic dissection, the monitoring of progression, and the evaluation of surgical intervention. The combination of transthoracic echocardiography and TEE has been shown to be more sensitive than computed axial tomography and aortography in diagnosis.<sup>2,4,6</sup> The upper portion of the ascending aorta cannot be visualized with TEE because the air-filled trachea is interposed between the esophagus and ascending aorta.<sup>7</sup> TEE is especially suitable for identifying dissection of the descending thoracic aorta<sup>3</sup> and frequently can distinguish the false and true lumens. Distinguishing the true and false lumens permits monitoring of disease progression and possibly the origin of branching vessels, as in case 2. Color flow and spectral wave pulsed Doppler can be used to identify the lumen that has the higher-velocity blood flow and possibly to identify the entry site from the true to the false lumens.<sup>20</sup> Two-dimensional imaging of spontaneous echo-contrast suggests sluggish or no blood flow<sup>2</sup> (as in case 1). Movement of the intimal flap during systole usually is toward the false lumen.

Diagnosis and evaluation of aortic dissection with TEE is an skill learned only through months of dedicated

training with an active echocardiography service. Properly trained anesthesiologists<sup>7,21</sup> are qualified to make these diagnoses. The attendance of a cardiologist experienced in echocardiography<sup>7,22</sup> for the confirmation of these complex findings may also be recommended.

The utility of TEE in the diagnosis and evaluation of aortic dissection outside of the operating room has been well established.<sup>2-6</sup> In the cases reported above, TEE was instrumental for the diagnosis, evaluation, and management of aortic dissection intraoperatively. In case 1, the intraoperative diagnosis and extent of dissection was first established by TEE. The absence of a false lumen in the ascending aorta permitted the placement of an aortic root perfusion cannula. The return of flow to the aortic arch with institution of arterial perfusion in the aortic root was confirmed by TEE. In cases 2 and 3, aortic dissection was suspected and was believed to be confined to the cardioplegia site in the ascending aorta. Intraoperative TEE confirmed the diagnosis of aortic dissection and identified the extension of the dissection to the descending thoracic aorta (case 3) and toward the aortic annulus (case 2). In case 2, TEE confirmed communication between the right coronary artery and the true lumen, thereby making coronary artery bypass grafting unnecessary.

Patient outcome depends on early recognition and management. Mortality from aortic dissection during cardiac surgery is 33% when the diagnosis is made intraoperatively, compared to 78% when the diagnosis is made postoperatively.<sup>1</sup> Although aortic dissection as a complication of cardiac surgery is uncommon, we believe that imaging of the acoustically accessible segments of the aorta should be part of every TEE examination. The diagnosis, evaluation, and management of aortic dissection during cardiac surgery can be accomplished earlier if surgical manipulation of the aorta is followed by TEE examination of the segments at risk. Examination of the thoracic aorta immediately after aortic or femoral artery cannulation, clamping, and unclamping is recommended. Femoral artery cannulation for CPB poses the risk of aortic dissection in segments of the aorta that are not accessible for direct visual inspection. Diagnosis of subclinical dissection and intervention directed earlier in the course of aortic dissection may prevent prolonged periods of vital organ ischemia, as in case 1. With increased availability and a higher index of suspicion, TEE may become instrumental in the diagnosis and monitoring of this ominous complication.

#### REFERENCES

1. Murphy DA, Craver JM, Jones EL, Bone DK, Guyton RA, Hatcher CR: Recognition and management of ascending aortic dissection complicating cardiac surgical operations. *J Thorac Cardiovasc Surg* 85:247-256, 1983
2. Erbel R, Mohr-Kahaly S, Rennollet H, Brunier J, Drexler M, Wittlich N, Iversen S, Oelert H, Thelen M, Meyer J: Diagnosis of

- aortic dissection: The value of transesophageal echocardiography. *Thorac Cardiovasc Surgeon* 35(special issue):126-133, 1987
3. Engberding R, Bender F, Grosse-Heitmeyer W, Most E, Muller US, Bramann HU, Schneider D: Identification of dissection of aneurysm of the descending thoracic aorta by conventional and transesophageal two-dimensional echocardiography. *Am J Cardiol* 59:717-719, 1987
  4. Erbel R, Engberding R, Daniel W, Roelandt J, Visser C, Rennollet H: Echocardiography in diagnosis of aortic dissection. *Lancet* 1:457-461, 1989
  5. Muge A, Daniel WG, Laas J, Grote R, Lichtlen PR: False-negative diagnosis of proximal aortic dissection by computed tomography or angiography and possible explanations based on transesophageal echocardiographic findings. *Am J Cardiol* 65:527-529, 1990
  6. Erbel R, Borner N, Stellar D, Brunier J, Thelen M, Pfeiffer C, Mohr-Kahaly S, Iversen S, Oelert H, Meyer J: Detection of aortic dissection by transesophageal echocardiography. *Br Heart J* 58:45-51, 1987
  7. Seward JB, Khandheria BK, Oh JK, Abel MD, Hughes RW, Edwards WD, Nichols BA, Freeman WK, Tajik AJ: Transesophageal echocardiography: Technique, anatomic correlations, implementation, and clinical applications. *Mayo Clin Proc* 63:649-680, 1988
  8. Boruchow IB, Iyengar R, Jude JR: Injury to ascending aorta by partial-occlusion clamp during aorta-coronary bypass. *J Thorac Cardiovasc Surg* 73:303-305, 1977
  9. Kirklin JW, Barratt-Boyes BG: *Acute aortic dissection*, Cardiac Surgery, New York, John Wiley and Sons, 1986, pp 1471-1491
  10. Nicholson WJ, Crawley IS, Logue RB, Dorney ER, Cobbs BW, Hatcher CR: Aortic root dissection complicating coronary bypass surgery. *Am J Cardiol* 41:103-107, 1978
  11. Williams CD, Suwansirikal S, Engleman RM: Thoracic aortic dissection following cannulation for perfusion. *Ann Thorac Surg* 18:300-304, 1974
  12. Litchford B, Okies JE, Sugimura S, Starr A: Acute aortic dissection from cross-clamp injury. *J Thorac Cardiovasc Surg* 72:709-713, 1976
  13. Reinke RT, Harris RD, Klein AJ, Daily PO: Aortoiliac dissection due to aortic cannulation. *Ann Thorac Surg* 18:295-299, 1974
  14. Archer AG, Choyke PL, Zeman RK, Green CE, Zuckerman M: Aortic dissection following coronary artery bypass surgery: Diagnosis by CT. *Cardiovasc Intervent Radiol* 9:142-145, 1986
  15. Roberts WC: Aortic dissection: anatomy, consequences, and causes. *Am Heart J* 101:195-214, 1981
  16. Michaels I, Sheehan J: EEG changes due to unsuspected aortic dissection during cardiopulmonary bypass. *Anesth Analg* 63:946-948, 1984
  17. Smuckler AI, Nomeir A-M, Watts LE, Hackshaw BT: Echocardiographic diagnosis of aortic root dissection by M-mode and two-dimensional techniques. *Am Heart J* 103:897-904, 1982
  18. Mathew T, Nanda NC: Two-dimensional and doppler echocardiographic evaluation of aortic aneurysm and dissection. *Am J Cardiol* 54:379-385, 1984
  19. Enia F, Ledda G, Lo-Mauro R, Matassa C, Raspanti G, Stabile A: Utility of echocardiography in the diagnosis of aortic dissection involving the ascending aorta. *Chest* 95:124-129, 1989
  20. Iliceto S, Nanda NC, Rizzon P, Hsu MC, Goyal RG, Amico A, Sorino M: Color Doppler evaluation of aortic dissection. *Circulation* 75:748-755, 1987
  21. Vandenberg BF, Kerber RE: Transesophageal echocardiography and intraoperative monitoring of left ventricular function. *ANESTHESIOLOGY* 73:799-801, 1990
  22. Popp RL, Winters WL: Clinical competence in adult echocardiography. *Circulation* 81:2032-2035, 1990

Anesthesiology  
75:153-155, 1991

### Intraoperative Ventilator-induced Right-to-left Intracardiac Shunt

RICHARD A. JAFFE, M.D., PH.D.,\* FAUSTO J. PINTO, M.D.,† INGELA SCHNITTGER, M.D.,‡  
JOHN G. BROCK-UTNE, M.D., F.F.A.(S.A.)§

The inadvertent introduction of air into the venous system during surgery is believed to be fairly common but is of limited clinical significance because of the typically

small volumes involved and because of the filtering capacity of the lungs. However, even a small volume of air entering the left side of the heart (paradoxical embolization) has the potential to obstruct portions of the cerebral or coronary circulations with possibly disastrous consequences.<sup>1</sup>

Paradoxical embolization is believed to occur most commonly through the foramen ovale, which is known from autopsy studies to be probe-patent in up to 34% of the adult population.<sup>2</sup> Provocative maneuvers such as coughing or Valsalva's maneuver are known to cause rapid changes in intrathoracic pressure associated with reversal of interatrial pressure gradients.<sup>3</sup> Transthoracic echocardiographic studies using these maneuvers performed in normal subjects and in patients before surgical procedures reported a 6-10% incidence of patent foramen ovale

\* Assistant Professor, Department of Anesthesia.

† Fellow, Department of Internal Medicine.

‡ Assistant Professor, Department of Internal Medicine.

§ Professor, Department of Anesthesia.

Received from the Department of Anesthesia and the Department of Internal Medicine (Cardiology Division), Stanford University School of Medicine, Stanford, California. Accepted for publication March 18, 1991.

Address reprint requests to Dr. Jaffe: Department of Anesthesia, Stanford University School of Medicine, Stanford, California 94305-5123

Key words: Embolism: air. Heart: patent foramen ovale. Monitoring: intraoperative transesophageal echocardiography. Ventilation: controlled; mechanical; positive end expiratory pressure.