

Observation of Spinal Canal and Cisternae with the Newly Developed Small-diameter, Flexible Fiberscopes

Koki Shimoji, M.D.,* Hitoshi Fujioka, M.D.,† Mayumi Onodera, M.D.,† Tamaki Hokari, M.D.,†
Satoru Fukuda, M.D.,‡ Naoshi Fujiwara, Ph.D.,† Tsuruo Hatori, B.S.§

Small-diameter (0.5-, 0.9-, and 1.4-mm) flexible fiberscopes were developed for visual diagnosis of spinal canal diseases. The fiberscopes were introduced *via* a Tuohy needle into the subarachnoid and epidural spaces of ten patients with various pain syndromes. Clear visualization of the subarachnoid space was achieved using the fiberscopes. The epidural space could be visualized only during withdrawal of the fiberscope. In five cases, the fiberscope could be advanced up to the level of the cisternae without causing the patient any discomfort. A slight headache and transient fever were noted after the examination in five and two cases, respectively, but no other complications occurred. Interestingly, preexisting pain diminished (two cases) or disappeared (one case) after the myeloscopy in three of five cases in which the myeloscopy revealed aseptic adhesive arachnoiditis. Further studies should be carried out to evaluate the usefulness of this technique. (Key words: Anesthetic techniques: epidural; spinal. Equipment: fiberoptic myeloscope; fiberscope.)

BURMAN¹ FIRST TRIED to visualize the spinal canal using an arthroscope in the spines of cadavers. Several attempts²⁻⁴ were made thereafter to observe patients' spinal structures with large-diameter rigid endoscopes. Due to defects in endoscopic mechanics, photographic pictures could not be taken until Ooi and Morisaki⁵ successfully took clear color pictures of the spinal canal in a patient with a ruptured disc. Since then the structures of the lumbar spinal cord and cauda equina have been observed intensively by Ooi and colleagues⁶⁻⁹ and Mita and colleagues¹⁰ with rigid or flexible "myeloscopes".

For observation along the entire length of the spinal cord, however, a small-diameter and flexible fiberscope should be used to avoid mechanical injuries to the cord or roots. We have developed small-diameter, flexible fiberscopes for the this purpose and have tested them in

our pain clinic in patients with back pain. A preliminary report has been made elsewhere.[¶]

Materials and Methods

Epiduroscopy and myeloscopy were performed in ten patients admitted to our pain clinic for treatment of back or leg pain, as listed in table 1. Prior to the investigation, informed consent was obtained from all patients in accordance with the Ethical Committee of this University Hospital.

The patients had been treated by continuous epidural block or epidural spinal cord stimulation for their pain. These treatments were suspended until 5-7 days after the tests. All patients had normal coagulation tests and platelet counts before the test.

The patients were placed in lateral decubitus on the operating table. After aseptic cleaning of the skin and local anesthesia with 5-7 ml 0.5% lidocaine, a specially designed Tuohy needle, 14- or 16-G, was percutaneously introduced by paramedian approach, angled approximately 45° in the coronal plane, into the epidural and/or subarachnoid space at the L5-S1-interspace level. The internal edge of the bevel of the Tuohy needle was polished to avoid damage to the fiberscope during advance and withdrawing maneuvers. The technique for introduction of the needle into the epidural and subarachnoid spaces was basically the same as that of continuous epidural anesthesia. The fiberscopes were introduced through the needle and advanced rostrally by direct visualization, by a video image system, and by the guidance of x-ray imaging.

Three types of small-diameter (Precise Fiberscope 14, 1.4 mm; PF-9, 0.9 mm; and PF-5, 0.5 mm external diameter), soft and flexible fiberscopes (fig. 1 and table 2), jointly developed by Olympus Kogaku Co. and our laboratory, were used. The 16-G Tuohy needle was used for introducing the smallest size fiberscope (PF-5, 0.5 mm), and the 14-G needle was used for the fiberscopes of 0.9-

* Professor of Anesthesiology.

† Assistant of Anesthesiology.

‡ Associate Professor of Anesthesiology.

§ Development staff, Third Department of Development, Olympus Kogaku Co., Japan.

Received from the Department of Anesthesiology, Niigata University School of Medicine, Asahi-machi, Niigata, Japan, and the Third Department of Development, Olympus Kogaku Co., Japan. Accepted for publication April 24, 1991. Supported in part by a grant-in-aid (02557058) from the Japanese Ministry of Education, Science, and Culture.

Address reprint requests to Dr. Shimoji: Department of Anesthesiology, Niigata University School of Medicine, #1-757, Asahi-machi, Niigata 951, Japan.

¶ Shimoji K, Fukuda S, Fujioka H, Matuki M, Fujiwara N, Kawashima M: Development of fine fiberscopes for subarachnoid and epidural spaces (in Japanese). The Journal of Japan Society for Clinical Anesthesia 8:215-220, 1988.

TABLE 1. The Diseases and Complaints of Patients and the Results and Conditions of Observation by Spinal Fiberscope

Patient Number	Age (yr)	Sex	Diagnosis	Transient Complaints	Fiberscope Type	Visualized Space	Level of Observation	Abnormal Findings	Complications
87-04-06	67	M	Disc herniation postoperatively	Leg pain	PF14 PF9	Ep, Sd	S ₁ -T ₁₂	NP	None
87-07-13	69	F	Aseptic arachnoiditis	Lumbago Leg paresis	PF14 PF9	Sd	S ₁ -T ₁	Many arachnoid filaments	Headache fever (38° C)
87-10-26	67	M	Shoulder-neck syndrome	Shoulder-neck pain, dysethesia	PF14 PF9	Sd	S ₁ -C _m	NP	None
88-02-01	40	M	Chronic aseptic arachnoiditis	Back pain	PF14 PF9	Ep, Sd	S ₁ -C _b	Many arachnoid filaments	Headache
88-02-22	57	M	Chronic aseptic arachnoiditis	Lumbago, leg pain	PF14 PF9	Ep, Sd	S ₁ -T ₂	Many arachnoid filaments and adhesions	Headache
88-05-02	64	F	Posttraumatic pain syndrome	Arm pain	PF14 PF9	Sd	S ₁ -C _m	NP	None
88-11-28	53	F	Posttraumatic pain syndrome	Leg pain	PF14 PF9 PF5	Ep, Sd	S ₁ -T ₈	NP	Headache
89-02-01	69	M	Spinal cord injury	Paraplegia, dysethesia	PF14 PF9 PF5	Sd	S ₁ -T ₄	Adhesion	None
89-07-29	54	F	Chronic aseptic adhesive arachnoiditis	Lumbago	PF14 PF9 PF5	Sd	S ₁ -T ₆	Many arachnoid filaments	None
89-09-13	62	F	Aseptic arachnoiditis	Paresthesia at legs	PF14	Ep, Sd	S ₁ -C _m	Arachnoid filaments and adhesions	Headache, fever (38° C)

Ep = epidural space; Sd = subarachnoid space; C_m = cisterna cerebellomedullaris; C_b = cisterna basalis; NP = no pathology.

and 1.4-mm diameter (PF-9 and PF-14). The fiberscopes were sterilized by formaldehyde (Efgren®, Tateishi Chemicals, Kumamoto, Japan) for 10 h in a plastic box (35 × 35 × 60 cm³) and then placed in the same box 2-4 days before the tests. On the day of investigation, the fiberscopes were washed intensively by sterilized distilled water.

The epidural or subarachnoid space was identified visually by the fiberscopes, which also were attached to a camera (Olympus OTV-F) or to a video cassette recording

system (Victor CR850) for monitoring and recording. Photographs were taken using an oral esophageal stethoscope high-intensity light source (Olympus CLV-10) and color film (Olympus 1604-D).

The patients were asked frequently by the operator if there was pain or dysethesia during the manipulations. During the procedure, sedatives or local analgesics were not used, in order to avoid the patient's inability to perceive pain and other discomfort. Vital signs and the electrocardiogram also were monitored. Lactated Ringer's

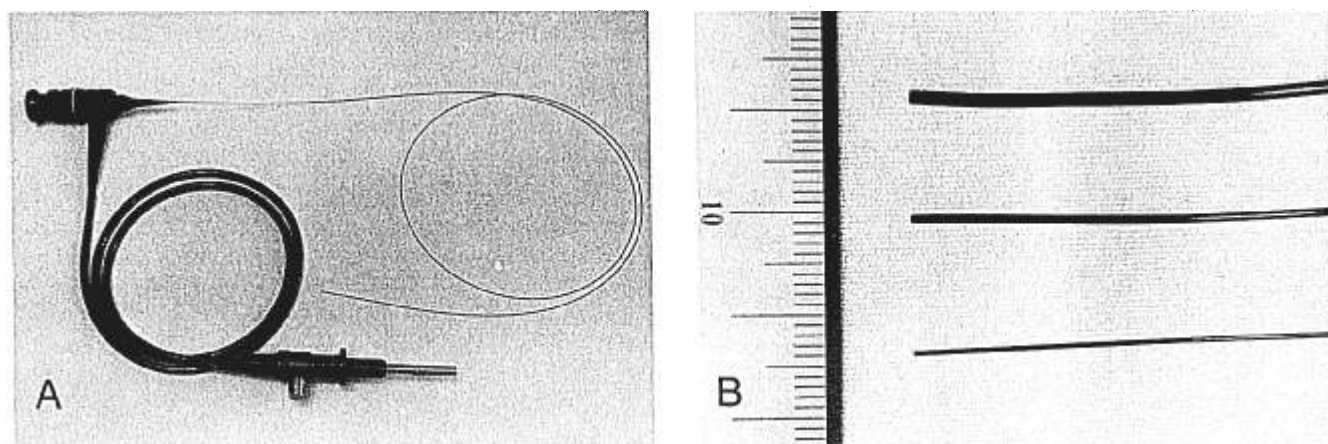


FIG. 1. A: The fiberscope (PF5) with its lead to a high-intensity light source. B: Tips of three types of fiberscopes with diameter of 1.4 (PF14), 0.9 (PF9), and 0.5 mm (PF5), shown from top to bottom, respectively.

TABLE 2. Properties of the Three Newly Developed Spinal Fiberscopes Used

	PF14	PF9	PF5
Depth of view (mm)	2-50	1-20	1-8
Angle of view (°)	75	70	60
External diameter (mm)	1.4	0.9	0.5
Length of fiber (m)	1.2	1.28	1.5
Total length (m)	1.4	1.5	1.64

solution was infused through a forearm vein throughout the procedure.

Results

In all patients tested, the spinal cord, roots and accompanying blood vessels, arachnoids, and dura mater were visualized clearly (fig. 2A). The segment of the nerve root

being visualized was identified by the position of the tip of the fiberscope, which was monitored by x-ray imaging. Sometimes, the tip of the fiberscope touched a nerve root, causing radicular pain in the region of the root being visualized. Characteristic pulsatory movements of the arachnoid and roots with their blood vessels were seen.

In four patients, the fiberscopes could be advanced up to the cisterna magna and basalis without any complaint of pain (table 1 and Fig. 2B). Three patients, including two patients with aseptic adhesive arachnoiditis, complained of slight transient discomfort or back pain when the fiberscopes were advanced to a thoracic level where they touched a dorsal root. In these three cases, the fiberscopes were slowly withdrawn.

In the patients with aseptic adhesive arachnoiditis, nerve roots were matted or clumped with filamentous tissues without evidence of other structural lesions, such that it was difficult to clearly visualize the subarachnoid space.




FIG. 2. *Top left:* Spinal cord (s), spinal roots (r) with accompanying blood vessel (v), and dura mater (d) visualized by a fiberscope (PF9). *Top right:* Cisternae cerebellomedullaris visualized by a fiberscope (PF9). Cerebellum (c), dorsal rootlets with accompanying vessels (r) and medulla (m) are demonstrated. *Bottom:* Epidural space visualized by fiberscope (PF14). Dura mater (d), a vessel (v), and a canal (h) made by the fiberscope are observed.

In three of five patients with aseptic adhesive arachnoiditis, pain disappeared (one patient) or decreased (two patients) (by 60 and 40% based on a numeric rating scale) after the fiberscopy.

An x-ray disclosed in all cases that the end of the fiberscope was situated along the dorsal or dorsolateral surface of the spinal cord. The intact epidural space could not be visualized clearly by the fiberscopes, seemingly because of the direct contact of the epidural tissues with the lens. Thus, when the track was formed with the fiberscope in the epidural space, the "track space" could be visualized during withdrawal of the fiberscope (fig. 2C). No complications other than headache (five patients) and transient (1–2 days) fever (two patients) were observed after fiberscopy (table 1). The headache was worsened by raising the head, suggesting that it was a post-dural puncture headache. The cause of the transient fever could not be determined. Both the headache and the fever were gone within 1–4 days without any specific treatments.

Discussion

The current results demonstrate that the newly developed small-diameter flexible fiberscopes might be useful for observation of the spinal canal. Clear visualization along the entire length of the spinal canal and even the cisterna magna and basalis might provide a direct inspection of these areas in detail.

It is noteworthy that pain decreased or disappeared after the fiberscopy in three of five patients with aseptic adhesive arachnoiditis, which was diagnosed by the current fiberscopy. The mechanism for pain relief after the fiberscopy is unclear. One possible explanation is that tension of the roots caused by adhesion of the arachnoids might be mechanically released by the fiberscopy. Ooi⁹ also noted pain reduction in some patients after rigid-endoscope "myeloscopy."

Our spinal fiberscopy also disclosed that an entire view of the intact epidural space is not attainable. Thus, forming a track with the fiberscope or forming a space by injecting fluid in the epidural space might be necessary for clear visualization of the epidural space. This was noticed

also by other investigators who used a rigid needle-type arthroscope for observation of the epidural space.^{11,12}

No complications other than headache with transient fever were noticed after the current procedures. In three patients, advancement of the fiberscope to the thoracic levels caused slight discomfort or pain. We withdrew the fiberscopes slowly, without any sequelae. It might be advisable, therefore, to carry out the spinal fiberscopy while patients are awake in order to detect possible undue effects.

Our myeloscopy did not identify any pathology that might explain the patient's complaints. Further study should be carried out to evaluate the usefulness of this technique and to improve the fiberscope mechanics.

The authors thank Mr. Yukio Sato, Mr. Shigeo Urano, and Mr. Shiori Kurikawa for their assistance in this study.

References

1. Burman MS: Myeloscopy or the direct visualization of spinal cord. *J Bone Joint Surg* 13:695–696, 1931
2. Stern EL: The spinascope: A new instrument for visualizing the spinal canal and its contents. *Medical Record (NY)* 143:31–32, 1936
3. Pool JL: Direct visualization of dorsal nerve roots of cauda equina by means of a myeloscope. *Arch Neurol Psychiatry* 39:1308–1312, 1938
4. Pool JL: Myeloscopy: Intrathecal endoscopy. *Surgery* 11:169–182, 1942
5. Ooi Y, Morisaki N: Intrathecal lumbar endoscope (first report) (in Japanese). *Clin Orthop Surg* 4:295–297, 1969
6. Ooi Y, Satoh Y, Morisaki N: Myeloscopy, possibility of observing lumbar intrathecal space by use of an endoscope. *Endoscopy* 5: 90–96, 1973
7. Ooi Y, Satoh Y, Hirose K, Mikanagi K, Morisaki N: Myeloscopy. *Acta Orthop Belg* 44:881–894, 1978
8. Ooi Y, Satoh Y, Inoue K, Mikanagi K, Morisaki N: Myeloscopy, with special reference to blood flow changes in the cauda equina during Lasègue's test. *Int Orthop* 4:307–311, 1981.
9. Ooi Y: Myeloscopy (in Japanese). *Orthopedics and Traumatic Surgery* 24:659–669, 1981
10. Mita F, Satoh Y, Sunaga A, Ooi Y: Myeloscopic findings for diagnosis of adhesive arachnoiditis (in Japanese). *Clin Orthopaedics (Tokyo)* 22:507–513, 1987
11. Harrison GR, Parkin IG, Shah JL: Resin injection studies of the lumbar extradural space. *Br J Anaesth* 57:333–336, 1985.
12. Blomberg RG, Olsson SS: The lumbar epidural space in patients examined with epiduroscopy. *Anesth Analg* 68:157–160, 1989