

- chemical face peeling with phenol. *ANESTHESIOLOGY* 62:366-367, 1985
5. Cline RE, Yert LW, Needham LL: Determination of germicidal phenols in blood by capillary column gas chromatography. *J Chromatogr* 307:420-425, 1984
  6. Lown B: Sudden cardiac death: The major challenge confronting contemporary cardiology. *Am J Cardiol* 43:213-228, 1979
  7. Wood KM: The use of phenol as a neurolytic agent: A review. *Pain* 5:205-229, 1978
  8. Kempthorne PM, Brown TCK: Nerve blocks around the knee in children. *Anaesth Intensive Care* 12:14-17, 1984
  9. Deichmann WB, Keplinger ML: Phenols and phenolic compounds, *Industrial Hygiene and Toxicology*. Edited by Patty FA. New York, Interscience Publishers, 1963, pp 1,363-1,375

Anesthesiology  
75:362-364, 1991

## Successful Defibrillation with Near-simultaneous Orthogonal Discharges

JAN C. HORROW, M.D.,\* GREGORY PHARO, D.O.†

Implantation of the automatic cardioverter-defibrillator (AICD) permits patients with life-threatening arrhythmias to continue their normal daily activities. Continuing operative care of these patients includes replacement of pulse generators and electrodes. Each episode of device-testing risks the inability to restore a viable cardiac rhythm.<sup>1</sup>

We encountered a case of ventricular fibrillation during AICD testing that was unresponsive to internal or external countershocks. In this instance, however, near simultaneous orthogonal countershocks using both internal paddles and the defibrillator spring-patch electrodes eventually restored sinus rhythm.

### CASE REPORT

A 58-yr-old man required left thoracotomy for placement of new AICD patches. Recurrent symptomatic ventricular tachycardia unresponsive to anti-arrhythmic therapy had prompted insertion 2 yr earlier of an INTEC® spring-epicardial-patch-configured AICD. Since implantation, that AICD had discharged successfully four times. Magnet testing of the device at a subsequent routine office visit disclosed a magnet charge of time of 30.3 s, indicating battery depletion of the pulse generator. Follow-up electrophysiologic study revealed normal resistance of the single epicardial patch, as well as normal pacing threshold, R-wave amplitude, and pulse duration. However, shocks of 20 and 30 J from an external generator, applied *via* the indwelling spring wire and patch, could not convert an induced ventricular tachycardia, and 40 J rescue cardioversion was required, similarly applied. Based on these findings, the patient's cardiologists planned replacement of the spring-patch-configured AICD with large patch defibrillation plates.

\* Associate Professor of Anesthesiology.

† Resident in Anesthesiology.

Received from the Department of Anesthesiology, Hahnemann University, Philadelphia, Pennsylvania. Accepted for publication April 8, 1991.

Address reprint requests to Dr. Horrow: Department of Anesthesiology, Hahnemann University, Broad and Vine Streets, Philadelphia, Pennsylvania 19102-1192.

Key words: Circulation: extracorporeal. Heart: arrhythmia; defibrillation; automatic implantable cardioverter-defibrillator.

The patient had undergone previous coronary artery bypass graft surgery and had had previous myocardial infarctions, and suffered from hypertension and chronic obstructive pulmonary disease. Repeat cardiac catheterization just prior to AICD replacement revealed an ejection fraction of 13%, totally occluded left anterior descending and right coronary arteries, normal left main and left circumflex coronary arteries, and patent vein grafts to the left anterior descending and right coronary arteries. Medical therapy included oral amiodarone 200 mg twice daily, 1 g sustained release procainamide four times daily, diltiazem 60 mg three times daily, digoxin 0.25 mg daily, and furosemide 40 mg daily.

He received preanesthetic medication with intramuscular morphine sulfate and scopolamine. Monitors included surface electrocardiogram (leads II and V5, continuously), pulse oximetry, a radial arterial catheter, and an oximetry pulmonary artery catheter.‡ Etomidate 20 mg, lidocaine 140 mg, and sufentanil 100 µg provided anesthesia, and vecuronium 8 mg provided muscle relaxation for intubation. One episode of spontaneous ventricular tachycardia converted to sinus rhythm with 20 J from an external generator applied *via* the spring wire and patch.

New large patch-patch electrode placement proceeded. A CPI® external cardioverter defibrillator tested the defibrillation threshold of the new patches. During testing, ventricular fibrillation induced with alternating current by epicardial leads could not be successfully converted despite incremental increases in defibrillation energy (15, 20, and then 40 J). Internal cardiac massage began. External defibrillation at 360 J *via* R2 rescue pads failed five times. More than ten additional attempts to defibrillate *via* the old spring and patch, internal paddles, and external R2 pads also were unsuccessful. Defibrillation attempts continued during and after administration of each of the following drugs: lidocaine 100 mg intravenous (iv) bolus twice and infusion at 2 mg · min<sup>-1</sup>; epinephrine 6 µg iv bolus and infusion of 4 µg · min<sup>-1</sup>; sodium bicarbonate 44 mEq iv; bretylium 350 mg iv and then 700 mg iv with 2 mg · min<sup>-1</sup> infusion; and isoproterenol infusion at 2 µg · min<sup>-1</sup>.

After 15 min of cardiopulmonary resuscitation, extracorporeal circulation (ECC) was instituted *via* femoral artery and vein. During 52 min of ECC, 28 attempts to defibrillate with the spring-patch, epicardial patches, internal paddles, and external R2 pads at maximal energies proved unsuccessful. Finally, near-simultaneous (50 ms apart as recorded on a rapid-speed ECG recorder) discharge of internal paddles (50 J) placed perpendicular (fig. 1) to the spring-wire-epicardial-patch plane (40 J) achieved successful defibrillation. With restoration of sinus

‡ Van Riper DF, Horrow JC, Kutalek SP, McCormick D, Goldman SM: Mixed venous oximetry during automatic implantable cardioverter-defibrillator placement. *J Cardiothorac Anesth* 4:453-457, 1990.

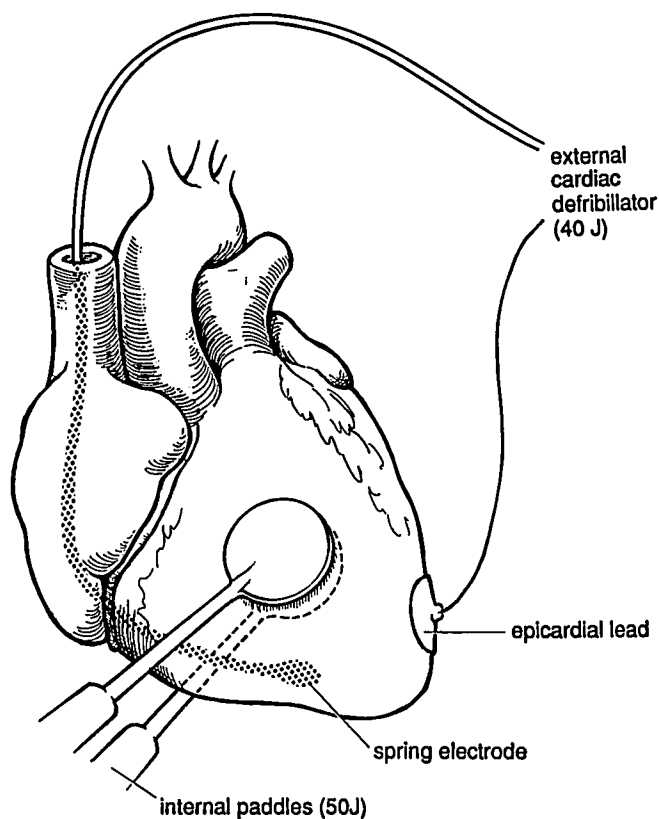


FIG. 1. Application of orthogonal depolarizations. The spring-patch-configured INTEC® AICD carried energy from an external generator, while internal paddles applied energy in a perpendicular plane.

rhythm and after 52 min total of ECC, separation from ECC proceeded with infusions of lidocaine  $2 \text{ mg} \cdot \text{min}^{-1}$  and epinephrine  $2 \mu\text{g} \cdot \text{min}^{-1}$ .

The patient recovered uneventfully without recall of surgery and without neurologic sequelae.

#### DISCUSSION

As many as 1,000 cardiac arrests occur daily in the United States.<sup>2,3</sup> Most episodes of sudden death from arrhythmia occur outside the hospital. While electrical defibrillation remains the most effective method of terminating malignant ventricular arrhythmias, its effectiveness depends on early application of sufficient energy.<sup>4</sup> Survivors of potentially fatal arrhythmias undergo cardiac electrophysiologic study to determine responsiveness to anti-arrhythmic therapy. Those not responsive may undergo AICD placement.

Since Mirowski *et al.*<sup>5</sup> and Watkins *et al.*<sup>6</sup> first reported implantation of an AICD, nearly ten thousand more have been implanted.<sup>7</sup> § Newer devices offer improved algo-

ritms for detection of fibrillation and thus result in fewer occurrences of inappropriate shock delivery (false-positive defibrillation). Other advancements include improved ease of programmability and battery testing.<sup>7-9</sup> Most fibrillation-detection algorithms require sensing of both a rapid rate and a decreased percentage of the cardiac cycle that is isoelectric.<sup>5,8,10,11</sup> These devices require 15-20 s to sense an arrhythmia, charge their internal capacitors, and deliver the energy.

This patient's AICD had malfunctioned not in rhythm-sensing but in effective energy delivery. For that reason, his spring-wire-patch electrodes were replaced with patch-patch electrodes, providing greater contact area. This patient exemplifies the importance of early delivery of effective shocks. Initial delivery of ineffective, low-energy shocks may have permitted the development of myocardial ischemia, thus rendering him more resistant to the subsequent shocks of higher energy. This patient received amiodarone, an antiarrhythmic that increases the defibrillation threshold<sup>12</sup> and thus perhaps contributes to the difficulty in achieving successful countershock. Intervention with ECC allowed for myocardial recovery, which contributed toward the eventual success in achieving defibrillation. Continued acidosis and ischemia might have resulted in the patient's death had not ECC been instituted in a timely fashion. ECC should be available in institutions where AICD testing is performed. Could recovery of myocardial function during ECC alone account for the eventual success of countershock in this patient? We believe not, since attempted rescue countershock at maximal energy after nearly 1 h of ECC failed. The near-simultaneous orthogonal depolarizations contributed significantly to the ultimately successful outcome.

Successful defibrillation requires passage of sufficient electrical current through the heart. Two theories currently account for successful defibrillation with sufficient current. The older "critical mass" hypothesis contends that depolarization of a critical mass of myocardium extinguishes activation fronts within it by depolarizing all nonrefractory tissue.<sup>2,6,13</sup> More recent investigations claim to disprove the critical mass theory by demonstrating reinitiation of fibrillation despite abolition of all epicardial, septal, and endocardial activation.<sup>14</sup> The newer theory formulates an upper limit of ventricular vulnerability; shocks below defibrillation threshold are unsuccessful because they stimulate portions of myocardium during their vulnerable period and thus reinitiate ventricular fibrillation. Either theory predicts the success of orthogonal near-simultaneous shocks.

In this case, sufficient energy at proper orientation to achieve successful depolarization could not be supplied by maximal energy (360 J) during operation. Successful depolarization required two near-simultaneous (50 ms)

§ Deutsch N, Hantler CB, Morady F, Kirsh M: Perioperative management of patients undergoing automatic internal cardioverter/defibrillator implantation. *J Cardiothorac Anesth* 4:236-244, 1990.

countershocks oriented in different geometric planes. Bardou *et al.* described a 64% reduction in the total defibrillation energy needed to countershock dogs, with the delivery of two orthogonal shocks 100 ms apart.<sup>15</sup> Jones *et al.* delivered two near-simultaneous (0.2 ms apart) sequential shocks to patients with a specially constructed spring electrode and epicardial patch, providing different orientations. Sequential shock delivery at low energy (7.5 J) successfully defibrillated more patients than did single shocks.<sup>16</sup>

This case demonstrates several important management aspects of AICD implantation. First, AICD testing can result in refractory ventricular fibrillation. Second, immediate access to ECC during testing of AICD patches may prove life-saving. Third, near-simultaneous orthogonal countershocks may be useful during AICD threshold testing. This last principle may be applicable whenever repeated single maximal-energy countershocks prove unsuccessful.

Dr. F. B. Amin, Dr. D. McCormick, Dr. S. P. Kutalek, and Dr. D. T. Seitman provided clinical information that enabled the authors to report this case.

#### REFERENCES

1. Vlay SC: Defibrillation threshold testing: Necessary but evil? (editorial). *Am Heart J* 117:499-504, 1989
2. Jaffe AS: Textbook of Advanced Cardiac Life Support. Dallas, American Heart Association, 1987, pp 89-96
3. Gaba DM, Wyner J, Fish KJ: Anesthesia and the automatic implantable cardioverter-defibrillator. *ANESTHESIOLOGY* 62:786-792, 1985
4. Weaver WD, Cobb LA, Hallstrom A, Fahrenbuch C, Copass MK, Ray R: Factors influencing survival after out-of-hospital cardiac arrest. *J Am Coll Cardiol* 7:752-757, 1986
5. Mirowski M, Reid PR, Mower MM, Watkins L, Gott VL, Schauble JF, Langer A, Heilman MS, Kolenik SA, Fischell RE, Weisfeldt ML: Termination of malignant ventricular arrhythmia with an implantable automatic defibrillator in human beings. *N Engl J Med* 303:322-324, 1980
6. Watkins L, Mirowski M, Mower MM, Reid PR, Griffith LSC, Vlay SC, Weisfeldt ML, Gott VL: Automatic defibrillation in man: The initial surgical experience. *J Thorac Cardiovasc Surg* 82:492-500, 1981
7. Mirowski M, Mower MM: Hemodynamic sensors for implantable defibrillators. *J Am Coll Cardiol* 15: 656-657, 1990
8. Gabry MD, Brodman R, Johnston D, Frame R, Kim SG, Waspe LE, Fisher JD, Furman S: Automatic implantable cardioverter-defibrillator: Patient survival, battery longevity and shock delivery analysis. *J Am Coll Cardiol* 9: 1349-1356, 1987
9. Kelly PA, Cannom DS, Garan H, Mirabal GS, Harthorne JW, Hurvitz RJ, Vlahakes GJ, Jacobs ML, Ilvento JP, Buckley MJ, Ruskin JN: The automatic implantable cardioverter-defibrillator: Efficacy, complications and survival in patients with malignant ventricular arrhythmias. *J Am Coll Cardiol* 11:1278-1286, 1988
10. McGovern BA, Garan H, Ruskin JN: Treatment of ventricular arrhythmias. *Curr Probl Cardiol* 12: 842-845, 1988
11. Winkle RA, Stinson EB, Echt DS, Mead RH, Schmidt P: Practical aspects of automatic cardioverter/defibrillator implantation. *Am Heart J* 108:1335-1346, 1984
12. Guarnieri T, Levine JH, Veltri EP, Griffith LSC, Watkins L, Juan-teguy J, Mower MM, Mirowski M: Success of chronic defibrillation and the role of antiarrhythmic drugs with the automatic implantable cardioverter/defibrillator. *Am J Cardiol* 60:1061-1064, 1987
13. Zipes DP, Fischer J, King RM, Nicoll AdeB, Jolly WW: Termination of ventricular fibrillation in dogs by depolarizing a critical mass of myocardium. *Am J Cardiol* 36:37-44, 1975
14. Chen P-S, Shibata N, Dixon EG, Martin RO, Ideker RE: Comparison of the defibrillation threshold and the upper limit of ventricular vulnerability. *Circulation* 73:1022-1028, 1986
15. Bardou AL, Degonde J, Birkui PJ, Auger P, Chesnais J-M, Duriez M: Reduction of energy required for defibrillation by delivering shocks in orthogonal directions in the dog. *PACE* 11(part II): 1,990-1,995, 1988
16. Jones DL, Klein GJ, Guiraudon GM, Sharma AD, Kallok MJ, Bourland JD, Tacker WA: Internal cardiac defibrillation in man: Pronounced improvement with sequential pulse delivery to two different lead orientations. *Circulation* 73:484-491, 1986