

Anesthesiology  
75:367-370, 1991

## Acute Complete Heart Block during Anesthesia in a Patient with Severe Coronary Artery Disease: Effect of Scopolamine *versus* Ischemia of the AV Node

KYUNG W. PARK, M.D.,\* EDWARD LOWENSTEIN, M.D.†

Patients with impaired left ventricular function are dependent on normal sequence of atrial and ventricular contraction to sustain adequate pumping function. We report an instance of acute complete heart block (CHB) during anesthesia for myocardial revascularization in a patient with severe coronary artery disease and impaired left ventricular function undergoing intraaortic balloon counterpulsation. The episode occurred shortly after intravenous scopolamine had been administered to aid provision of amnesia at a time when the systemic arterial pressure was also decreasing. The case raises the question of whether scopolamine has sufficient negative dromotropic effect to produce or to contribute to the occurrence of CHB.

To our knowledge, this represents the first report of a case of CHB occurring intraoperatively without an acute myocardial infarction (MI) in a patient without previous conduction defect or heart block.

### CASE REPORT

A 68-yr-old, 85-kg, ASA physical status 4 man was scheduled on a semi-emergency basis for coronary artery bypass grafting.

His initial symptoms of angina pectoris had occurred 12 months earlier. Cardiac enzymes and electrocardiograms (ECG) ruled out MI. A subsequent dipyridamole thallium-201 stress test showed anterior, apical, and septal ischemia. Six months prior to the current admission, he presented with congestive heart failure. An ECG then showed an interval anterior-wall MI with Q waves in V1 to V4; an echocardiogram showed an extensive anterolateral and apical dyskinesia, and his ejection fraction was estimated at 17% by radionuclide ventriculogram. Two days prior to admission to the Beth Israel Hospital, he presented to another hospital with an accelerating pattern of angina pectoris and was "ruled in" for a non-Q wave MI by cardiac enzymes (CPK415 IU with 13% MB). Angiography revealed 50% obstruction of the left main coronary artery as well as significant obstructions in the left anterior descending artery, obtuse marginal branch of the circumflex artery,

right coronary artery, posterior descending artery, and the right posterolateral branch in a right dominant system. During catheterization, he became hypotensive, with the pulmonary artery (PA) occlusion pressure increasing to a mean of 30 mmHg and a V wave to 45 mmHg. An intraaortic balloon pump (IABP) then was inserted. He was transferred to our hospital for further management. Cardiac enzymes indicated an ongoing non-Q wave MI. The evening before his operation, he had a 25-beat run of ventricular tachycardia, which was treated successfully with lidocaine. His rhythm was normal sinus at 80 beats per min, with a PR interval of 0.16 ms and QRS interval of 0.10 ms.

The patient's medical history was otherwise significant for essential hypertension, non-insulin-dependent diabetes mellitus, severe reflux esophagitis with a hiatus hernia, and history of poliomyelitis at age 30 yr, which had resulted in severe wasting of the lower extremities. His preoperative medications included intravenous (iv) heparin (1000 IU/h), iv nitroglycerin (dose-titrated to a mean arterial pressure (MAP) of 70-80 mm Hg), iv lidocaine (2 mg/min), diltiazem (90 mg four times per day, chronically), metoprolol (25 mg two times per day), furosemide, ranitidine, sucralfate, and regular insulin on a sliding scale.

The patient received one dose of oxazepam 30 mg orally at midnight the night before the operation. In addition to his usual medications, he received metoclopramide 10 mg preoperatively. No sedatives were added other than the oxazepam the patient was receiving as necessary in the coronary care unit. The patient developed a fever to 38.3° C the night prior to operation. Two new 14-G intravenous catheters and a right radial arterial catheter were inserted. The PA catheter in his right femoral vein was replaced with an oxygen-saturation PA catheter via the right internal jugular vein. Preinduction hemodynamic measurements revealed a central venous pressure of 13 mmHg, a PA pressure (PAP) of 57/26 mmHg, a mean PA occlusion pressure of 31 mmHg with a large V wave to >60 mm Hg, a cardiac output of 5.5 l/min, and a mixed venous oxygen saturation of 68%. The augmented radial artery diastolic pressure was 140 mmHg; the systolic pressure was 118 mmHg; and the heart rate was 82 beats per min in normal sinus rhythm.

Because of the patient's significant reflux symptoms, anesthesia was induced in a modified rapid sequence. After 1.5 mg pancuronium, 350 µg sufentanil in two increments was administered, followed by 10 mg vecuronium. Laryngoscopy and tracheal intubation were performed while cricoid pressure was applied.

After induction and tracheal intubation, the augmented diastolic pressure was 105 mmHg; the systolic pressure was 90 mmHg; and the heart rate remained unchanged at 82 beats per min. To provide amnesia, 0.1 mg iv of scopolamine was administered 5 min after induction and was followed by two more 0.1-mg increments over the next 5 min. Within 1 min after the last dose of scopolamine, the IABP briefly failed to trigger. This was followed by CHB with a narrow-QRS complex regular escape rhythm at 45 beats per min (fig. 1). This was refractory to three doses of 0.4 mg iv atropine and an isoproterenol infusion, titrated to 10 µg/min. The atrial rate increased to 130 beats per min, and the atrial rhythm changed to atrial flutter-fibrillation with an unchanged ventricular response. Median sternotomy was performed and sequential atrioventricular (AV) pacing instituted at a rate of 80 beats per min, capturing only the ventricle consistently. The remainder of the course until institution of cardiopulmonary bypass was uneventful.

\* Resident, Department of Anesthesia and Critical Care, Beth Israel Hospital; Clinical Fellow in Anaesthesia, Harvard Medical School.

† Anesthetist-in-Chief, Department of Anesthesia and Critical Care, Beth Israel Hospital; Professor of Anaesthesia, Harvard Medical School.

Received from Beth Israel Hospital and Harvard Medical School, Boston, Massachusetts. Accepted for publication April 10, 1991.

Address reprint requests to Dr. Lowenstein: Department of Anesthesia and Critical Care, Beth Israel Hospital, 330 Brookline Avenue, Boston, Massachusetts 02215.

Key words: Heart, AV node: complete heart block. Parasympathetic nervous system, anticholinergics: scopolamine. Surgery, cardiac: coronary artery bypass graft.

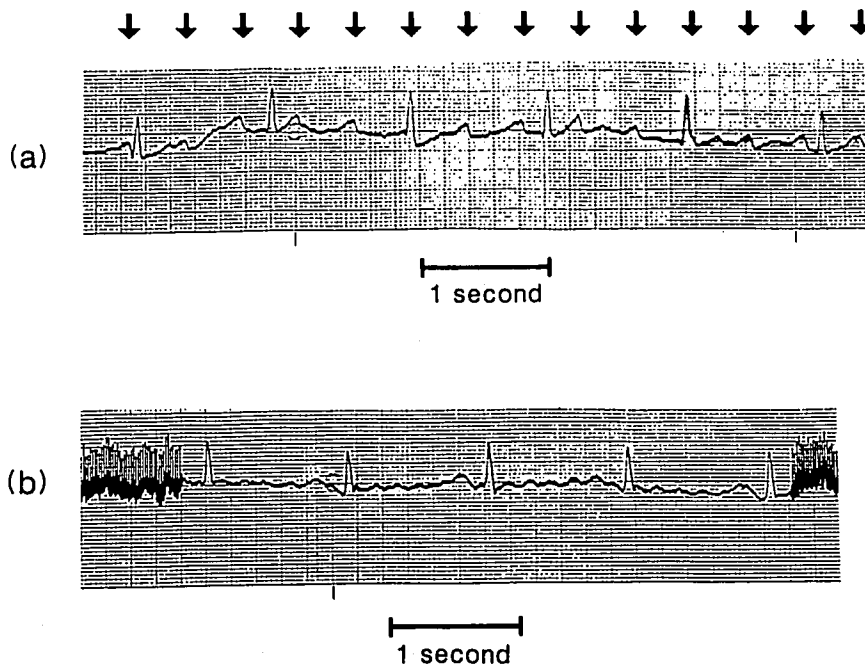


FIG. 1. ECG tracings demonstrating complete heart block. *A*: Atrioventricular dissociation with an atrial rate of about 130 and a ventricular rate of 45 beats per min. Arrows indicate P waves. *B*: After atropine and isoproterenol infusion, the atrial rhythm changed to fibrillation/flutter, but the ventricular rate remained 45 beats per min.

Antegrade administration of cardioplegic solution after aortic cross clamping was associated with lack of decrease of septal temperature and maintenance of mechanical activity. Retrograde cardioplegia *via* the coronary sinus resulted in a prompt decline of septal temperature to less than 15 °C. During a bypass time of 2 h and 42 min and a cross-clamp time of 1 h and 55 min, six distal anastomoses were constructed. After reestablishment of coronary blood flow, the heart demonstrated normal sinus rhythm without evidence of block. The patient was separated from bypass with counterpulsation and infusions of dobutamine ( $5 \mu\text{g} \cdot \text{kg}^{-1} \cdot \text{min}^{-1}$ ) and norepinephrine (dose-titrated to a MAP of 70–80 mmHg). At the conclusion of the operation, his hemodynamic parameters were a central venous pressure of 13 mmHg, a PAP of 44/23 mmHg, a left atrial pressure of 12 mmHg, and a cardiac output of 6.57 l/min. The augmented diastolic pressure was 100 mmHg; the systolic pressure was 120 mmHg; the MAP was 75 mmHg; and the heart rate was 100 beats per min in sinus rhythm.

The trachea was extubated and pharmacologic support discontinued during the first postoperative day. The IABP was removed on the second postoperative day. Cardiac enzymes revealed no evidence of a perioperative MI. There was no further evidence of heart block or any significant rhythm disturbance except for transient atrial fibrillation on the second and third postoperative days. The patient was discharged from the hospital in satisfactory condition on the 13th postoperative day.

#### DISCUSSION

This patient had the abrupt onset of CHB 10 min after induction of anesthesia. Prior to this, his heart rate and rhythm had been unchanged after induction of anesthesia, production of neuromuscular blockade, and laryngoscopy and tracheal intubation. Two things were occurring simultaneously at this time: his systemic blood pressure was decreasing, and he was receiving increments of scopolamine.

The AV node is innervated by both the parasympathetic and the sympathetic systems. Acute CHB may be caused by MI or ischemia,<sup>1</sup> coronary artery spasm,<sup>2</sup> pharmacologic agents,<sup>3</sup> infectious processes,<sup>4,5</sup> sarcoidosis,<sup>6</sup> amyloidosis,<sup>7</sup> and neoplasms.<sup>8</sup> In this patient, the most likely explanation for the observed CHB appears to be either ischemic or pharmacologic.

In about 90% of the population, the AV nodal artery branches off from the distal right coronary artery, whereas in the remainder, it is a branch of the distal left circumflex artery. In our patient, who had a right-dominant coronary arterial system, the AV nodal artery was a branch of the right coronary artery. Since he had significant obstructions in the right coronary artery, he was predisposed to AV nodal ischemia. It is also notable that the block occurred soon after the IABP failed to trigger for several moments and that antegrade cardioplegia was ineffective, suggesting that the septum and the AV node had a compromised arterial supply. Furthermore, whereas the relatively low intramural pressure in the less muscular right ventricle lessens the importance of diastolic perfusion and makes the perfusion of the endocardium greater on the right than on the left,<sup>9</sup> the perfusion pattern on the right approximates that on the left in the presence of pulmonary hypertension<sup>10</sup> (such as in our patient); the subendocardium and areas perfused mainly by collaterals are then at risk for ischemia. It is possible that with decrease in both the augmented diastolic and the systolic pressures after induction, the perfusion of the AV node became critically compromised, leading to the observed heart block.

In our patient, the heart rate and rhythm were un-

changed after induction and remained steady until the abrupt onset of CHB. After administration of atropine and isoproterenol infusion, the atrial rate increased without a concomitant resolution of the block or increase in ventricular response. Therefore, in order to postulate that a pharmacologic agent (or agents) was responsible for the observed heart block, a distinction needs to be made between a negative chronotropic effect on the sinoatrial (SA) node and a negative dromotropic effect on the AV node. In dogs,<sup>11</sup> gallamine did not block the negative chronotropic effect of acetylcholine on the SA node but did block the negative dromotropic effect of acetylcholine on the AV node, suggesting that the muscarinic receptors of the SA and AV nodes are different. Whether such a distinction can be made in humans is not known.

Bradycardia is commonly observed after administration of opioids. Proposed explanations include:‡ reduction in sympathetic tone, centrally mediated increase in vagal tone, direct negative chronotropic action, and potentiation of acetylcholine action on the sinus node. Several cases of severe bradyarrhythmia and asystole, but not CHB, have been reported; these were associated with the use of sufentanil and vecuronium, especially in patients receiving  $\beta$ -adrenergic blockers or calcium channel blockers.‡ We administered 1.5 mg pancuronium iv before sufentanil and vecuronium to attempt to avoid such bradyarrhythmias, and the heart rate and rhythm remained unchanged after induction. Opioids also may prolong AV conduction time,<sup>12</sup> and if sufentanil has a negative dromotropic effect not blocked by pancuronium, it may have been a contributing factor to the observed block.

Finally, it is interesting to consider the possible role of scopolamine in the development of CHB. Atropine has been shown to have central vagotonic properties,<sup>13</sup> and scopolamine may have similar properties.<sup>14</sup> Gravenstein and Thornby<sup>15</sup> reported that in doses of up to 0.2 mg per 70 kg, scopolamine decreased the heart rate within 10 min by about 12–15 beats per min, whereas doses ranging from 0.3 to 0.6 mg/70 kg produced an initial tachycardia followed by a more persistent bradycardia. It is possible that central vagotonia may lead to a prolongation of the AV conduction time, even to the point of a CHB. Our patient was receiving a  $\beta$ -adrenergic blocker preoperatively and may have been experiencing ischemia in the distribution of the RCA. In addition, anesthesia was induced with sufentanil, which may prolong the AV conduction time as well. It is conceivable that the combination may have been sufficient to produce CHB.

‡ Schmeling WT, Bernstein JS, Vucins EJ, Cody R: Persistent bradycardia with episodic sinus arrest after sufentanil and vecuronium administration: Successful treatment with isoproterenol. *J Cardiothoracic Anes* 4:89–94, 1990.

Anatomically, CHB may occur in the AV node, in the bundle of His, or in the bundle branches.<sup>16</sup> When the block is in the AV node, the QRS complex of the escape rhythm is of normal duration and has a rate of 40–55 beats per min. This rhythm usually responds to atropine, although when occurring after the first 24 h of an inferior MI, it is resistant to atropine.<sup>17</sup> When the block is within or distal to the bundle of His, the QRS complex of the escape rhythm is wide and has rates of less than 40 beats per min. In our patient, the escape rhythm had QRS complexes of normal duration and a rate of 45 beats per min; this suggests that the anatomic site of the block was in the AV node.

Treatment of CHB includes vagolytic agents,  $\beta$ -adrenergic agonists, and pacemakers. Administration of atropine and isoproterenol did not relieve the block. Rather, isoproterenol might have caused the atrial flutter-fibrillation. Direct epicardial pacing was effective in our patient. A PA catheter with pacing capability was not inserted prior to operation, since conduction was normal and since we were confident that the heart could be paced directly if necessary.

In conclusion, we believe that in this patient, decreased systemic arterial and coronary perfusion pressure caused or increased ischemia of the upper portion of the AV node and that this was primarily responsible for the CHB. That the septum did not cool with antegrade cardioplegia suggests that the circulation was compromised and pressure-dependent. Retrograde cardioplegia effectively cooled the septum and may have prevented tissue damage in this region and the AV node, permitting normal conduction after reestablishment of coronary arterial flow. However, we cannot rule out the possibility that scopolamine, administered to a patient who had been receiving  $\beta$ -adrenergic and calcium-channel blockers preoperatively and in whom anesthesia was induced with sufentanil and vecuronium, may have contributed to the occurrence of CHB.

#### REFERENCES

1. Willerson JT, Buta LM: Cause and course of acute myocardial infarction. *Am J Med* 69:903–914, 1980
2. Ortega-Carnicer J, Malillos M, Tascon J: Transient bifascicular block during Prinzmetal's variant angina. *Chest* 82:789–790, 1982
3. Kenny J: Calcium channel blocking agents and the heart. *Br Med J (Clin Res)* 291:1150–1152, 1985
4. McAlister HF, Klementowicz PT, Andrews C, Fisher JD, Feld M, Furman S: Lyme carditis: An important cause of reversible heart block. *Ann Intern Med* 110:339–345, 1989
5. Clarke M, Keith JD: Atrioventricular conduction in acute rheumatic fever. *Br Heart J* 34:472–479, 1972
6. Thomas DW, Mason RA: Complete heart block during anesthesia in a patient with sarcoidosis. *Anaesthesia* 43:578–580, 1988
7. Brownstein MH: Cardiac amyloidosis and complete heart block. *N Y State J Med* 66:397–399, 1966

8. Evans DW, Stovin PG: Fatal heart block due to mesothelioma of the atrioventricular node. *Br Heart J* 56:572-574, 1986
9. Hess DC, Bache RJ: The transmural right ventricular myocardial blood flow during systole in the awake dog. *Circ Res* 45:88-94, 1979
10. Lowensohn HS, Khouri EM, Gregg DE, Pyle RL, Patterson RE: Phasic right coronary artery blood flow in conscious dogs with normal and elevated right ventricular pressures. *Circ Res* 39:760-766, 1976
11. Loeb JM, De Tarnowsky JM, Johnsen JA: Differential cholinergic sensitivity of sinus and AV nodes. *Eur J Pharmacol* 83:321-324, 1982
12. Royster RL, Keeler K, Haisty K, Johnston WE, Prough DS: Cardiac electrophysiologic effects of fentanyl and combinations of fentanyl and neuromuscular relaxants in pentobarbital-anesthetized dogs. *Anesth Analg* 67:15-20, 1988
13. Katona PG, Lipson D, Dauchot PJ: Opposing central and peripheral effects of atropine on parasympathetic cardiac control. *Am J Physiol* 232:H146-H151, 1977
14. Heinekamp WJR: The central influence of atropine and hyoscine on the heart rate. *J Lab Clin Med* 8:104-111, 1922
15. Gravenstein JS and Thornby JI: Scopolamine on heart rates in man. *Clin Pharmacol Ther* 10:395-400, 1969
16. Schmidt PJ, Ezri MD, Denes P: Cardiac arrhythmias: Update 1987. *Dis Mon* 33:365-432, 1987
17. Shah PK, Nalos P, Peter T: Atropine resistant post infarction complete AV block: Possible role of adenosine and improvement with aminophylline. *Am Heart J* 113:194-195, 1987

Anesthesiology  
75:370-374, 1991

## Epidural Analgesia in Patients with Congenital Lumbosacral Spinal Anomalies

MICHAEL G. COOPER, M.B., B.S., F.F.A.R.A.C.S.,\* NAVIL F. SETHNA, M.B., CH.B.†

Epidural anesthesia, other than that by the caudal route, is now an accepted and safe technique in pediatric regional anesthesia.<sup>1-4</sup> However, spinal deformity is regarded as a relative contraindication<sup>5,6</sup> to the safe placement and use of an epidural catheter. We reviewed the records of six cases of the use of lumbar epidural blockade in patients with congenital anomalies of the sacrum and lower lumbar spine.

### CASE REPORTS

*Case 1.* A girl aged 9 months and weighing 9 kg presented with complete sacral agenesis and partial sacralization of the fifth lumbar vertebra (see fig. 1). She presented for major perineal genitourinary reconstruction of a cloaca deformity. After induction of general anesthesia, a lumbar epidural catheter was inserted at L3-L4 via a 19-G Tuohy needle using loss of resistance to air to identify the epidural space. She received 2 ml 0.5% bupivacaine, which was repeated once during the 9-h operation. On awakening in recovery the patient experienced pain, which resolved with 1 ml 0.5% bupivacaine. Since there was limited facility for postoperative infusion via the epidural

route, the catheter was removed. However, analgesia lasted only 1 h, and an intravenous morphine infusion was commenced.

*Case 2.* A girl currently aged 3 yr and weighing 16 kg had been born with sacral teratoma, cloacal exstrophy, imperforate anus, duplex vagina, and bladder exstrophy. A mature teratoma was excised and sigmoid colostomy was performed on day 1 of life. The teratoma contained ribs articulating with the lower abnormal aspect of the sacrum, and at operation there appeared to be a double sacrum with a central membrane-lined cavity that did not contain cerebrospinal fluid. There remained a calcified remnant of sacrum and a marked diastasis of the pelvis. On this admission, she underwent major abdominopelvic surgery lasting 19 h that involved bilateral iliac osteotomies, splitting of the pubic symphysis, creation of a bladder from the stomach, reimplantation of ureters, creation of a urethra and bladder neck, and excision of the vaginal septum.

Postoperatively, after tracheal extubation, she required such large doses of opioid and sedation that respiratory depression occurred and tracheal intubation was necessary. In order to decrease analgesic requirement, which included ketamine  $4 \text{ mg} \cdot \text{kg}^{-1} \cdot \text{h}^{-1}$ , a catheter was inserted 3 cm into the epidural space at the L1-L2 interspace. This proved ineffective: there was no evidence of sympathetic or sensory blockade. The catheter was reinserted via the L2-L3 interspace. Four milliliters of lidocaine 1.5% with 1:200,000 epinephrine provided motor blockade, and an infusion of 0.125% bupivacaine with fentanyl  $2 \mu\text{g}/\text{ml}$  was commenced at 7 ml/h. This provided effective analgesia and was subsequently maintained at 5 ml/h. All sedation ceased, and the trachea was extubated successfully. The infusion continued for 144 h.

*Case 3.* A girl aged 4 yr and weighing 13 kg had been born with a cloaca and a tracheoesophageal fistula. Esophageal repair, colostomy, vesicostomy, and vaginostomy were performed in the first days of life. The child developed chronic pulmonary disease secondary to recurrent aspiration despite two fundoplication procedures. She also developed asthma. The spinal anomaly consisted of hypoplasia of the lower lumbar vertebrae, partial sacral agenesis with a block fusion of L4-L5 causing kyphosis (see fig. 2). The patient underwent a 14-h major genitourinary reconstruction that included splitting of the pubic symphysis, adhesion lysis, creation of neourethra and perineal vaginoplasty, cloaca repair, and suprapubic cystostomy.

Epidural catheter placement was attempted at the end of the operation at L4-L5 and L3-L4 with a 17-G Tuohy needle. At both

\* Fellow, Pain Treatment Service.

† Assistant Professor in Anesthesia.

Received from the Department of Anesthesia, The Children's Hospital and Harvard Medical School, Boston, Massachusetts and the Department of Anaesthesia, The Children's Hospital, Camperdown, Sydney, Australia. Accepted for publication April 11, 1991. Supported in part by a research grant from Astra Pharmaceuticals Pty. Ltd., Australia (MGC).

Case 1 was performed at the Children's Hospital, Camperdown, Sydney and cases 2-6 at the Children's Hospital, Boston, Massachusetts.

Address reprint requests to Dr. Cooper: Department of Anaesthesia, The Children's Hospital, Camperdown, N.S.W. 2050, Australia.

Key words: Anatomy: spine. Anesthesia: pediatric. Anesthetic technique: epidural.