

## Assessment of Myocardial Perfusion during CABG Surgery with Two-dimensional Transesophageal Contrast Echocardiography

Solomon Aronson, M.D.,\* Bryan K. Lee, M.D.,† Jeff G. Wienczek, B.S.,‡ Steven B. Feinstein, M.D.,§  
Michael F. Roizen, M.D.,¶ Robert B. Karp, M.D.,\*\* John E. Ellis, M.D.\*

No reliable, quantifiable index of tissue perfusion is currently available to assess the efforts of coronary artery bypass graft (CABG) surgery. We used two-dimensional transesophageal contrast echocardiography with sonicated Renografin-76 microbubbles to determine the distribution of myocardial blood flow during coronary artery bypass graft surgery in 15 patients. Sonicated Renografin-76 contrast agent was injected into the aortic root of all patients after institution of cardiopulmonary bypass and application of the aortic occlusive clamp. Eight patients had contrast agent injected directly into the free proximal end of the vein-CABG anastomosis. All patients again received aortic root injections during reperfusion after anastomosis of the proximal aortovein and distal coronary artery. Echocardiographic images of the left ventricle short axis at the level of the papillary muscles were obtained in real time and analyzed retrospectively from videotape. Injection of contrast provided information about the magnitude and geometric distribution of coronary artery-vein bypass run-off and enabled identification of poorly perfused myocardial regions. When predicted myocardial perfusion patterns, based on preoperative evaluation of epicardial vessel distribution derived from coronary angiography, were compared to actual perfusion patterns assessed with intraoperative echocardiography, contrast regional myocardial perfusion patterns were predicted 84% of the time (71-97%, 95% confidence limit). Regional myocardial perfusion deficits detected after coronary bypass grafting were associated with regional wall motion abnormalities detected after separation from cardiopulmonary bypass. Our technique makes possible on-line visualization of changes in regional blood flow in the heart before, during, and after CABG. The immediate recognition of blood flow changes during CABG surgery with contrast echocardiography may allow improved revascularization in up to 16% (3-29%, 95% confidence limit) of vein grafts. (Key words: Heart: myocardial perfusion. Measurement technique, echocardiography: two-dimensional transesophageal contrast echocardiography. Surgery, cardiac: coronary artery bypass graft.)

TRADITIONAL MONITORING TECHNIQUES to assess myocardial ischemia during cardiac surgery are limited because these methods rely on the detection of adverse effects of ischemia and not its cause. The electrocardiogram, pulmonary artery catheter, and transesophageal

echocardiography, for example, rely on current of injury, repolarization abnormalities, left ventricular compliance changes, or contractile abnormalities as adverse consequences that indicate myocardial ischemia. These techniques require dysfunctional myocardial tissue to detect underlying tissue ischemia and do not offer a true measurement of the extent of nonviable myocardial tissue.<sup>1-3</sup>

The adequacy of myocardial revascularization after coronary artery bypass graft (CABG) surgery is an important concern, because 4-21% of CABG procedures are accompanied by myocardial infarction.<sup>4-6</sup> The ability to directly assess the adequacy of regional myocardial perfusion should permit more accurate identification and recognition of the cause of myocardial ischemia during CABG surgery. This identification may allow prevention of myocardial infarction postoperatively. Currently, a reliable index of myocardial perfusion to assess the effects of CABG is not available.

We and others have postulated that contrast echocardiography is a technique capable of demonstrating myocardial blood flow in patients during CABG procedures.<sup>7-10</sup> Previous efforts with contrast echocardiographic techniques have not fulfilled monitoring requirements, however, because the contrast medium could not be visualized easily in myocardial tissue with ultrasonography.

We report here the results of a contrast echocardiographic technique that uses two-dimensional transesophageal echocardiography to assess regional myocardial perfusion patterns before, during, and after saphenous vein-CABG during cardiopulmonary bypass (CPB). In addition, we tested the hypothesis that intraoperative contrast echocardiography may provide useful information about the distribution of myocardial blood flow during CABG surgery, information not easily obtained with angiographic imaging techniques.

### Materials and Methods

With institutional review board approval and individual informed consent, 15 patients (12 men and 3 women), ages 37-88 yr (mean 59.4 yr), were studied. All patients had coronary artery disease documented by recent cardiac angiography and underwent CABG. Excluded from the study were patients with documented cerebral vascular

\* Assistant Professor, Department of Anesthesia and Critical Care.

† Assistant Professor, Department of Surgery.

‡ Student, University of Chicago Pritzker School of Medicine.

§ Associate Professor, Department of Medicine.

¶ Professor and Chairman, Department of Anesthesia and Critical Care; Professor of Internal Medicine, Department of Medicine.

\*\* Professor, Department of Surgery.

Received from the Departments of Anesthesia and Critical Care, Medicine, and Surgery, The University of Chicago Pritzker School of Medicine, Chicago, Illinois. Accepted for publication May 10, 1991. Presented in part at the annual meeting of the American Society of Anesthesiologists, Las Vegas, Nevada, October 1990.

insufficiency, severe renal insufficiency requiring hemodialysis, or a history of allergy to contrast dye.

Anesthetic management was not altered in any way during any phase of the anesthetic period. All patients were monitored continuously with two-dimensional transesophageal echocardiography immediately after tracheal intubation until the end of the surgical procedure. Likewise, surgical technique was not altered in any way for the study except during the period of contrast injections. Contrast was injected after institution of CPB and after occlusion of the ascending aorta. At that time, each patient received an aortic root injection of 8 ml sonicated Renografin-76 contrast agent (E. R. Squibb & Sons, Princeton, NJ) into the cardioplegia catheter along with the cardioplegic solution. In eight of the patients, the surgeon elected to perform the distal saphenous vein graft anastomosis initially. In those eight patients, we also injected 2 ml contrast agent directly into the proximal end of the saphenous vein-CABG. At the completion of the distal and proximal vein anastomosis, and while the aorta remained occluded during CPB, all patients again received aortic root injections through the cardioplegic catheter with warm blood as the carrier solution.

The contrast agent was sonicated according to the methods first introduced by Feinstein *et al.*<sup>11</sup> with commercially available sterile Renografin-76. The process of sonication creates highly reflective, gaseous microbubbles of average diameter  $3.3 \pm 1.2 \mu\text{m}$  as indicated by laser analysis.<sup>12</sup> These microbubbles have been shown to have an average half-life of 100 s.

A sonifier (Heat Systems model 220, Ultrasonics, Plainsview, NY) was used to sonicate the Renografin-76. The half-inch titanium horn of the sonicator was sterilized

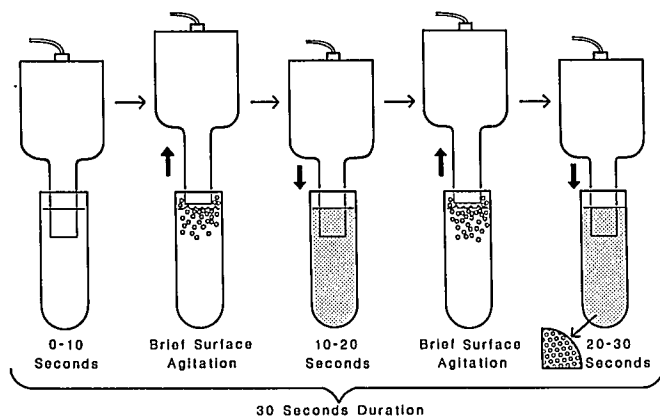


FIG. 1. The sonication process for generating Renografin-76 microbubbles. An initial 10-s emergence of the sonicator horn tip into the Renografin-76 is interrupted by brief surface agitation and then repeated once with intermittent surface agitation and once without, to create small, relatively uniform microbubbles. (Reprinted from Feinstein *et al.*<sup>12</sup> by permission of the Journal of the American Society of Echocardiography.)

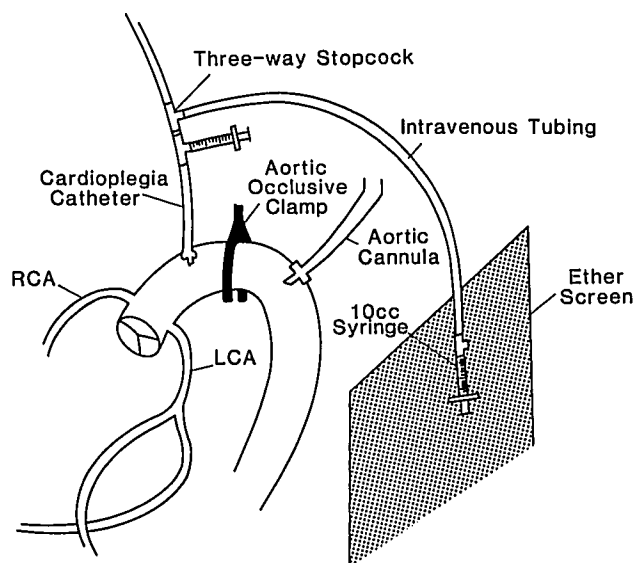


FIG. 2. After the ascending aorta was occluded, contrast was delivered from one 10-ml syringe through intravenous extension tubing into another 10-ml syringe that was connected in line to the cardioplegia cannula with two adjacent three-way stopcocks. The contrast could be injected directly into the aortic root along with cardioplegia solution, or the syringe could be removed and used to inject contrast directly into the proximal end of a coronary vein bypass graft. RCA = right coronary artery; LCA = left coronary artery.

before each use by soaking in cold sterilant solution (As-tracid-S, approved by the Food and Drug Administration) for 2 h. The sonicator horn then was rinsed with sterile water and mounted into a soundproof hood. At the time of injection, 8 ml Renografin-76 was loaded into an inverted 10 ml syringe with a closed stopcock at one end. The Renografin-76-filled syringe was held such that the level of agent was approximately 0.5 cm beneath the sonicator horn. The sonicator was turned on at an energy setting at 70% capacity. After 10 s the syringe was lowered so that the top of the sonicator touched the surface of the liquid and thus produced a brief period (less than 1 s) of surface agitation. When the surface was agitated, the tip of the sonicator was lowered beneath the surface of the liquid for another 10 s. The surface agitation process was repeated at 20 and 30 s (fig. 1). After a total sonication time of 30 s, the solution appeared translucent.

Sonicated Renografin-76 was transferred immediately to the surgeon *via* sterile intravenous tubing. The sterile end of the intravenous tubing was connected to a syringe, enabling the surgeon to aspirate contrast agent from the syringe used for sonication (fig. 2). The surgeon then injected 8 ml sonicated Renografin-76 into the cardioplegia line into the ascending aorta. In this way, injection of contrast and infusion of cardioplegia could be timed precisely. Initially, it was important to rehearse and synchronize this technique for imaging the heart with the oper-

ating surgeon because the short half-life of the sonicated contrast agent (100 s) does not allow for much time to elapse between sonication and injection of agent.

For injections directly into the saphenous vein, the surgeon received the contrast in the same manner and removed the syringe from the stopcock system before manually injecting 2 ml into the proximal end of the distal vein-CABG. The vein then was flushed with saline or blood.

Transesophageal echocardiographic images of the left ventricle (short-axis view of the level of the papillary muscles) were obtained with a 5.0-MHz transducer (RT-5000, General Electric, Milwaukee, WI). Images were recorded continuously on 0.5-inch videotape immediately before and for 2 min after each contrast injection.

Optimal gain and power settings were established at the beginning of each study and were maintained constant throughout. Imaging planes were kept constant by using the short-axis view of the papillary muscle as a reference.

Detailed analysis of the echocardiographic images was performed retrospectively from videotape. During analysis, the quality of contrast enhancement within the myocardium was determined. Images were graded on a subjective scale to be excessive (3), optimal (2), minimal (1), or not enhanced (0) (table 1). Regional myocardial perfusion patterns subtended from the proposed coronary bypass graft were predicted by three independent blinded examiners (one cardiologist and two cardiac surgeons) after a review of the preoperative coronary angiograms.

Each reviewer was asked to review a standard angiogram in his or her routine manner. Each then was asked to determine the coronary artery vessels that needed to be bypassed and to predict the region of the myocardium that would be perfused by the native coronary arteries as well as by the proposed saphenous vein CABGs. Predicted perfusion patterns then were compared with intraoperative contrast perfusion patterns (table 2). Regional myocardial perfusion patterns imaged with aortic root injections of contrast after completion of saphenous vein grafting and before separation from CPB were compared with regional wall motion after separation from CPB (table 3). Regional wall motion was assessed in each patient before and after CABG surgery (table 1).

### Results

Contrast-enhanced images of myocardial perfusion before coronary bypass surgery *via* aortic root injections of Renografin-76 were obtained in 12 of 15 patients (table 1). Three patients had severe aortic valve incompetence at the time of initial contrast injection, precluding adequate coronary artery uptake and myocardial imaging and resulting in opacification of the left ventricle after injection of contrast into the aortic root (table 1).

Myocardial perfusion patterns were visualized easily for all patients who received injections directly into the saphenous vein after distal vein-coronary artery anastomosis.

TABLE 1. Quality of Contrast Injection Enhancement

Patient	Wall Motion before CPB	Contrast Injections				Wall Motion after CPB	
		Directly into Aortic Root before SVG	Directly into SVG		Directly into Aortic Root after SVG		
1	Normal	2	LCX 2	Post desc 3	Sequential 2	2	Normal
2	Normal	1	LCX 2	Diag 2	Post desc 2	2	Normal
3	Normal	1	OM 1	Post desc 2	—	1	Normal
4	Normal	2	—	—	—	1	Normal
5	Global hypokinesis	1	Diag 2	OM 2	Post desc 2	1	Lateral wall dyskinesia-hypokinesis
6	Normal	2	—	—	—	2	Normal
7	Global hypokinesis	2	RCA 2	Diag 1	OM 1	1	Septal akinesis
8	Normal	0 (AI)	—	—	—	0 (AI)	Normal
9	Normal	2	Diag 1	OM 2	RCA 1	1	Normal
10	Normal	2	—	—	—	0	Normal
11	Normal	2	—	—	—	Did not measure	Normal
12	Normal	0 (AI)	Post desc 2	OM 2	—	0 (AI)	Normal
13	Normal	0 (AI)	—	—	—	0 (AI)	Normal
14	Normal	1	—	—	—	1	Normal
15	Normal	1	RCA 2	Diag 2	—	1	Normal

Numbers under contrast injections signify the following: 0 = not enhanced; 1 = minimal; 2 = optimal; 3 = excessive. For injections before and after SVG, the number under contrast injection refers to the quality of the whole myocardial image.

SVG = saphenous vein graft; LCX = left circumflex coronary artery; OM = obtuse marginal; AI = aortic insufficiency; Diag = diagonal; RCA = right coronary artery; CPB = cardiopulmonary bypass; Post desc = posterior descending.

TABLE 2. Comparison of Predicted Perfusion Patterns with Intraoperative Perfusion Patterns

Patient	Vessel Imaged at Angiography	Perfusion Patterns		Score
		Predicted	Actual	
1	RCA (posterior desc)	Good collateralization, posterior wall	Posterior wall	+
	Diag (sequential)	Anterior	Anterior	+
	LCX	Lateral	Lateral	+
	Ao root pre-CABG	No defects, good collateral	No defects	+
2	LCX	No filling	Lateral wall with good collateralization	-
	RCA (posterior desc)	Posterior wall	Posterior	+
	LAD (diag)	Anterior wall	Anterior	+
3	Ao root pre-CABG	No defects	No defects	+
	LCX (OM <sub>1</sub> , OM <sub>2</sub> )	Lateral wall	Lateral	+
	RCA (posterior lat and posterior desc)	Posterior wall	Posterior	+
	Ao root pre-CABG	No defect	No defect	+
4	Ao root pre-CABG	No defect	No defect	+
	LCX (OM <sub>1</sub> )	Posterior lateral wall	Posterior lateral wall	+
5	Diag	No flow	Anterior septal wall	-
	RCA (posterior desc)	Posterior wall	Posterior septal	+
	Ao root pre-CABG	No defect	No defect	+
	Ao root pre-CABG	No defect	No defect	+
6	Ao root pre-CABG	No defect	No defect	+
	RCA	Posterior	Posterior	+
	Diag	No filling	No filling	+
	OM <sub>1</sub>	Lateral	Posterior lateral	+
7	Ao root pre-CABG	Good collateral, no defect	Septal defect	-
	RCA	Post-septum	Posterior septum	+
	LCX (OM <sub>1</sub> )	Posterior	Anterior lateral	-
	Diag	Anterior lateral	Posterior lateral	+
9	Ao root pre-CABG	No flow anterior-septal	Poor anterior filling	+
	Ao root pre-CABG	No defect	No defect	+
10	Ao root pre-CABG	No defect	No defect	+
	RCA (posterior desc)	Posterior	Posterior septum	+
12	LCX (OM)	Lateral	Lateral	+
	Ao root pre-CABG	No defect	No defect	+
14	Ao root pre-CABG	No defect	No defect	+
	RCA	Posterior	Posterior	+
	Diag	No filling	Anterior lateral	-
15	Ao root pre-CABG	No defect	No defect	+

Patient 11, no angiogram available; patients 8 and 13, inadequate contrast evaluation.

For vessel imaged, parentheses indicate a different injection site.

Score: + = Perfusion as predicted; - = perfusion not as predicted.

RCA = right coronary artery; Diag = diagonal; LCX = left circumflex coronary artery; LAD = left anterior descending artery; Ao root = aortic root; CABG = coronary artery bypass graft; OM = obtuse marginal.

No preoperative angiogram was available for one patient, whose coronary catheterization was performed at another hospital.

Injection of contrast into the aortic root immediately after initiation of CPB and the application of the aortic occlusive clamp enabled identification of myocardial regions with or without flow (figs. 3 and 4). Injection of contrast directly into the saphenous vein provided useful information about the magnitude and geometric distribution of coronary artery-vein bypass run-off into the myocardium (figs. 5 and 6). Aortic root injections during reperfusion with warm blood at the completion of CABG

and before separation from CPB and release of the aortic occlusive clamp enabled the identification of myocardial regions without perfusion. These regions were associated with segmental wall motion abnormalities after separation from CPB (table 3). Two patients with localized perfusion defects after CABG surgery had corresponding abnormal wall motion in the region of the myocardium showing no perfusion. One patient showing no perfusion to the antero-septal region of myocardium before separation from CPB did not have wall motion abnormalities after separation from CPB. However, this patient had a left internal mammary artery to the left anterior descending artery

TABLE 3. Segmental Wall Motion Abnormalities after Separation from Cardiopulmonary Bypass as "Predicted" by Perfusion Pattern

Patient	Injection Pattern	Segmental Wall Motion Abnormalities
1	No deficit	No
2	No deficit	No
3	No deficit	No
4	No deficit	No
5	Anterolateral wall deficit	Lateral wall dyskinesis
6	No deficit	No
7	Posterior septal deficit	Septal akinesis
9	Anterior septal deficit	No*
14	No deficit	No
15	No deficit	No

Injection: into the aortic root after the CABG procedure. Segmental wall motion abnormalities: as observed from the short-axis view of the left ventricle.

\* Initial anterior hypokinesis, noted during controlled reperfusion, resolved after the internal mammary artery to left anterior descending bypass graft was perfused.

bypass, and so the perfusion deficit on injection of contrast into the aortic root did not reflect perfusion subtended by the internal mammary artery.

When predicted perfusion patterns were compared with actual perfusion patterns, predictions were accurate 84% of the time (27 of 32; 71–97%, 95% confidence interval) (table 2). There was no interobserver discordance among the reviewers of the angiograms, and therefore the results for the predicted perfusion patterns were pooled.

### Discussion

Conventional techniques to evaluate the adequacy of myocardial perfusion are of limited value because they provide only indirect evidence of the imbalance of myocardial oxygen supply and demand. The relationship of electrocardiographic and echocardiographic evidence of ischemia to an imbalance in hemodynamic indices of myocardial oxygen supply and demand indicates that a decrease in oxygen supply accounts for a significant percentage of myocardial ischemia during CABG surgery.<sup>13,14</sup> In the decade since its introduction, two-dimensional echocardiography has assumed a prominent role in the evaluation of cardiac ischemia and infarction.

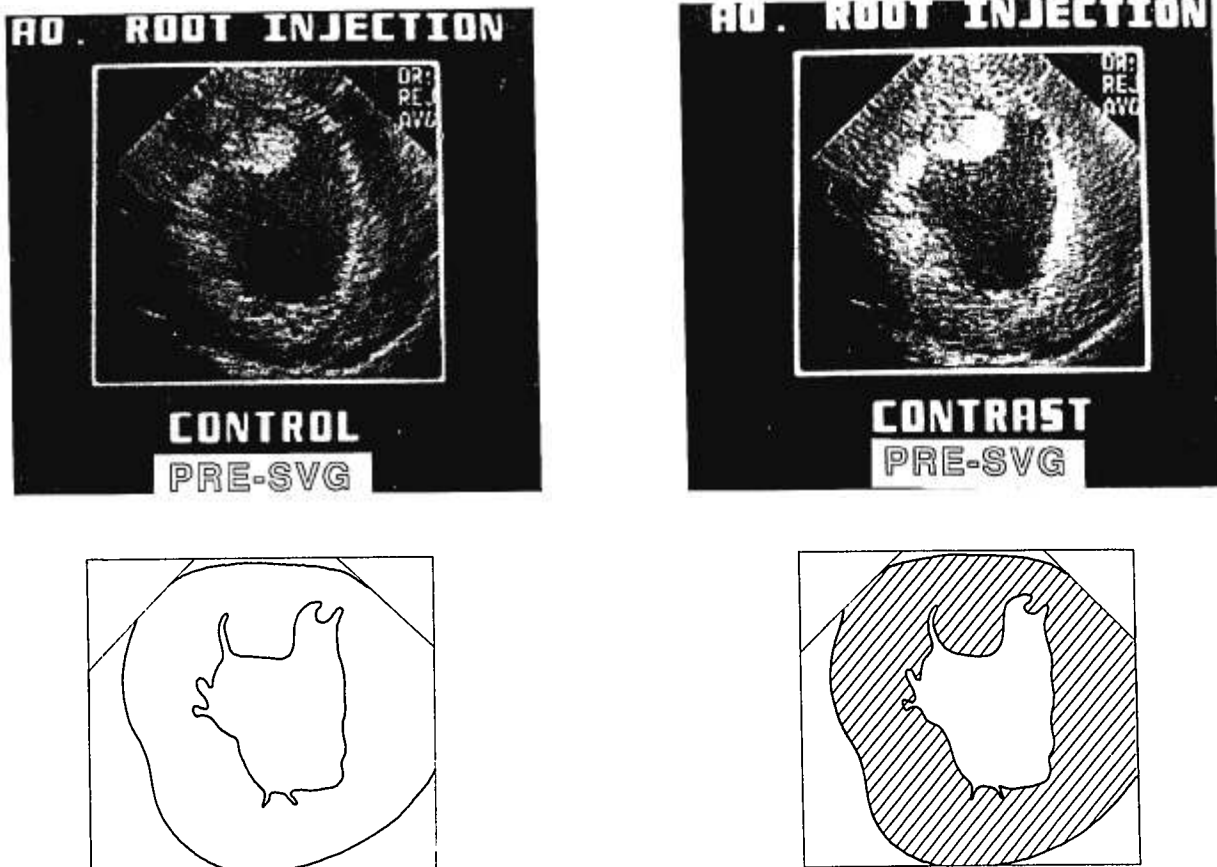


FIG. 3. Transesophageal contrast echocardiogram from a patient. Control (left) is a short-axis view of the left ventricle before injection of contrast prior to saphenous vein bypass grafting (SVG). Contrast (right) shows the same view when contrast is injected into the aortic root along with cardioplegia solution prior to coronary artery-vein bypass grafting. Shaded areas represent regional blood flow. AO = aortic.

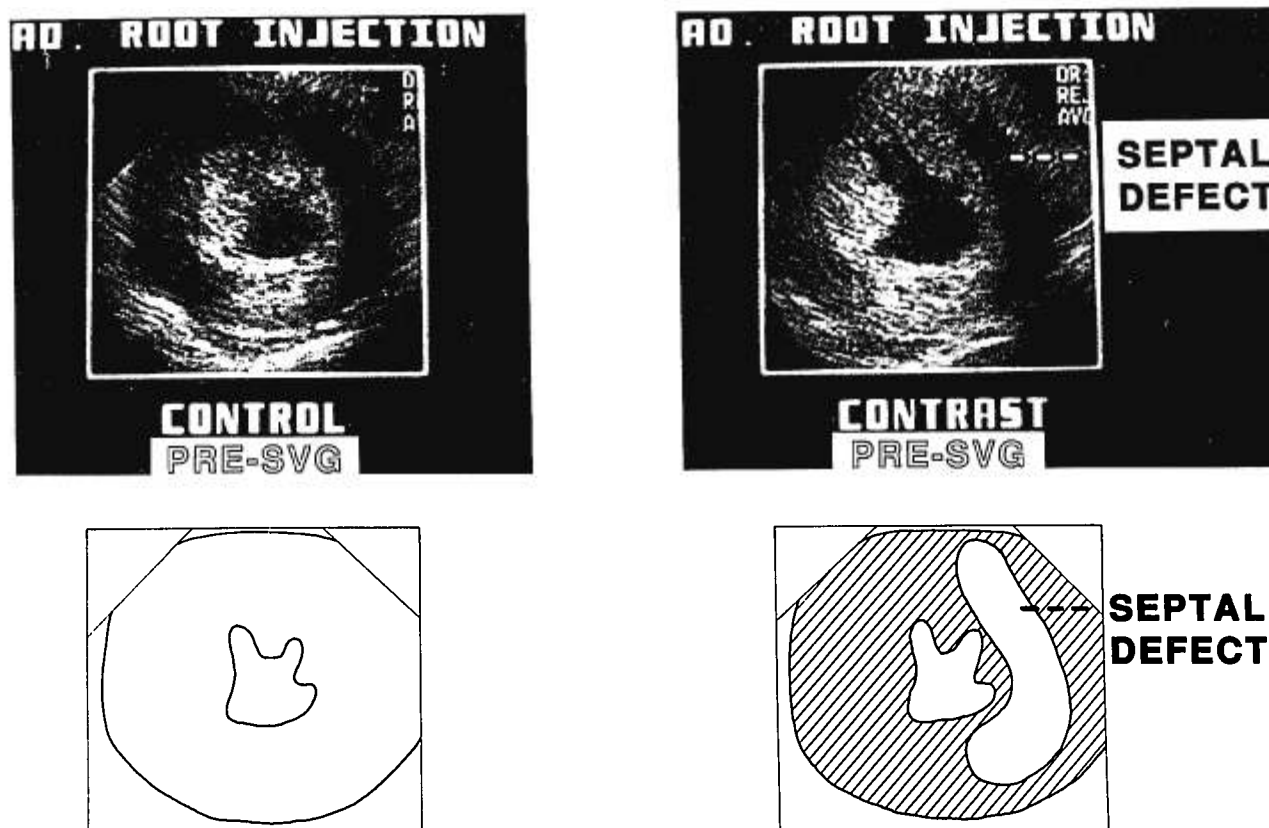


FIG. 4. Transesophageal echocardiogram images of the left ventricular short axis. Control (*left*) is an image prior to contrast injection. Contrast (*right*) is an image after contrast injection into the aortic root before CABG demonstrating a significant septal region filling defect. Shaded areas represent regional blood flow. AO = aortic; SVG = saphenous vein graft.

Regional wall motion analysis with two-dimensional transesophageal echocardiography, though a sensitive and early marker for the detection of perioperative cardiac ischemia,<sup>15</sup> is limited because it relies on the extent of dysfunctional myocardium as an index of underlying tissue ischemia. Functional analysis with two-dimensional echocardiography tends to overestimate the extent of nonviable myocardial tissue.<sup>2,16</sup> The disassociation between function and viability therefore limits the application of conventional two-dimensional echocardiography because regional myocardial blood flow cannot be assessed directly. Since its introduction in the early 1960s, coronary angiography has maintained a prominent place in the assessment of patients with coronary artery disease. Nevertheless, the visual anatomical perspective it offers may be inaccurate.<sup>17</sup> Indeed, visual interpretation of coronary arteriograms does not predict the physiologic importance of coronary stenosis<sup>18</sup> or patency.<sup>19</sup>

Contrast echocardiography is a means of accurately defining a region of inadequate myocardial perfusion without reliance on functional consequences for estimates. Initial attempts to image myocardial perfusion with contrast echocardiography were limited by contrast agents,

injection techniques, and methods of analyzing the ultrasound signal. The development of small, sonicated microbubble contrast agents has permitted the assessment of myocardial blood flow in patients undergoing cardiac catheterization, angioplasty, and thrombolytic revascularization procedures.<sup>20,21</sup> The process of sonication creates microbubbles (contrast agent) that are smaller than red blood cells and therefore are able to flow through blood vessels safely and without obstruction.<sup>22,23</sup> Sonicated microbubbles act as excellent reflectors of ultrasound waves and permit the mapping of regional patterns for myocardial blood flow.

We have introduced a technique for direct on-line visualization of changes in regional blood flow in the heart before, during, and after coronary bypass surgery with contrast echocardiography. Other investigators have used contrast ultrasound techniques to evaluate cardiac blood flow during CABG with hand-held ultrasound transducers and contrast agents injected directly into either the aortic root or a selected arteriovenous anastomosis.<sup>9</sup> Our method differed from these techniques in several ways.

First, to obtain our image, we used transesophageal echocardiography, which provides continuous imaging of

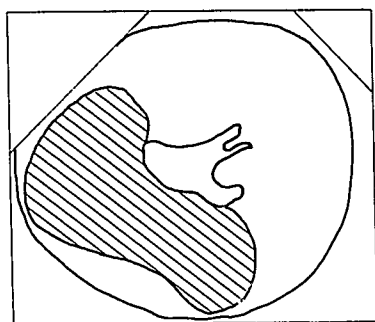
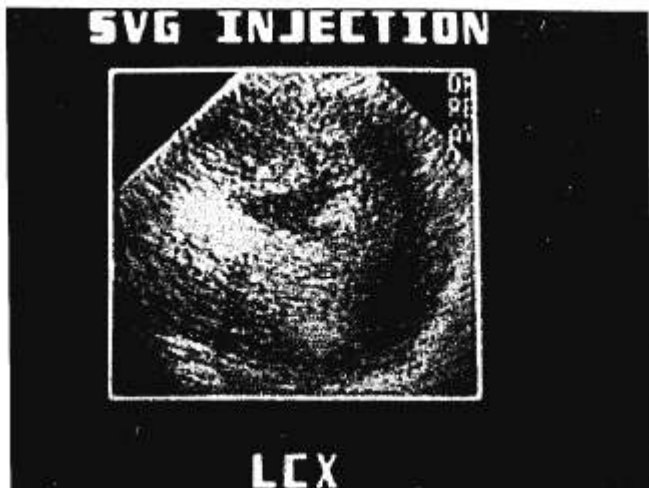


FIG. 5. Transesophageal contrast echocardiogram from a patient demonstrating myocardial perfusion during a contrast injection, directly into the proximal end of a left circumflex (LCX) saphenous vein bypass graft (SVG). Shaded areas represent regional blood flow.

the heart throughout the surgical procedure and does not require interruption of surgery, since no ultrasound probe is used.

Second, we injected contrast agent into the aortic root through the catheter routinely placed in the ascending aorta for administration of cardioplegia. Prebypass contrast injections for the identification of myocardial regions with little or no flow were thus possible. In addition, we selectively injected contrast into the proximal ends of saphenous veins after their distal ends had been anastomosed to coronary arteries. Direct saphenous vein injections provided useful information about the magnitude and geometric distribution of coronary artery-vein bypass run-off into the myocardium. Finally, before CPB was discontinued and after the proximal aortovenous anastomosis had been completed, we again injected contrast into the aortic root during reperfusion with warm blood through the cardioplegia line. These injections into the aorta during reperfusion allowed the identification of poorly perfused myocardial regions that were associated

with segmental wall motion abnormalities after separation from CPB. A significant limitation of our technique was the inability to assess myocardial perfusion subserved by the internal mammary artery bypass graft.

When predicted myocardial perfusion patterns (based on preoperative angiograms) and actual perfusion patterns (assessed by contrast echo) were compared off-line, the predicted perfusion pattern of regional myocardial blood flow occurred 84% of the time (71-97%, 95% confident interval). Our results are consistent with the findings of Feinstein *et al.*,<sup>20</sup> who confirmed that even though epicardial vessel distribution is associated with general myocardial perfusion patterns, perfusion patterns for a given patient may vary in a way that is specific to the individual. This finding indicates that operative results may be improved for 3-30% of vein-grafted vessel during CABG.

No reliable, quantifiable measure of tissue perfusion is currently available to assess the effectiveness of CABG surgery. Current techniques, such as coronary angiog-

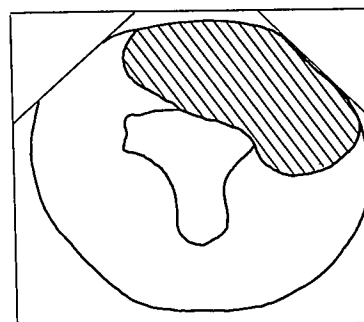
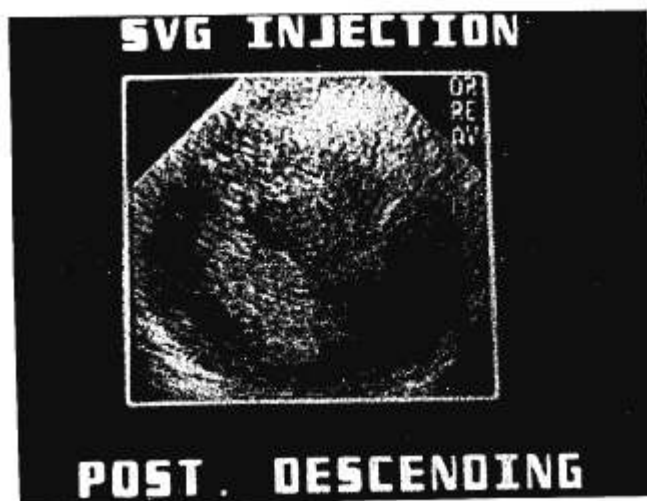

FIG. 6. Transesophageal contrast echocardiogram from a patient demonstrating myocardial perfusion during a contrast injection, directly into the proximal end of a posterior descending saphenous vein bypass graft (SVG). Shaded areas represent regional blood flow. POST = posterior.

raphy, define anatomy or structure, but do not provide measurements of distribution of blood flow. We used ultrasonic energy (sonication) in sterile Renografin-76 to generate gaseous microbubbles that were smaller than human red blood cells and flowed unimpeded through the microcapillary vasculature. After an injection of these microbubbles, we used transesophageal echocardiography to image the bubble-blood interface in the heart, which served as an ultrasound reflector. The "tracer" microbubbles, imaged by ultrasound, represented blood flow within the heart and allowed areas where perfusion was impaired or absent to be identified.

We believe that ultimately, critical clinical questions such as the amount of coronary reserve, the degree of collateralization, and the effects of interventional therapy may be answered by means of contrast echocardiography.

### References

- Häggmark S, Hohner P, Östman M, Friedman A, Diamond G, Lowenstein E, Reiz S: Comparison of hemodynamic, electrocardiopleptic, mechanical, and metabolic indicators of intraoperative myocardial ischemia in vascular surgical patients with coronary artery disease. *ANESTHESIOLOGY* 70:19-25, 1989
- Liberman AN, Weiss JL, Lugdutt BL, Becker LC, Bulkley BH, Garrison JG, Hutchins GM, Kallman CA, Weisfeldt ML: Two-dimensional echocardiography and infarct size: Relationship of regional wall motion and thickening to the extent of myocardial infarction in the dog. *Circulation* 63:739-746, 1981
- Kaul S, Glasheen W, Ruddy TD, Pandian NG, Weyman AE, Okada RD: The importance of defining left ventricular area at risk in vivo during acute myocardial infarction: an experimental evaluation with myocardial contrast two-dimensional echocardiography. *Circulation* 75:1249-1259, 1987
- Rose DM, Gelbfish J, Jacobowitz IJ, Kramer M, Zisbrod Z, Acinapura A, Cappabianca P, Cunningham JN, Jr: Analysis of morbidity and mortality in patients 70 years of age and over undergoing isolated coronary artery bypass surgery. *Am Heart J* 110:341-346, 1985
- Force T, Bloomfield P, O'Boyle JE, Khuri SF, Josa M, Parisi AF: Quantitative two-dimensional echocardiographic analysis of regional wall motion in patients with perioperative myocardial infarction. *Circulation* 70:233-241, 1984
- Burns RJ, Gladstone PJ, Tremblay PC, Feindel CM, Salter DR, Lipton IH, Ogilvie RR, David TE: Myocardial infarction determined by technetium-99m pyrophosphate single-photon tomography complicating elective coronary artery bypass grafting for angina pectoris. *Am J Cardiol* 63:1429-1434, 1989
- Goldman ME, Mindich BP: Intraoperative cardioplegic contrast echocardiography for assessing myocardial perfusion during open heart surgery. *J Am Coll Cardiol* 4:1029-1034, 1984
- Aronson S, Bender E, Feinstein SB, Heidenreich PA, Ellis JE, Dick C, Roizen MF, Karp RB: Contrast echocardiography: A method to visualize changes in regional myocardial perfusion in the dog model for CABG surgery. *ANESTHESIOLOGY* 72:295-301, 1990
- Kabas SJ, Kisslo J, Flick CL, Johnson SH, Craig DM, Stanley TE, Smith PK: Intraoperative perfusion contrast echocardiography: Initial experience during coronary artery bypass grafting. *J Thorac Cardiovasc Surg* 99:536-542, 1990
- Keller MW, Spotnitz WD, Matthew TL, Giasheen WP, Watson DD, Kaul S: Intraoperative assessment of regional myocardial perfusion using quantitative myocardial contrast echocardiography: An experimental evaluation. *J Am Coll Cardiol* 16:1267-1279, 1990
- Feinstein SB, Ten Cate FJ, Zwehl W, Ong K, Maurer G, Tei C, Shah PM, Meerbaum S, Corady E: Two-dimensional contrast echocardiography: In vitro development and quantitative analysis of echo contrast agents. *J Am Coll Cardiol* 3:6-13, 1984
- Feinstein SB, Keller MW, Kerber RE: Sonicated echocardiographic contrast agents: Reproducibility studies. *J Am Soc Echocardiogr* 2:125-131, 1989
- Slogoff S, Keats AS: Does perioperative myocardial ischemia lead to postoperative myocardial infarction? *ANESTHESIOLOGY* 62:107-114, 1985
- Leung JM, O'Kelly BF, Mangano DT: Relationship of regional wall motion abnormalities to hemodynamic indices of myocardial oxygen supply and demand in patients undergoing CABG surgery. *ANESTHESIOLOGY* 73:802-814, 1990
- Smith JS, Cahalan MK, Benefiel DJ, Byrd BJ, Lurz FW, Shapiro WA, Roizen MF, Bouchard A, Schiller NB: Intraoperative detection of myocardial ischemia in high risk patients: Electrocardiography versus two-dimensional transesophageal echocardiography. *Circulation* 72:1015-1021, 1985
- Force T, Kemper A, Perkins L, Gilfoil M, Cohen C, Parisi AF: Overestimation of infarct size by quantitative two-dimensional echocardiography: The role of tethering and of analytic procedures. *Circulation* 73:1360-1368, 1986
- Arnett EN, Isner JM, Redwood DR, Kent KM, Baker WP, Ackerman H, Roberts WC: Coronary artery narrowing in coronary heart disease: Comparison of cineangiographic and necropsy findings. *Ann Intern Med* 91:350-356, 1979
- White CW, Wright CB, Doty DB, Hiratza LF, Eastham CL, Harrison DG, Marcus ML: Does visual interpretation of the coronary angiogram predict the physiologic importance of a coronary stenosis? *N Engl J Med* 310:819-824, 1984
- Legrand V, Hodgson J, McB, Bates ER, Aueron FM, Mancini GBJ, Smith JS, Gross MD, Vogel RA: Abnormal coronary flow reserve and abnormal radionuclide exercise test results in patients with normal coronary angiograms. *J Am Coll Cardiol* 6:1245-1253, 1985
- Feinstein SB, Lang RM, Dick C, Neuman A, Al-Sadir J, Chua KG, Carrol J, Feldman T, Borow KM: Contrast echocardiography during coronary arteriography in humans: Perfusion and anatomical studies. *J Am Coll Cardiol* 11:59-65, 1988
- Griffin B, Timmis AD, Henderson RA, Souton E: Contrast perfusion echocardiography: Identification of area at risk of dyskinesia during percutaneous transluminal coronary angioplasty. *Am Heart J* 114:497-502, 1987
- Feinstein SB, Shah PM, Bing RJ, Meerbaum S, Corday E, Chang B-L, Santillan G, Fujibayashi Y: Microbubble dynamics visualized in the intact capillary circulation. *J Am Coll Cardiol* 4:595-600, 1984
- Keller MW, Segal SS, Duling B: The behavior of sonicated albumin microbubbles within the microvasculature: A basis for their use during myocardial contrast echocardiography. *Circ Res* 65:458-467, 1989