

A731

TITLE: INITIAL RESULTS WITH PROSTATIC BLOCK--A NEW ANESTHETIC TECHNIQUE FOR TRANSURETHRAL BALLOON DILATATION (TUBD)

AUTHORS: KG Belani, MBBS, MS, P K. Reddy, M.D.

AFFILIATION: Depts of Anesthesiology and Urology University of Minnesota Hospital and Clinic, Minneapolis, MN 55455

TUBD of the prostate to treat obstructive voiding symptoms has traditionally been done under general or spinal anesthesia. This report describes our initial experience with a newly described prostatic block which can easily be accomplished on an outpatient basis.

Fourteen patients (ASA Class III; HTN-6, COPD-8, prior MI-4) with benign prostatic hypertrophy, mean age 71 y (range 68-76 y), weight 85 kg (range 74-92 kg), underwent TUBD under prostatic block. None had a bleeding tendency and they all consented to the procedure under local block and monitored care. The block was done in the lithotomy position (Fig) using an aseptic technique. A 25 g needle was used to raise bilateral skin wheals (1% lidocaine) 1 cm anterior and lateral to the anal orifice. With the index finger of one hand in the rectum, a 5-inch long 22 g spinal needle (without a stylette but attached to a preloaded syringe with 1% lidocaine) was then advanced cephalad with the opposite hand through the skin wheal and guided along the lateral border of the prostate to the junction of the prostate with the seminal vesicle. 5 ml of 1% lidocaine was injected during passage of the needle and 10-15 ml was injected at the junction. The shaft of the advancing needle was easy to palpate with the index finger in the rectum. Striking the pubic ramus prevented the needle from being misdirected anteriorly or laterally. Aspiration prior to injection prevented intravascular injection. The same was repeated on the opposite side.

The first 2 patients were premedicated with intramuscular meperidine (50 mg) and hydroxyzine (25 mg). Diazepam 5 mg i.v. was given to the first 4 patients during the performance of the block. However, the remaining 10 patients did not require any parenteral sedatives or anxiolytics. All patients tolerated the procedure well and were comfortable during dilatation. There were no complications.

Conclusion: Prostatic block is a simple procedure to allow safe and easy TUBD of the prostate gland. We are currently investigating its use for prostatic biopsies.

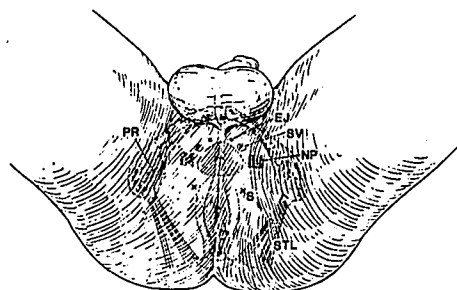


Figure: Perineal view illustrating landmarks for administration of local anesthetic to the prostate. E.A. = external anal sphincter, B.V.I. = bulbo-urethral vesicle, S.V. = seminal vesicle, P.P. = pubic ramus, B.T.L. = bulbourethral ligament.

A732

TITLE: MODIFIED BIER BLOCK ABOLISHES LOCAL PAIN ASSOCIATED WITH PROPOFOL INJECTION

AUTHORS: E. Holak, M.D., D. Mangar, M.D.

AFFILIATION: Department of Anesthesiology, University of South Florida College of Medicine, Tampa, FL 33612

Propofol, a 2,6-di-isopropylphenol, is a new intravenous hypnotic with many characteristics of an ideal anesthetic agent. The most notable side effect of propofol is pain on injection, with an incidence of 58%. Use of lidocaine treatment has been proposed to decrease injection related pain, but its effectiveness is unclear. We evaluated the efficacy of lidocaine, with and without a tourniquet, on decreasing the intensity of pain during propofol injection.

After Institutional Review Board approval, fifty-three consenting ASA class I or II patients scheduled to undergo general anesthesia were randomly assigned to one of four groups. Patients in group A (n=11) received propofol 2 mg/kg IV; those in group B (n=16) were given 1% lidocaine 100 mg IV followed by propofol 2 mg/kg one minute later. Patients in group C (n=12) and D (n=14) had an arm tourniquet (Modified Bier Block) applied after gravity drainage of venous blood, followed by injection of a saline placebo (group C) or 1% lidocaine 100 mg (group D). The tourniquet was released one minute later, before injecting propofol 2 mg/kg IV.

Premedication was omitted. An electrolyte solution (Plasmalyte®) was administered at a rate of 125 ml/hr via an 18-gauge angiocatheter inserted into a vein in the dorsum of the hand. All medications were delivered through the injection port nearest the catheter. Patients were asked to rate the intensity of pain along the forearm during propofol administration using a 0 to 100 mm visual analog scale (VAS). Statistical analysis of the data was performed with the Kruskal-Wallis tests.

No significant difference in sex, age, or ASA classification existed among the groups. Pain intensity was significantly lower in patients who received lidocaine prior to propofol (group B; 66 ± 35 mm) than in the control group (group A; 22 ± 20 mm; $p < 0.01$). Pain intensity was significantly lower in patients receiving lidocaine with a tourniquet (group D; 1 ± 2 mm) compared with those receiving lidocaine without a tourniquet (group B; 22 ± 20 mm; $p < 0.001$). Use of the tourniquet with placebo did not decrease the pain significantly.

We conclude that intravenous lidocaine administration prior to propofol injection attenuates the painful response; whereas, lidocaine administered with a modified Bier block technique virtually abolished the transient local pain associated with propofol injection. This simple, cost-efficient technique eliminates an unpleasant side effect, allows for painless induction, and likely increases patients' acceptance of this induction agent.