

**A1111**

**Title:** Tracheal Intubation After Propofol Anesthesia Without a Neuromuscular Blocker Is Not Practical

**Authors:** SP Kothary MBBS, SK Pandit MD, M Lebenbom-Mansour DO, L Levy MD, GI Randel MD

**Affiliation:** University of Michigan School of Medicine, Ann Arbor, MI 48109-0048

**Introduction:** The newly introduced intravenous anesthetic propofol has several useful properties including rapid induction of anesthesia and rapid recovery. It has been suggested that propofol might have an inherent muscle relaxing property as well<sup>1</sup>. One group of investigators<sup>2</sup> recently reported excellent conditions for tracheal intubation following an induction dose of propofol without any neuromuscular blocker. In the present study, we have recorded tracheal intubating conditions in adults after high and low induction doses of propofol, as well as after thiomyal induction.

**Methods:** The institutional ethical committee approved the study and each patient gave written informed consent. Thirty adults (age 18 - 65 yrs), ASA physical status 1 or 2, scheduled for a lower abdominal operation participated in this randomized study. After premedication with midazolam 0.2 mg I.V., anesthesia was induced with either thiomyal (5 mg/kg), high dose propofol (2.5 or 3 mg/kg) or low dose propofol (1.5 or 2.0 mg/kg). Thirty seconds after the loss of eye lash reflex, one of the three designated investigators (all staff anesthesiologists) attempted tracheal intubation. The following were noted and numerical grades were given for each: relaxation of the lower jaw, visualization and patency of the vocal cords, intubation possible or impossible without a neuromuscular blocker and post intubation responses (only in cases where intubation was possible without succinylcholine).

**Results:** Demographic variables like age, weight, and height were comparable in the three groups (ANOVA). The results of the intubating conditions are shown in Table 1. More patients in the high dose propofol group had excellent relaxation of the lower jaw and good visualization of the vocal cords compared to the other two groups. However, only three patients out of thirty (two induced with high dose propofol and one with the low dose) could be intubated without succinylcholine. Furthermore, post intubation responses consisting of coughing and bucking were severe in each of these three patients.

**Conclusions:** We conclude that tracheal intubation after a reasonable induction dose of propofol (without a neuromuscular blocker) in healthy adults is impractical and is no better than an equivalent dose of thiomyal.

**References:**

1. McKeating K, Bali IM, Dundee JW: The effects of thiopentone and propofol on upper airway integrity. *Anaesthesia*, 43:638-640, 1988
2. Kallar SK: Propofol allows intubation without muscle relaxants. *Anesthesiology*, 73:A 21, 1990

Table 1  
Assessment of Intubating Conditions

	Thiomyal N = 10	Propofol High Dose N = 10	Propofol Low Dose N = 10
<b>Relaxation of Lower Jaw</b>			
Excellent	2	6	1
Average	6	4	6
Poor	2	0	3
<b>Visualization of Vocal Cords</b>			
Excellent	1	4	1
Average	4	4	2
Poor	5	2	7
<b>Intubation Possible (Without a Neuromuscular Blocker)</b>	0	2	1

**A1112**

**TITLE:** COMPARISON OF LARYNGEAL MASK WITH ENDOTRACHEAL TUBE FOR AIRWAY CONTROL

**AUTHORS:** RC Cork, MD, PhD, B Kaul MS, BS, MD, FFARCSI, EJ Frink, Jr, MD, JR Standen, MD, R Depa

**AFFILIATION:** Departments of Anesthesiology and Radiology, University of Arizona, Tucson, AZ, 85724

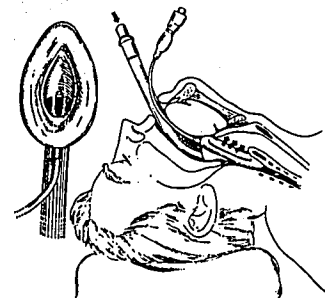
**Introduction:** The laryngeal mask (LM)<sup>1</sup> (Figure 1) has become a valuable adjunct for airway control in Britain and Canada, but has yet to be approved for general use in the United States. We compared the LM with the endotracheal tube (ETT) in terms of hemodynamics, respiratory variables, and protection of the trachea, in patients scheduled for outpatient orthopedic procedures.

**Methods:** After approval by the Human Subjects Committee, 10 ASA PS-I outpatient orthopedic patients were randomized to the LM Group or ETT Group. No preoperative medication was given. Anesthesia was induced with propofol 2.5 mg/kg. One minute after administration of succinylcholine 1.5mg/kg, patients received either an LM or an ETT for airway control. Anesthesia was maintained with N<sub>2</sub>O 67% and isoflurane 1-2%. Cuff pressure for the ETT was maintained at 25 cm H<sub>2</sub>O, and pop-off pressure for the LM was measured. After skin incision, those patients with the LM were given a fiberoptic examination to verify placement of the LM. After this, 15 ml of 10% barium sulfate was poured into the patients oropharynx. At the end of the procedure, the fiberoptic exam was repeated, and an AP x-ray of the upper chest and neck was done. In two patients a lateral x-ray of the neck was done. Patients were interviewed on discharge from the recovery room regarding incidence of sore throat. Data were analyzed with Student's-t test and Chi-square analysis, with p<0.05.

**Results:** Airway time was 110±21 min for the LM Group and 139±37 min for the ETT Group. Barium time was 70±17 min and 103±31 min, respectively. No barium was seen in the trachea or lungs on x-ray in either group. Neither Hemodynamic response to airway placement, nor airway removal at the end of the case was different between groups. Fiberoptic examination revealed the epiglottis to be appropriately positioned between the bars of the LM in all cases. No change in LM position occurred in any case and pop-off pressures ranged from 20 to 28 cm H<sub>2</sub>O. Aldrete Scores were not different between groups on admission to the recovery room, and incidence of sore throat was the same. Patients in the ETT Group requested more Demerol in the recovery room than did patients in the LM Group (24±7 mg vs 9±4 mg) (p<0.05).

**Conclusions:** For outpatient orthopedic procedures, no problems with the LM were encountered. Placement of the LM is technically easier, because no laryngoscopy is required. The trachea and lungs were protected from barium in the oropharynx, but these results are no guarantee of protection from aspiration of stomach contents. The laryngeal mask provides an additional technique to the anesthesiologist for control of the patient's airway during anesthesia.

Figure 1



**References:** <sup>1</sup>Br J Anaesth 55:801, 1983