

tube is difficult. In contrast, the laryngeal mask can be used regardless of the location of the stenotic segment.

The laryngeal mask is not able to prevent air leakage at high inflation pressure and also is not designed as an esophageal blocker. Air can therefore be introduced into the stomach with positive pressure ventilation. However, because the laryngeal mask does not occlude the mouth and nose, and instead partially obstructs the esophagus, gastric distention is less likely to occur than when a face mask is used for ventilation.

Bronchospasm appeared during anesthesia in our case, and was relieved by increasing depth of anesthesia, demonstrating the laryngeal mask should be used in a deep plane of anesthesia. Brain recommends that the laryngeal mask should not be removed during a light plane of anesthesia, since this may worsen the situation by increasing the stimulus.⁹

One of the disadvantages of the laryngeal mask is air leakage. Air leakage usually occurs at airway pressure greater than about 20 cmH₂O. Although successful airway management at peak pressure of 60 cmH₂O with pressure on the thyroid cartilage has been reported, the efficacy of the laryngeal mask at high airway pressure has not been confirmed; therefore, we consider that tracheal intubation is currently a better choice in patients who require high inflation pressure. If in our case the airway problem during the induction of anesthesia or the bronchospasm during the surgery had worsened despite deepening of the anesthesia, we would have intubated the patient's trachea.

Patients with mechanically obstructed trachea, such as tracheomalacia or external compression of the trachea, cannot be managed with a laryngeal mask, because the laryngeal mask cannot prevent collapse of the trachea.

In summary, we used the laryngeal mask in a child with congenital tracheal stenosis. We believe that the laryngeal mask is a useful alternative to endotracheal intubation in this population.

REFERENCES

1. Brain AIJ: The laryngeal mask: A new concept in airway management. *Br J Anaesth* 55:801-805, 1983
2. Brodrick PM, Webster NR, Nunn JF: The laryngeal mask airway: A study of 100 patients during spontaneous breathing. *Anaesthesia* 44:238-241, 1989
3. Brain AIJ: Three cases of difficult intubation overcome by the laryngeal mask airway. *Anaesthesia* 40:353-355, 1985
4. Beveridge ME: Laryngeal mask anaesthesia for repair of cleft palate. *Anaesthesia* 44:656-657, 1989
5. Smith BL: Brain airway in anaesthesia for patients with juvenile chronic arthritis. *Anaesthesia* 43: 421-422, 1988
6. Rowbottom SJ, Sudhaman DA: Anaesthesia in the management of congenital tracheal stenosis. *Anaesth Intensive Care* 17:93-96, 1989
7. Benca JF, Hickey PR, Dornbusch JN, Koka BV, McGill TJ, Jonas R: Ventilatory management assisted by cardiopulmonary bypass for distal tracheal reconstruction in a neonate. *ANESTHESIOLOGY* 68:270-271, 1988
8. Gal TJ, Suratt PM: Resistance to breathing in healthy subjects following endotracheal intubation under topical anesthesia. *Anesth Analg* 59:270-274, 1980
9. Brain AIJ: Studies on the laryngeal mask: First, learn the art. *Anaesthesia* 46:417-418, 1991

Anesthesiology
75:904-907, 1991

Protamine-induced Right-to-left Intracardiac Shunting

ALBERT T. CHEUNG, M.D.,* STUART J. WEISS, M.D., PH.D.,* JOSEPH S. SAVINO, M.D.†

Right-to-left intracardiac shunting through a patent foramen ovale (PFO) is not usually observed in the resting

state, but certain physiologic conditions during anesthesia that increase right atrial pressure and/or decrease left atrial pressure may increase interatrial shunting.¹⁻⁶ This report describes a case of acute right-to-left interatrial shunting provoked by protamine-induced pulmonary vasoconstriction in a patient with a PFO.

* Lecturer in Anesthesia.

† Assistant Professor in Anesthesia.

Received from the University of Pennsylvania, Department of Anesthesia, Division of Cardiothoracic Anesthesia, Intraoperative Echocardiography Service, Philadelphia, Pennsylvania. Accepted for publication June 27, 1991.

Address reprint requests to Dr. Cheung: University of Pennsylvania, Department of Anesthesia, 3400 Spruce Street, Philadelphia, Pennsylvania 19104-4283.

Key words: Blood, coagulation: protamine. Complications: embolism. Heart: atrial septal defect. Lungs, circulation: hypertension. Monitoring: transesophageal echocardiography.

CASE REPORT

A 64-yr-old 80-kg man was admitted for elective coronary revascularization and closure of a perimembranous ventricular septal defect (VSD). His past history included a recent non-Q-wave myocardial infarction, pneumonia, and mild glucose intolerance.

A preoperative transthoracic echocardiogram showed a perimembranous VSD with left-to-right shunting, increased pulmonary artery

pressures, and normal left ventricular function. The VSD was verified by cardiac catheterization. Systemic cardiac output was determined to be $3.8 \text{ l} \cdot \text{min}^{-1}$ using the Fick oxygen method. The calculated pulmonary to systemic blood flow ratio was 2.9. Hemodynamic measurements demonstrated a mean right atrial pressure of 5, right ventricular pressure of 66/5, pulmonary artery pressure of 66/29, pulmonary artery occlusion pressure of 8, left ventricular pressure of 125/8, and aortic pressure of 125/60 mmHg. The pulmonary vascular resistance was 6 Woods units. There was neither history of drug or food allergies nor symptoms of angina or congestive heart failure on a medical regimen of diltiazem, isosorbide dinitrate, and glyburide.

Preoperative sedation was achieved with lorazepam 1 mg orally, morphine sulfate 8 mg intramuscularly, and scopolamine 0.4 mg intramuscularly. Monitoring included radial artery and oximetric pulmonary artery catheters. General anesthesia was induced with midazolam 3 mg intravenously and morphine sulfate 80 mg intravenously, and the trachea was intubated after the administration of vecuronium bromide. A 5.0-MHz transesophageal ultrasound transducer (Hewlett Packard, Andover, MA) was passed into the esophagus for intraoperative localization of the VSD. Intraoperative echocardiography was also used for evaluating whether residual shunts were present after the surgical repair, assessing the effectiveness of deairing procedures, and monitoring ventricular function.

The pre-cardiopulmonary bypass echocardiography study was notable for a VSD in the membranous septum, a PFO with minimal right-to-left shunting during ventricular systole, and mild hypertrophy of the right ventricle. The pulmonary artery pressure was 72/30 mmHg and the systemic blood pressure 110/70 mmHg.

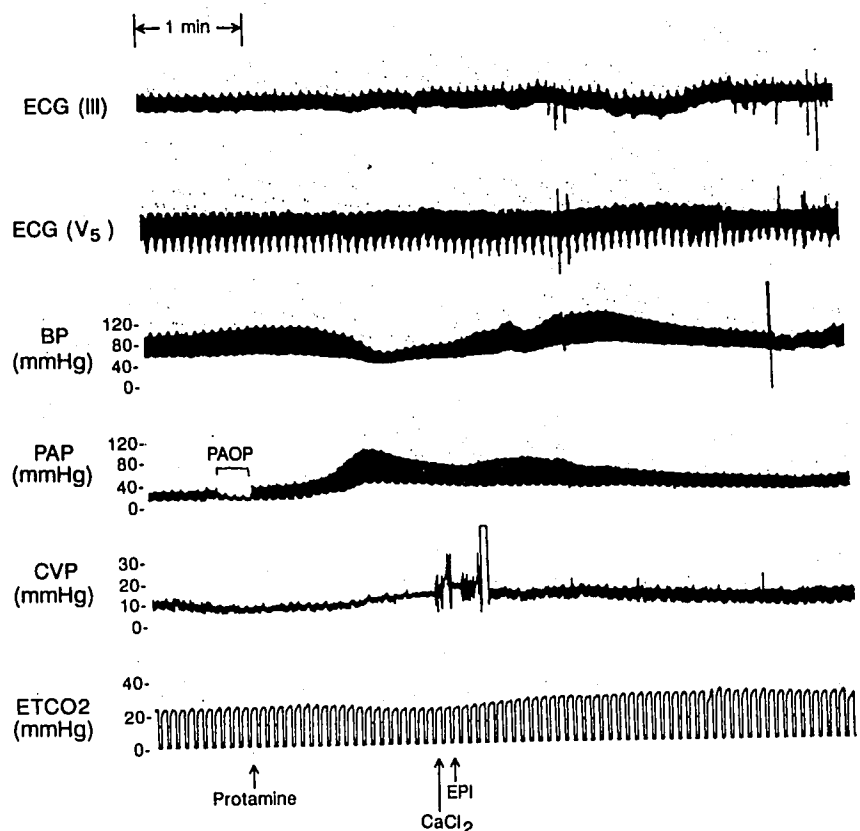
After administering heparin $300 \text{ U} \cdot \text{kg}^{-1}$ intravenously and initiating cardiopulmonary bypass, the congenital membranous VSD was located and closed with a Dacron patch, and aortocoronary bypass with reversed

saphenous vein grafts was performed to the left anterior, first diagonal, and first obtuse marginal coronary arteries. Separation from cardiopulmonary bypass proceeded uneventfully with atrioventricular sequential cardiac pacing, the administration of calcium chloride 1 g intravenously, and nitroglycerin $33 \mu\text{g} \cdot \text{min}^{-1}$ intravenous infusion. The patient had a radial artery pressure of 100/60, pulmonary artery pressure of 28/17, mean right atrial pressure of 9, pulmonary artery occlusion pressure of 12 mmHg, mixed venous oxygen saturation of 73%, and cardiac output of $3.9 \text{ l} \cdot \text{min}^{-1}$. The post-cardiopulmonary bypass transesophageal echocardiographic examination showed no residual transeptal flow, normal left ventricular wall motion, and no air in the left atrium, left atrial appendage, or left ventricle.

A 50-mg intravenous test dose of protamine sulfate was administered slowly. The remaining 200 mg protamine was administered gradually as an intravenous infusion. Immediately after the protamine infusion was completed, systemic hypotension, which had been preceded by an initial rapid increase in the pulmonary artery and then central venous pressures (fig. 1), occurred. A transient decrease in the end-tidal carbon dioxide tension and the mixed venous oxygen saturation was also observed during this period.

The patient was treated with calcium chloride 500 mg and epinephrine $16 \mu\text{g}$ injected into the right atrial port of the pulmonary artery catheter. A continuous intravenous infusion of epinephrine at a rate of $4 \mu\text{g} \cdot \text{min}^{-1}$ was started simultaneously. Transesophageal echocardiography demonstrated a severe reduction in left ventricular systolic and diastolic dimensions in combination with the sudden appearance of echocardiographic contrast (presumed to be microbubbles) within all cardiac chambers (fig. 2). Right ventricular distension was observed both directly and by echocardiography. Global left ventricular function and wall motion was normal. Restoration of cardiovascular function was rapid and the epinephrine infusion was gradually discon-

FIG. 1. Hemodynamic profile during the administration of protamine for reversal of heparin anticoagulation. The acute increase in pulmonary artery pressure (PAP) precedes the decrease in radial artery pressure (BP). The increase in right atrial pressure (CVP) occurs gradually with the onset of right ventricular pressure overload. Note also the decrease in the end-tidal carbon dioxide partial pressure (ET_{CO_2}) corresponding to the reduction in cardiac output, which subsequently rebounds after recovery of cardiovascular function. The appearance of echocardiographic contrast within the cardiac chambers occurred immediately after injection of calcium chloride (CaCl_2) 500 mg intravenously and epinephrine (EPI) $16 \mu\text{g}$ intravenously. ECG = electrocardiogram; PAOP = pulmonary artery occlusion pressure; Protamine = start of protamine sulfate 250 mg intravenous infusion.



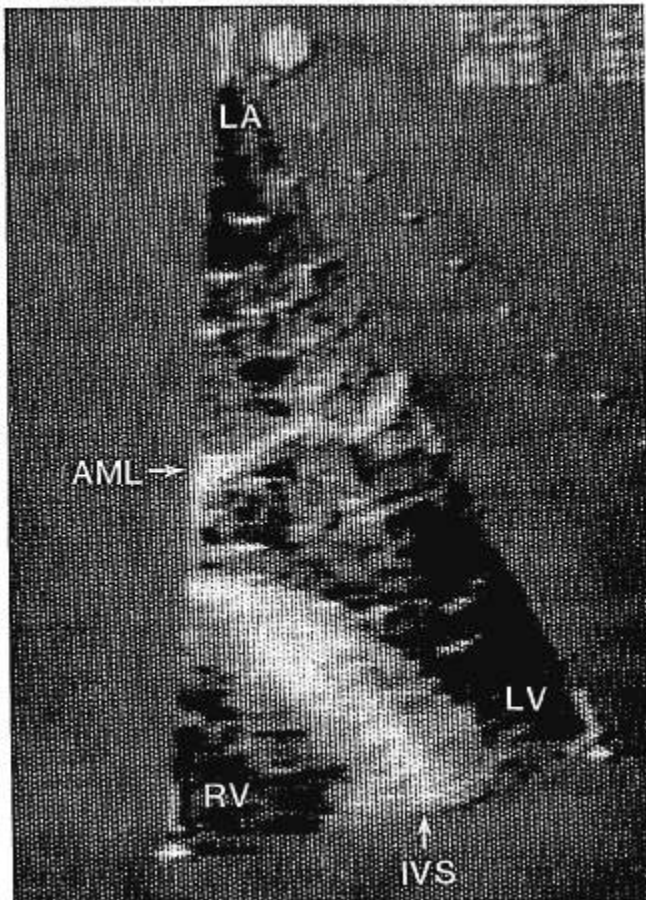


FIG. 2. Right-to-left interatrial shunting after protamine administration. Long-axis four-chamber view at end diastole showing echocardiographic contrast in the left atrium and ventricle diagnostic of right-to-left interatrial shunting. The contrast agent is presumed to be microbubbles created during rapid injection of medication into the right atrial port of the pulmonary artery catheter and appears as specular echoes within the cardiac chambers. No intracardiac microbubbles were visualized during the initial period after separation from cardiopulmonary bypass. LA = left atrium; RV = right ventricle; LV = left ventricle; AML = anterior mitral valve leaflet.

tinued. The patient recovered uneventfully from his anesthesia and operation without neurologic sequelae.

DISCUSSION

The incidence of PFO in the general population is approximately 27%.⁷ Provocative testing using transesophageal echocardiography detected a PFO in 26% of patients undergoing elective cardiovascular surgery.¹ The incidence of cerebral or myocardial injury caused by paradoxical air or particulate emboli in anesthetized patients with PFO is unknown. Identifying patients with PFO and recognizing the conditions that promote right-to-left intracardiac shunting in these patients may improve the ability to predict which patients are at risk for paradoxical emboli.^{5,8} Early therapeutic intervention (*e.g.*, careful re-

moval of air from intravenous lines, use of bubble traps, and avoidance of PEEP) may decrease the chance of paradoxical emboli in high-risk patients.

This report describes a case of protamine-induced pulmonary hypertension causing acute right-to-left intracardiac shunting through a PFO. The primary event was severe pulmonary artery vasoconstriction leading to right ventricular pressure overload and an increase in right atrial pressure. Impedance of blood flow across the pulmonary vascular bed as a consequence of pulmonary vasoconstriction decreased pulmonary venous return to the left atrium and caused a reversal of the normal interatrial pressure gradient. Although left atrial pressure was not directly measured, the acute increase in central venous pressure to 14 mmHg, the increase in pulmonary artery pressure to greater than the radial artery pressure, and the observation of right ventricular dilation in combination with a decrease in left ventricular cavity size suggest that the right atrial pressure exceeded the left atrial pressure during the protamine-induced reaction. This reversal of the interatrial pressure gradient acutely caused right-to-left interatrial shunting.

Intracardiac shunting was demonstrated by intraoperative transesophageal echocardiography. Echocardiographic contrast produced by the rapid injection of fluid into the heart created multiple acoustic interfaces that were readily imaged. The immediate appearance of echocardiographic contrast in both atria and ventricles of the heart during the rapid injection of medication into the right atrial port of the pulmonary artery catheter was diagnostic of intracardiac shunting (fig. 2). The acute appearance of echocardiographic contrast could not be explained on the basis of residual air in the left atrium, left ventricle, and pulmonary veins following the open chamber cardiac operation because sufficient time had elapsed after the discontinuation of cardiopulmonary bypass for any residual air to be eliminated.

The life-threatening reaction to protamine in a patient with a PFO is an uncommon event, but it demonstrates the physiologic mechanisms involved in the pathogenesis of acute intracardiac shunting. Clinical conditions that reverse the normal interatrial pressure gradient can cause intracardiac shunting through a PFO. Examples include the Valsalva maneuver, coughing, primary lung disease, hypoxic pulmonary vasoconstriction, pulmonary emboli, pulmonic valve stenosis, tricuspid valve regurgitation, and right ventricular ischemia or infarction leading to an acute increase in right atrial pressure.^{2-4,9} Patients undergoing pneumonectomy, heart transplantation, or lung transplantation often have pulmonary hypertension with increased pulmonary vascular resistance and also are at increased risk for paradoxical emboli during anesthesia.

Intraoperative transesophageal echocardiography has proven to be a sensitive monitor for intracardiac air and can be used for the detection of PFO.^{1,8} Experience at

our institution suggests that positioning the tip of the transducer to produce a long-axis two-dimensional image enveloping the interatrial septum and the mitral valve orifice optimizes the chances of detecting interatrial shunting in echocontrast studies.

In summary, transesophageal echocardiography was used to demonstrate acute paradoxical right-to-left intracardiac shunting through a PFO during a life-threatening adverse reaction to protamine. The transesophageal echocardiographic findings during the acute phase of a pulmonary vasoconstrictive response to protamine in a human demonstrate an acute decrease in left ventricular preload. This case report suggests that the risk of paradoxical emboli is increased in pathologic conditions associated with an increased right-to-left interatrial pressure gradient in patients with PFO. Intraoperative echocardiography is providing insight into the pathophysiology of clinical problems encountered during anesthesia.

REFERENCES

1. Konstadt SN, Louie EK, Black S, Rao TLK, Scanlon P: Intraoperative detection of patent foramen ovale by transesophageal echocardiography. *ANESTHESIOLOGY* 74:212-216, 1991
2. Borow K, Braunwald E: Congenital heart disease in the adult, *Heart Disease: A Textbook of Cardiovascular Medicine*. Edited by Braunwald E. Philadelphia, WB Saunders, 1988, p 985
3. Feigenbaum H: *Echocardiography*. Philadelphia, Lea and Febiger, 1986, p 408
4. Lynch JJ, Schuchard GH, Gross CM, Wann LS: Prevalence of right-to-left atrial shunting in the healthy population: Detection by Valsalva maneuver contrast echocardiography. *Am J Cardiol* 53:1478-1480, 1984
5. Black S, Muzzi DA, Nishimura RA, Cucciara RF: Preoperative and intraoperative echocardiography to detect right-to-left shunt in patients undergoing neurosurgical procedures in the sitting position. *ANESTHESIOLOGY* 72:436-438, 1988
6. Moorthy SS, Haselby KA, Caldwell RL, West KW, Albrecht T, France LW, Powell JC: Transient right-to-left interatrial shunt during emergence from anesthesia: Demonstration by color flow mapping. *Anesth Analg* 68:820-822, 1989
7. Hagen PT, Scholtz DG, Edwards WD: Incidence and size of patent foramen ovale during the first ten decades of life: An autopsy study of 965 normal hearts. *Mayo Clin Proc* 59:17-20, 1984
8. Pearson AC, Labovitz AJ, Tatineni S, Gomez CR: Superiority of transesophageal echocardiography in detecting cardiac source of embolism in patients with cerebral ischemia of uncertain etiology. *J Am Coll Cardiol* 17:66-72, 1991
9. Dubourg O, Bourdarias JP, Farcot JC, Gueret P, Terdjman M, Ferrer A, Rigaud M, Barcelet JC: Contrast echocardiographic visualization of cough-induced right to left shunt through a patent foramen ovale. *J Am Coll Cardiol* 4:587-594, 1984

Anesthesiology
75:907-911, 1991

Management of Peripartum Congestive Heart Failure Using Continuous Arteriovenous Hemofiltration in a Patient with Myotonic Dystrophy

T. M. DODDS,* M. F. HANEY,† F. M. APPLETON‡

Cardiac decompensation can occur during pregnancy in patients with cardiac dysfunction because of cardiovascular changes that stress cardiac reserve, including increases in total blood volume (35-40%) and cardiac output (30-40%), both of which peak early in the third trimester.^{1,2} Further increases in venous return and cardiac output occur during labor and in the postpartum period.³

Cardiomyopathy is a well-recognized component of the

multisystem disease seen in myotonic dystrophy. Overt congestive heart failure (CHF) related to myotonic dystrophy is rare, but diffuse, often subclinical, myocardial involvement is common. We report here the case of a woman in the third trimester of pregnancy with CHF from myotonic dystrophy-related cardiomyopathy. We describe the use of continuous arteriovenous hemofiltration (CAVH) for the treatment of refractory CHF in preparation for operative delivery.

CASE REPORT

During the 1st month of her pregnancy, this 25-yr-old gravida 1, para 0 woman underwent an electromyographic study that was diagnostic of myotonic dystrophy. This workup was prompted by the recent diagnosis of a sister with myotonic dystrophy. Her pregnancy was uneventful until presentation at the 30th week with rapidly progressive orthopnea, shortness of breath, and dyspnea on exertion. Evaluation at that time was significant for an ECG with sinus tachycardia, first-degree atrioventricular block, and loss of R wave; an echocardiogram revealing moderate mitral regurgitation and severe global hypokinesis,

* Assistant Professor of Anesthesiology.

† Instructor in Anesthesiology.

‡ Associate Professor of Medicine.

Received from the Dartmouth-Hitchcock Medical Center, 2 Maynard Street, Hanover, New Hampshire. Accepted for publication July 3, 1991.

Address reprint requests to Dr. Dodds: Department of Anesthesiology, Dartmouth-Hitchcock Medical Center, 2 Maynard Street, Hanover, New Hampshire 03756.

Key words: Anesthesia, obstetric: congestive heart failure. Muscle: myotonic dystrophy. Renal: continuous arteriovenous hemofiltration.