

our institution suggests that positioning the tip of the transducer to produce a long-axis two-dimensional image enveloping the interatrial septum and the mitral valve orifice optimizes the chances of detecting interatrial shunting in echocontrast studies.

In summary, transesophageal echocardiography was used to demonstrate acute paradoxical right-to-left intracardiac shunting through a PFO during a life-threatening adverse reaction to protamine. The transesophageal echocardiographic findings during the acute phase of a pulmonary vasoconstrictive response to protamine in a human demonstrate an acute decrease in left ventricular preload. This case report suggests that the risk of paradoxical emboli is increased in pathologic conditions associated with an increased right-to-left interatrial pressure gradient in patients with PFO. Intraoperative echocardiography is providing insight into the pathophysiology of clinical problems encountered during anesthesia.

REFERENCES

1. Konstadt SN, Louie EK, Black S, Rao TLK, Scanlon P: Intraoperative detection of patent foramen ovale by transesophageal echocardiography. *ANESTHESIOLOGY* 74:212-216, 1991
2. Borow K, Braunwald E: Congenital heart disease in the adult, *Heart Disease: A Textbook of Cardiovascular Medicine*. Edited by Braunwald E. Philadelphia, WB Saunders, 1988, p 985
3. Feigenbaum H: *Echocardiography*. Philadelphia, Lea and Febiger, 1986, p 408
4. Lynch JJ, Schuchard GH, Gross CM, Wann LS: Prevalence of right-to-left atrial shunting in the healthy population: Detection by Valsalva maneuver contrast echocardiography. *Am J Cardiol* 53:1478-1480, 1984
5. Black S, Muzzi DA, Nishimura RA, Cucciara RF: Preoperative and intraoperative echocardiography to detect right-to-left shunt in patients undergoing neurosurgical procedures in the sitting position. *ANESTHESIOLOGY* 72:436-438, 1988
6. Moorthy SS, Haselby KA, Caldwell RL, West KW, Albrecht T, France LW, Powell JC: Transient right-to-left interatrial shunt during emergence from anesthesia: Demonstration by color flow mapping. *Anesth Analg* 68:820-822, 1989
7. Hagen PT, Scholtz DG, Edwards WD: Incidence and size of patent foramen ovale during the first ten decades of life: An autopsy study of 965 normal hearts. *Mayo Clin Proc* 59:17-20, 1984
8. Pearson AC, Labovitz AJ, Tatineni S, Gomez CR: Superiority of transesophageal echocardiography in detecting cardiac source of embolism in patients with cerebral ischemia of uncertain etiology. *J Am Coll Cardiol* 17:66-72, 1991
9. Dubourg O, Bourdarias JP, Farcot JC, Gueret P, Terdjman M, Ferrier A, Rigaud M, Barcelet JC: Contrast echocardiographic visualization of cough-induced right to left shunt through a patent foramen ovale. *J Am Coll Cardiol* 4:587-594, 1984

Anesthesiology
75:907-911, 1991

Management of Peripartum Congestive Heart Failure Using Continuous Arteriovenous Hemofiltration in a Patient with Myotonic Dystrophy

T. M. DODDS,* M. F. HANEY,† F. M. APPLETON‡

Cardiac decompensation can occur during pregnancy in patients with cardiac dysfunction because of cardiovascular changes that stress cardiac reserve, including increases in total blood volume (35-40%) and cardiac output (30-40%), both of which peak early in the third trimester.^{1,2} Further increases in venous return and cardiac output occur during labor and in the postpartum period.³

Cardiomyopathy is a well-recognized component of the

multisystem disease seen in myotonic dystrophy. Overt congestive heart failure (CHF) related to myotonic dystrophy is rare, but diffuse, often subclinical, myocardial involvement is common. We report here the case of a woman in the third trimester of pregnancy with CHF from myotonic dystrophy-related cardiomyopathy. We describe the use of continuous arteriovenous hemofiltration (CAVH) for the treatment of refractory CHF in preparation for operative delivery.

* Assistant Professor of Anesthesiology.

† Instructor in Anesthesiology.

‡ Associate Professor of Medicine.

Received from the Dartmouth-Hitchcock Medical Center, 2 Maynard Street, Hanover, New Hampshire. Accepted for publication July 3, 1991.

Address reprint requests to Dr. Dodds: Department of Anesthesiology, Dartmouth-Hitchcock Medical Center, 2 Maynard Street, Hanover, New Hampshire 03756.

Key words: Anesthesia, obstetric: congestive heart failure. Muscle: myotonic dystrophy. Renal: continuous arteriovenous hemofiltration.

CASE REPORT

During the 1st month of her pregnancy, this 25-yr-old gravida 1, para 0 woman underwent an electromyographic study that was diagnostic of myotonic dystrophy. This workup was prompted by the recent diagnosis of a sister with myotonic dystrophy. Her pregnancy was uneventful until presentation at the 30th week with rapidly progressive orthopnea, shortness of breath, and dyspnea on exertion. Evaluation at that time was significant for an ECG with sinus tachycardia, first-degree atrioventricular block, and loss of R wave; an echocardiogram revealing moderate mitral regurgitation and severe global hypokinesis,

with estimated ejection fraction of 20%; and an endomyocardial biopsy consistent with myotonic dystrophy (fibrotic change without inflammation). Uterine ultrasound examination showed a normal-appearing fetus at 30 weeks gestation in a breech presentation. The patient improved symptomatically after treatment with furosemide and digoxin, and she was discharged home on the 9th hospital day.

The patient was readmitted at 33 weeks gestation with an exacerbation of CHF and the complaint of decreased fetal movement. Deteriorating renal function was noted, with a creatinine clearance of 40 ml/min. Evaluation of the fetus included a nonstress test that showed adequate fetal activity and heart rate accelerations, and an ultrasound examination that showed normal growth and persistent breech presentation. Over the ensuing 3 days the patient experienced modest symptomatic improvement with bed rest and intravenous furosemide. Dexamethasone was given to hasten fetal lung maturation, and amniocentesis for determination of the lecithin/sphingomyelin ratio was scheduled. Prior to obtaining the amniocentesis, the patient's clinical condition deteriorated further, necessitating admission to the cardiac intensive care unit (CCU).

In the CCU the patient became increasingly dyspneic, tachypneic, and tachycardiac (range 116–130 beats per min). While breathing 50% oxygen *via* face mask her arterial blood gases were pH 7.46, arterial carbon dioxide tension 31 mmHg, and arterial oxygen tension 75 mmHg. An oximetric pulmonary artery catheter was inserted demonstrating hemodynamic parameters listed in table 1. The first 6 h in the CCU were characterized by pharmacologic attempts at improving the patient's CHF. Urine output was scant (< 20 ml/h) despite the increases in the doses of intravenous furosemide (100, 160, and 160 mg). Concomitantly, dobutamine was administered (up to 8.0 $\mu\text{g} \cdot \text{kg}^{-1} \cdot \text{min}^{-1}$) with improvement in cardiac index, but oliguria persisted and filling pressures remained high (table 1). With the patient tiring and exhibiting worsening respiratory distress, it was decided that her deterioration necessitated a cesarean section. It was hoped that her condition would improve with removal of the cardiovascular stressor imposed by the fetus and placenta. Anesthesia consultation was obtained for consideration of an urgent cesarean section. Faced with a patient in florid pulmonary edema who required an upright posture, we believed that her perioperative cardiac risk could be reduced and positioning for operative delivery facilitated if preload reduction could be achieved. We therefore delayed the cesarean section to institute CAVH. The dobutamine infusion was continued during this procedure.

An Amicon Diafilter 20 (Amicon Co, Danvers, MA) was used for ultrafiltration. Vascular access was obtained *via* 10-Fr femoral arterial and venous catheters. Heparin 600 units/h was infused into the proximal side of the filtration circuit (fig. 1). This maintained the activated clotting time at 1.5 times the baseline value proximal to the filter.

Concomitant systemic coagulation parameters were prothrombin time 13.1 s and partial thromboplastin time 54. s. After 5 h a net negative fluid balance of 1,500 ml had been achieved, and the patient was improved symptomatically: she was no longer dyspneic at rest and was able to lie supine with left uterine displacement. Cardiac filling pressures and mixed venous oxygen saturation improved in parallel with symptoms. Cardiac index decreased 18% but remained significantly greater than values obtained on arrival to the CCU (table 1). The fetal heart rate was continuously monitored, and it remained in the normal range with good variability. Systemic coagulation parameters returned to normal within 1 h of cessation of CAVH.

Six hours after hemofiltration had been initiated and after normal coagulation parameters had been documented, the patient was transported to the operating room. Maternal monitoring intraoperatively included an ECG, pulse oximeter, and radial arterial and pulmonary arterial catheter pressures. With the patient in the sitting position, a lumbar epidural catheter was placed with the loss-of-resistance technique. After a 3-ml test dose additional increments of lidocaine 2% with epinephrine 5 $\mu\text{g}/\text{ml}$ were administered to a total of 20 ml. Sensory blockade to T4 on the right and T8 on the left was noted within 20 min. Concomitant hemodynamic parameters are provided in table 1. An epinephrine infusion was instituted with the onset of the epidural block because of a decrease in systolic blood pressure to 90 mmHg.

For the balance of the surgical procedure, epinephrine (as much as 2 $\mu\text{g}/\text{min}$) was titrated to maintain an acceptable cardiac index and mean arterial pressure. Dobutamine was discontinued. The cesarean section proceeded uneventfully, with delivery of a viable infant with Apgar scores of 9 and 10 at 1 and 5 min, respectively. Umbilical-cord venous blood gases were pH 7.33, carbon dioxide tension 47 mmHg, and oxygen tension 30 mmHg. The uterus did not contract spontaneously despite massage and parenteral oxytocin (Pitocin, Parke Davis). Prompt contraction occurred with 10 units of intrauterine Pitocin. Crystalloid infusion was used to replace blood loss, which was estimated at 800 ml. The only hemodynamic perturbations noted during the blood loss was a decrease in mixed venous oxygen saturation (from 72 to 68%) and systolic blood pressure (from 110 to 95 mmHg). Total fluid infused for the operative procedure was 1,800 ml of crystalloid.

An epidural infusion of bupivacaine 0.125% (1.25 mg/ml) with fentanyl 3 $\mu\text{g}/\text{ml}$ was maintained for 36 h postoperatively to provide for analgesia and afterload reduction. Despite this, the patient had an exacerbation of CHF while in the CCU immediately postoperatively (table 1). Her condition steadily improved after she received CAVH for an additional 24 h (the catheters remained *in situ* intraoperatively), and she was discharged from the CCU on the fourth postoperative day.

On the ninth postoperative day the patient was discharged from the hospital. She was able to walk without symptoms on a medical regimen that included digoxin, furosemide, and captopril. Two months after

TABLE 1. Serial Hemodynamic Parameters

	Initial Data	Dobutamine +Furosemide	S/P CAVH	Epidural Onset	Epinephrine Infusion	Postpartum
HR (beats per min)	136	135	129	115	115	122
MAP (mmHg)	99	97	68	61	65	96
CVP (mmHg)	9	11	0	NR	11	10
MPAP (mmHg)	40	39	16	16	19	35
PCWP (mmHg)	32	35	8	10	NR	30
SvO ₂ (%)	44	64	68	72	70	52
CI (l · min ⁻¹ · m ⁻²)	1.8	2.8	2.3	2.8	2.7	2.2
SVR (dynes · s ⁻¹ · cm ⁻⁵)	2000	1180	1200	NR	710	1560

Measurements obtained in supine position while in the operating room (epidural onset and with addition of epinephrine). Remaining data obtained in semi-upright posture.

HR = heart rate; MAP = mean arterial pressure; CVP = central

venous pressure; MPAP = mean pulmonary arterial pressure; PCWP = pulmonary capillary wedge pressure; SvO₂ = mixed venous oxygen saturation; CI = cardiac index; SVR = systemic vascular resistance; NR = not recorded.

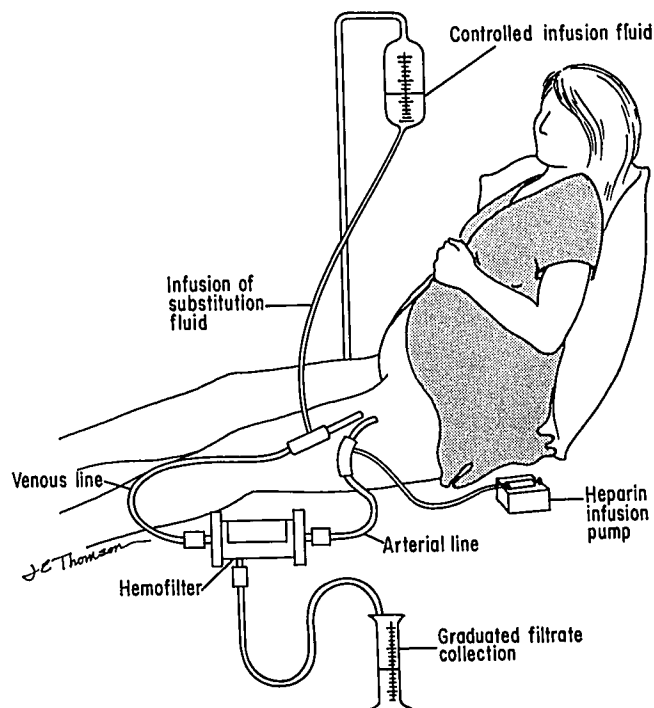


FIG. 1. CAVH components.

hospital discharge the patient suffered an out-of-hospital cardiac arrest from which she could not be resuscitated.

DISCUSSION

This case demonstrates the successful use of CAVH in the urgent treatment of an obstetric patient with severe diuretic-resistant CHF. The peripartum use of CAVH has not, to our knowledge, been previously described.

Traditional management of CHF, including bed rest, salt and fluid restriction, diuretics, and digoxin was ineffective in this patient. Dobutamine, through its positive impact on inotropy and/or afterload reduction, improved the cardiac index, although filling pressures remained high, oliguria persisted, and the patient continued to deteriorate symptomatically. Because of the potential negative impact of α -adrenergic stimulation on both utero-placental and renal perfusion, the cardiology team avoided the use of other sympathomimetic agents.⁴

When we were consulted for consideration of cesarean section, we recommended surgery be delayed, for two reasons. The first reason was the substantial risk of perioperative cardiac morbidity and mortality in a person with overt CHF. This contrasts to the lesser degree of risk in patients with compensated heart failure.⁵ We hoped to reduce this patient's cardiac risk by improving her hemodynamic status. The second reason for delay was that we favored, for reasons discussed below, epidural anesthesia and were concerned that the patient would be un-

able to tolerate a position that would facilitate surgical delivery while awake. CAVH was instituted because it is an effective and expeditious means of correcting hypervolemia in oliguric patients.⁶⁻⁸

Other management options that were considered included intravenous nitroglycerin, immediate surgery under epidural anesthesia, and phlebotomy. Although nitroglycerin would have likely been an effective temporizing measure—decreasing preload by redistributing blood volume—we believed this grossly hypervolemic patient would ultimately require treatment directed at reducing total body fluid overload. A factor in this decision was the potential for hemodynamic deterioration immediately postpartum. Despite the usual blood loss associated with vaginal delivery, venous return, central venous pressure, and cardiac output increase to peak levels immediately postpartum.³ Similarly, we rejected the option of immediate surgery under epidural anesthesia, despite the potentially favorable impact of afterload reduction (from epidural anesthesia) and blood loss, because we believed that if the CHF was better compensated at the time of surgery the risk of cardiopulmonary complications would be less. The option of phlebotomy also was rejected, because with an initial hemoglobin of 10 mg/dl, conservation of red cell mass was a priority in this patient with limited cardiopulmonary reserve. Preoperative phlebotomy would likely have been well tolerated, and perhaps beneficial, but would have been ill-advised given the potential for excessive postpartum blood loss in patients with myotonic dystrophy.^{9,10}

CAVH has recently been documented as an effective and well-tolerated treatment for the temporary control of severe diuretic and vasodilator resistant CHF.^{6,7} In contrast to hemodialysis, it does not require specially trained personnel, is simple and more readily instituted, and is less likely to cause significant hemodynamic perturbations. CAVH is quite efficient in the rapid removal of plasma ultrafiltrate but limited in its ability to correct azotemia or profound electrolyte abnormalities.⁸

Operational characteristics of CAVH are described elsewhere.^{8,11} In brief, CAVH is an extracorporeal therapy relying on the patient's arterial-to-venous pressure gradient to provide flow through the ultrafilter. The ultrafiltrate consists of plasma water, electrolytes, and other solutes of molecular weight less than 10,000 D. The rate of fluid removal (ultrafiltration rate) can be controlled by

§ Paganini EP, O'Hara P, Nakamoto S: Slow continuous ultrafiltration in hemodialysis resistant oliguric acute renal failure patients. *Transactions of the American Society for Artificial Internal Organs* 30:173-178, 1984

¶ Bosch JP: Continuous arteriovenous hemofiltration (CAVH): operational characteristics and clinical use. *American Kidney Foundation Nephrology Letter* 3:15-26, 1986

altering the transmembrane hydrostatic pressure. This is accomplished by raising or lowering the ultrafiltrate reservoir (fig. 1). The net negative fluid balance is ultimately determined by the ultrafiltration rate (usually 12–15 l/day) relative to the rate at which crystalloids and colloids are simultaneously reinfused. With large net negative fluid balances, some degree of hemoconcentration occurs because of the net loss of plasma volume with an unchanged red cell mass.

Potential complications of short term CAVH include intravascular volume depletion, electrolyte disturbances, bleeding, and problems associated with obtaining vascular access. Hypovolemia with resultant decreased cardiac index and hypotension was of particular concern in this patient because of the need to maintain adequate uteroplacental perfusion. Though we are unaware of data examining the impact of CAVH on uteroplacental perfusion, several reports^{6,7} demonstrate that cardiac index and mean arterial pressure are well maintained if excessively rapid fluid removal is avoided. In two series, patients with severe, diuretic-resistant, CHF had 2,000–3,000 ml fluid removed over 4–6 h with no change in cardiac index or mean arterial pressure despite decreased filling pressures.^{6,7} In our patient, mean arterial pressure and cardiac index decreased by 30 and 18%, respectively (table 1). We postulate that the decrease in cardiac index was secondary to rapid fluid removal in this patient with severe left ventricular dysfunction and a dependence on a high preload. Despite the decrease in cardiac index and mean arterial pressure, there was no evidence of uteroplacental insufficiency from either the fetal heart rate tracing or subsequent umbilical cord gases.

In addition to excessive volume loss, electrolyte depletion can occur. This is avoided by measuring serum electrolytes and adjusting the electrolyte composition of the substitution fluid infusion. Bleeding complications secondary to the anticoagulant required to prevent clotting within the filter were a concern in this patient not only because she was peripartum but because of the apparent association of myotonic dystrophy with postpartum bleeding.^{9,10} By administering the minimum requisite dose of heparin, we believed the risk of bleeding would be acceptably low. This was accomplished by infusing heparin into the circuit proximal to the filter to maintain an activated clotting time at 1.5 times the baseline value immediately proximal to the filter. In this case, 600 units/h heparin was required, resulting in some degree of systemic anticoagulation. Systemic anticoagulation can be avoided altogether by infusing protamine into the circuit distal to the filter and titrating it to return the activated clotting time to baseline (*i.e.*, regional heparinization). Finally, the usual complications associated with establishing vascular access must be considered. Of particular concern with CAVH are the large catheters required with the po-

tential for ischemic injury to the distal extremity. In our experience, this complication has been limited to elderly patients with concomitant peripheral vascular disease.

Detailed discussion of the perioperative management of patients with myotonic dystrophy is discussed in a recent review by Aldridge.¹¹ Muscle weakness and myotonia are the hallmarks of the disease. Involvement of pharyngeal, diaphragmatic, and intercostal musculature contribute to a high incidence (20%) of postoperative pulmonary complications. Although cardiomyopathy with overt CHF is rare, cardiac involvement—usually conduction abnormalities and arrhythmias—is common. There is substantial anecdotal evidence that some patients with myotonic dystrophy are particularly sensitive to thiopental, opioids, and perhaps other CNS depressants, with the potential for prolonged apnea and respiratory depression. The use of muscle relaxants is complicated by an unpredictable response to succinylcholine and anticholinesterase (reversal) agents. It has been advised that succinylcholine be avoided because of reports of rigidity and of difficulty in ventilation associated with its use. Similarly, reversal of nondepolarizing neuromuscular blocking drugs with neostigmine has been complicated by inadequate reversal, necessitating repeated administration as well as exacerbation of weakness postulated to be a depolarization blockade. Although the muscle relaxation achieved in this case was adequate, it should be noted that the myotonia manifest in these patients is not abolished by muscle relaxants or spinal blockade. Additional concerns in the pregnant patient with myotonic dystrophy include an apparent association with postpartum uterine atony and hemorrhage.^{9,10} Intrauterine Pitocin was ultimately required to achieve uterine contraction in this patient. Inheritance and the potential for congenital myotonic dystrophy has been reviewed elsewhere.¹²

We favored epidural anesthesia in this patient for a number of reasons. First, favorable hemodynamic impact of a sympathectomy with preload and afterload reduction was anticipated. Second, using an epidural infusion postoperatively allowed us to maintain a sympathectomy as well as to provide for postoperative analgesia. The beneficial impact of epidural analgesia on postoperative pulmonary function^{13,14} was critical in this patient with minimal cardiopulmonary reserve. Finally, regional anesthesia and analgesia allowed us to circumvent the potential problems associated with the use of muscle relaxants and central nervous system depressants, discussed above.

In summary, we present a case in which CAVH was used to prepare a pregnant patient with refractory CHF for cesarean section. The patient's symptoms and hemodynamic parameters improved during CAVH without apparent deleterious effect on the mother or the fetus. With the use of continuous fetal monitoring "low-dose" heparinization and careful attention to the rate of fluid

and electrolyte removal, we were able to use CAVH safely in the peripartum period.

REFERENCES

1. Pritchard JA: Changes in the blood volume during pregnancy and delivery. *ANESTHESIOLOGY* 26:393-399, 1965
2. Ueland K, Novy MJ, Peterson EN, Metcalfe J: Maternal cardiovascular dynamics: IV. The influence of gestational age on the maternal cardiovascular response to posture and exercise. *Am J Obstet Gynecol* 104:856-864, 1969
3. Ueland K, Hansen JM: Maternal cardiovascular dynamics: III. Labor and delivery under local and caudal analgesia. *Am J Obstet Gynecol* 103:8-18, 1969
4. Ralston DH, Shnider SM, deLorimier AA: Effects of equipotent ephedrine, metaraminol, mephentermine, and methoxamine on uterine blood flow in the pregnant ewe. *ANESTHESIOLOGY* 40:354-370, 1974
5. Goldman L: Cardiac risks and complications of noncardiac surgery. *Ann Intern Med* 98:504-513, 1983
6. Fauchald P, Forfang K, Amlie J: An evaluation of ultrafiltration as treatment of therapy-resistant cardiac edema. *Acta Med Scand* 219:47-52, 1986
7. Rimondini A, Cipolla CM, Bella PD, Grazi S, Sisillo E, Susini G, Guazzi MD: Hemofiltration as short-term treatment for refractory congestive heart failure. *Am J Med* 83:43-48, 1987
8. Golper TA: Continuous arteriovenous hemofiltration in acute renal failure. *Am J Kidney Dis* 6:373-386, 1985
9. Hook R, Anderson EF, Noto P: Anesthetic management of a parturient with myotonia atrophica. *ANESTHESIOLOGY* 43:689-692, 1975
10. Cope DK, Miller JN: Local and spinal anesthesia for cesarean section in a patient with myotonic dystrophy. *Anesth Analg* 65:687-690, 1986
11. Aldridge LM: Anaesthetic problems in myotonic dystrophy. *Br J Anaesth* 57:1119-1130, 1985
12. Glanz A, Fraser FC: Risk estimates for neonatal myotonic dystrophy. *J Med Genet* 21:186-188, 1984
13. Cuschieri RJ, Morran CG, Howie C, McArdle CS: Postoperative pain and pulmonary complications: Comparison of three analgesic regimens. *Br J Surg* 72:495-498, 1985
14. Rawal N, Sjöstrand U, Christoffersson E, Dahlström B, Arvill A, Rydman H: Comparison of intramuscular and epidural morphine for postoperative analgesia in the grossly obese: Influence on postoperative ambulation and pulmonary function. *Anesth Analg* 63:583-592, 1984