

tispastic effects and thereby obscuring any cross-tolerance effects between baclofen and fentanyl. A formal dose-response study with and without baclofen coadministration would be required to differentiate between these possible explanations.

Regardless of the mechanism, the ability of intrathecal fentanyl to reduce spasticity in this patient with tolerance to intrathecal baclofen may have important clinical implications. The majority of patients with implanted intrathecal infusion devices have demonstrated resistance to conventional oral medications for controlling their spasticity. Furthermore, they usually develop tolerance to intrathecal baclofen. In this patient, the favorable response to intrathecally infused opioid despite the development of tolerance to baclofen has proven very useful. The opioid treatment has provided satisfactory relaxation without the need for baclofen for at least 3 months. It appears that intrathecal opioid therapy may be a viable alternative therapy to provide a respite from baclofen. Prior to the commencement of intrathecal opioid therapy, baclofen should be discontinued gradually to prevent withdrawal symptoms. After a respite from baclofen the opioid could be discontinued and the baclofen resumed at a lower dose. A prolonged treatment plan could routinely involve rotation of intrathecal baclofen and opioid when clinical tolerance becomes apparent. The rate of reoccurrence of tolerance to baclofen following a respite and the effect of chronic prior exposure of baclofen on the development of tolerance to intrathecal opioids are not known.

In conclusion, this case report describes a patient with severe spasticity who developed tolerance to intrathecal baclofen but who retained the ability to respond with relaxation to intrathecal fentanyl. This may have important clinical implications for the prolonged management of spasticity in patients with implanted intrathecal infusion devices.

REFERENCES

1. Hudgson P, Weightman D: Baclofen in the treatment of spasticity. *B M J* 4:15-18, 1971
2. Pierson GA, Fowlks EW, King PS: Long-term follow-up in the use of diazepam in the treatment of spasticity. *Am J Phys Med Rehabil* 47:143-149, 1968
3. Penn RD, Savoy SM, Corcos D, Lathash M, Gottlieb G, Parke B, Kroin JS: Intrathecal baclofen for severe spinal spasticity. *N Engl J Med* 320:1517-1521, 1989
4. Erickson DL, Blacklock B, Michaelson M, Sperling KB, Lo JN: Control of spasticity by implantable continuous morphine pump. *Neurosurgery* 16:215-217, 1985
5. Penn RD, Kroin JS: Long-term intrathecal baclofen infusion for the treatment of spasticity. *J Neurosurg* 66:181-185, 1987
6. Erickson DL, Moreno P, Lo J, Cameron J, Michaelson M: Control of spasticity with intrathecal morphine sulfate. *Local Spinal Therapy of Spasticity*. Edited by Muller H, Zierski J, Penn RD. New York, Springer-Verlag, 1988 pp 137-142
7. Chabal C, Schwid HA, Jacobson L: The dynamic flexometer: An instrument for the objective evaluation of spasticity. *ANESTHESIOLOGY* 74:609-612, 1991
8. Muller-Schwweefe G, Penn RD: Physostigmine in the treatment of intrathecal baclofen overdose. *J Neurosurg* 71:273-275, 1989
9. Chabal C, Jacobson L, Schwid HA: An objective comparison of intrathecal lidocaine versus fentanyl for the treatment of lower extremity spasticity. *ANESTHESIOLOGY* 74:643-646, 1991

Anesthesiology
76:314-316, 1992

Incidental Discography during Celiac Plexus Block

PETER R. WILSON, M.B., B.S., PH.D., F.F.A. R.A.C.S.*

Celiac plexus blockade with local anesthetic or neurolytic agents is widely used as a diagnostic and therapeutic maneuver for patients with upper abdominal pain and upper abdominal carcinoma. Numerous techniques of celiac blockade have been described, including the classical two-needle posterior approach,^{1,2} a modified posterior ap-

proach,³ a posterior transaortic method,⁴ and an anterior approach.⁵ Some of these methods require needle contact with the vertebral body as an indicator of position, whereas others require radiologic control with fluoroscopy or computed tomography scan. All techniques should require a functional test dose of local anesthetic before a neurolytic agent is injected.⁶

Because these needles must traverse many structures in reaching the celiac plexus, numerous complications, including postural hypotension, chest pain, failure of ejaculation, urinary difficulty, pneumothorax, neurologic damage, pleural effusion, paraplegia, and aortic pseudoaneurysm have been reported.⁷⁻¹² These present case re-

* Associate Professor of Anesthesiology, Mayo Clinic and Foundation.

Received from the Mayo Clinic and Foundation, Rochester, Minnesota. Accepted for publication October 14, 1991.

Address reprint requests to Dr. Wilson: Department of Anesthesiology, Mayo Clinic and Foundation, Rochester, Minnesota, 55905.

Key words: Anesthetic technique: celiac plexus block. Complications.

ports illustrate a previously unreported needle misplacement with potentially disastrous consequences if not recognized.

CASE REPORTS

Case 1. Celiac plexus block using the modified posterior approach³ was being performed for relief of the pain of inoperable carcinoma of the pancreas. The left needle was placed with local anesthetic infiltration along the needle track, with correct placement being verified by fluoroscopy. The right needle was inserted to a similar depth without fluoroscopic control, and on initial screening it was shown to be in the L1-L2 intervertebral disc (fig. 1). The patient did not report any local or radiating pain during the placement of this needle when specifically asked. There was not any unusual resistance to the passage of the needle. The needle was immediately withdrawn from the disc and redirected to the correct position. The celiac block was completed in the usual fashion. There were no immediate or late adverse effects of the disc penetration or of the celiac block.

Case 2. Celiac plexus block was performed for pain relief in a patient with inoperable carcinoma of the pancreas using the modified posterior approach. Both needles appeared to be in the correct position on the anteroposterior fluoroscopic view. One half milliliter of contrast medium (diatrizoate, Hypaque 60) was injected through both needles without significant resistance. Screening at this stage showed the dye injected through the right needle spreading in the correct periaortic plane. However, the dye injected through the left needle was seen to enter the L1-L2 annulus and spread throughout the intervertebral disc. The anteroposterior image (fig. 2) was stored, and lateral fluoroscopy indicated that the contrast entered a disrupted, degenerated disc and passed out of the disc space into the epidural space within the vertebral column. Unfortunately, a hard copy was not made of the lateral view, but the dye was clearly visualized in the lateral view. The needle was therefore withdrawn and redirected to the correct position. The celiac block was completed as planned. Again, there were no ad-

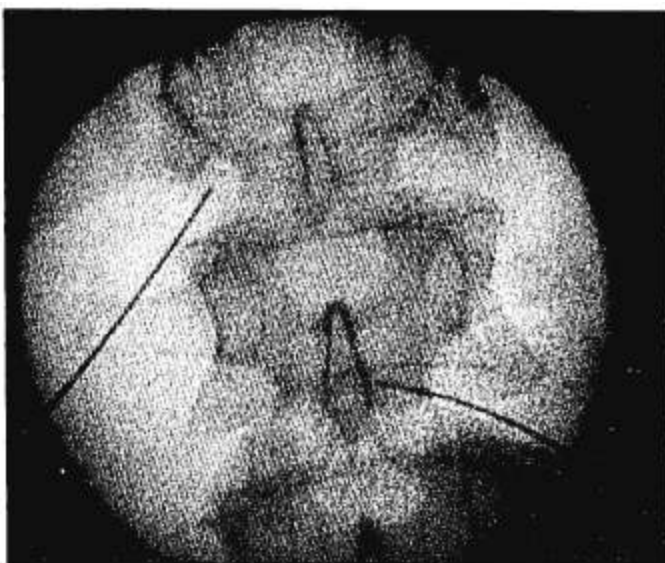


FIG. 1. Fluoroscopy screen indicating needle placement for celiac block. The needle at left in the photograph (on the right of the patient) is placed correctly. The needle at right in the photograph has entered the L1-L2 intervertebral disc.

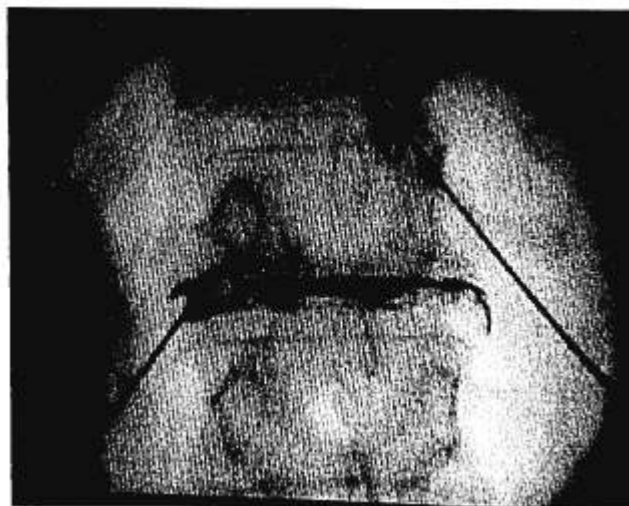


FIG. 2. Fluoroscopy screen indicating needle placement for celiac block. The needle at right in the photograph (on the left of the patient) is placed correctly, and the injected dye has spread in the correct plane locally. The other needle has entered the annulus of the L1-L2 intervertebral disc. Contrast dye can be seen within a degenerated disc space, spreading throughout the degenerated disc and exiting both laterally to the paravertebral space and posterior into the epidural space through an annular tear.

verse effects from the dye injection into the disc space or vertebral canal, and no adverse effects of the celiac block.

DISCUSSION

These cases appear to be the first reported in which documentation exists of incidental intervertebral disc penetration during celiac plexus block. The second case also illustrates a mechanism by which a neurolytic agent could gain access to the vertebral canal, despite radiologic evidence that the needle was clearly outside the canal. This phenomenon of disc injectate spreading to the epidural space is not uncommon during diagnostic discography.¹³ This spread of injected fluid from the disc is well known to discographers¹⁴ but is not referred to in standard anesthetic or pain texts. Although diagnostic discography probably does not injure normal discs,¹⁵ the most serious reported complications of discography is discitis.¹⁶ This complication is rare and fortunately did not occur in these cases.

The incidence of inadvertent or incidental disc penetration during celiac plexus block cannot be calculated. The possibility is always present, because deliberate attempts are made to bring the needle into contact with the vertebral body during the procedure. It would be more likely during lumbar paravertebral sympathetic block because of a more favorable needle angle. However, in many cases, the resistance to penetration of the disc alerts the operator that the needle may be penetrating a structure it should not penetrate. The annulus of the disc is supplied

by sinuvertebral nerves,¹⁷ which may cause local and referred pain if stimulated.^{18, 19} However, in some cases, the disc may be penetrated without pain. In addition, local anesthetic was infiltrated during passage of the needle, which should have reduced the sensitivity of the annulus. In the setting of celiac plexus block, however, disc injection is a potentially serious situation because of the continuity that may exist between a degenerated disc and the vertebral canal. A degenerated disc can offer minimal resistance to injection, and injection might also not cause pain. On the contrary, a small test dose of local anesthetic could produce pain relief if some spread *via* the disc to the epidural space, falsely indicating correct needle placement. If, in the belief that the needle is in the correct position, the full neurolytic dose of alcohol should then be injected, paraplegia could result from the neurolytic agent spreading into the epidural space.

These cases provide further support for the practice of radiologic control in real time during celiac blockade.

REFERENCES

1. Ward EM, Rorie DK, Nauss LA, Bahn RC: The celiac ganglia in man: Normal anatomic variations. *Anesth Analg* 58:461-465, 1979
2. Moore DC, Bush WH, Burnett LL: Celiac plexus block: A roentgenographic, anatomic study of technique and spread of solution in patients and corpses. *Anesth Analg* 60:369-379, 1981
3. Singler RC: An improved technique for alcohol neurolysis of the celiac plexus. *ANESTHESIOLOGY* 56:137-141, 1982
4. Ischia S, Luzzani A, Ischia A, Faggion S: A new approach to the neurolytic block of the coeliac plexus: The transaortic technique. *Pain* 16:333-341, 1983
5. Cousins MJ: Anesthetic approaches in cancer pain. *Advances in Pain Research and Therapy*. Edited by Foley KM, Bonica JJ, Ventafridda V. New York, Raven Press, 1990, pp 249-273
6. Brown DL, Bulley CK, Quiel EL: Neurolytic celiac plexus block for pancreatic cancer pain. *Anesth Analg* 66:869-873, 1987
7. Brown DL: A retrospective analysis of neurolytic celiac plexus block for non-pancreatic intra-abdominal cancer pain. *Reg Anesth* 14:63-65, 1989
8. Cousins MJ: Chronic pain and neurolytic neural blockade, *Neural Blockade in Clinical Anesthesia and Management of Pain*. Edited by Cousins MJ, Bridenbaugh PO. Philadelphia, JB Lippincott, 1988, pp 1053-1084
9. Cherry DA, Lamberty J: Paraplegia following coeliac plexus block. *Anaesth Intens Care* 12:59-61, 1984
10. Woodham MJ, Hanna MH: Paraplegia after celiac plexus block. *Anaesthesia* 44:487-489, 1989
11. Sett SS, Taylor DC: Aortic pseudoaneurysm secondary to celiac plexus block. *Ann Vasc Surg* 5:88-91, 1991
12. Fujita Y, Takaori M: Pleural effusion after CT-guided alcohol celiac plexus block. *Anesth Analg* 66:911-912, 1987
13. Aprill CN III: Diagnostic disc injection. *The Adult Spine: Principles and Practice*. Edited by Frymoyer JW. New York, Raven Press, 1991, pp 403-442
14. Executive Committee of the North American Spine Society: Position statement on discography. *Spine* 13:1343, 1988
15. Johnson RG: Does discography injure normal discs? An analysis of repeat discograms. *Spine* 14:424-426, 1989
16. Fraser RD, Osti OL, Vernon-Roberts B: Iatrogenic discitis: The role of intravenous antibiotics in prevention and treatment: An experimental study. *Spine* 14:1025-1032, 1989
17. Bogduk N, Tynan W, Wilson AS: The nerve supply to the human lumbar intervertebral discs. *J Anat* 132:39-56, 1981
18. Jackson RP, Cain JE, Jacobs RR, Cooper BR, McManus GE: The neuroradiographic diagnosis of lumbar herniated nucleus pulposus: I. A comparison of computed tomography (CT), myelography, CT-myelography, discography, and CT-discography. *Spine* 14:1356-1361, 1989
19. Weinstein J, Claverie W, Gibson S: The pain of discography. *Spine* 13:1344-1348, 1988

Anesthesiology
76:316-318, 1992

Subdural Block during Attempted Caudal Epidural Analgesia for Labor

TERRENCE M. CALDER, M.D.,* ANDREW P. HARRIS, M.D.†

Although subdural blocks following attempted lumbar epidural injections are well documented,¹⁻⁹ there are no reports of suspected subdural injections following attempted caudal epidural anesthesia. We describe a case

of unexpected, delayed high motor block with prolonged regression following attempted caudal epidural analgesia in a patient in labor.

CASE REPORT

A 27-yr-old, gravida 2 para 1 patient at term gestation was admitted in labor. She weighed 73 kg and was 178 cm tall. Her review of systems

* Resident, Department of Anesthesia, National Naval Medical Center.

† Staff Anesthesiologist, Department of Anesthesia, National Naval Medical Center; Assistant Professor of Anesthesiology/Critical Care Medicine and Gynecology/Obstetrics, The Johns Hopkins University School of Medicine, Baltimore, Maryland.

Received from the National Naval Medical Center, Bethesda, Maryland. Accepted for publication October 14, 1991.

The opinions expressed in this article are the personal opinions of the authors and do not necessarily reflect official policy of the Department of the Navy or the Department of Defense.

Key words: Anesthesia: obstetric. Anesthetic techniques: caudal. Complications: subdural.