

CASE REPORTS

Anesthesiology
76:468-469, 1992

Airway Fire during Jet Ventilation for Laser Excision of Vocal Cord Papillomata

EDWARD S. WEGRZYNOWICZ, M.D.,* NIELS F. JENSEN, M.D.,† KENT S. PEARSON, M.D.,‡
RUTH E. WACHTEL Ph.D.,‡ FRANKLIN L. SCAMMAN, M.D.§

Supraglottic jet ventilation (SJV) is effective in providing both adequate oxygenation and ventilation for patients undergoing laser surgery.¹ One purported major advantage of SJV, in addition to providing an unobstructed operative field, is the elimination of extraneous combustible material, specifically the endotracheal tube, from the airway.

This is a report of an airway fire associated with SJV and a carbon dioxide laser. An errant laser strike ignited the surgeon's latex glove outside the oropharynx. The resultant burning vapors were entrained into the airway. The burning oxygen-enriched mixture was spread by exhalation around the laryngoscope and under the soaking wet "protective" draping, igniting the patient's mustache and causing facial burns.

CASE REPORT

A 35-yr-old man presented for laser ablation of recurrent laryngeal papillomata. History and physical examination were unremarkable other than a 20 pack-yr smoking history, a bushy mustache, and a weight of 129 kg. Anesthesia was induced with thiopental and fentanyl. Ventilation *via* mask with oxygen, nitrous oxide, and isoflurane was without difficulty. Vecuronium was given to provide relaxation. The surgeon inserted an adult Dedo laryngoscope, and jet ventilation was instituted with oxygen *via* a 13-G cannula inserted in the left light-carrier channel of the Dedo laryngoscope. A thumb-controlled valve and 50 psi oxygen powered the jet.

The patient's face and the perioral area were covered with soaking wet towels such that only the barrel of the Dedo laryngoscope was visible. Anesthesia was maintained with thiopental and fentanyl during jet ventilation. There were no intraoperative problems except for brief periods of decreased hemoglobin oxygen saturation measured by pulse oximetry (Sp_{O_2}) during some episodes of apnea that were requested by the surgeon to eliminate movement of the vocal cords.

Near the end of the surgical procedure, the surgeon suddenly yelled "fire," and bright blue and orange flames accompanied by a muffled

roar were observed coming up through and around the laryngoscope. Jet ventilation was stopped; the towels were removed; and the patient's blazing mustache was extinguished with the wet towels. The surgeon, who was in a great deal of pain, noted that the latex glove had been burned away from two of the fingertips of his right hand. The Dedo laryngoscope was removed, and bag-and-mask ventilation was commenced. Subsequent rigid bronchoscopy revealed no carbonaceous material in the trachea, and except for evidence of lasering, the glottis was normal. Muscle relaxation was reversed and the patient was awakened. Recovery from anesthesia was otherwise unremarkable.

The patient suffered second degree burns to his right upper lip and nasal rim. These were treated with 1% silver sulfadiazine (Silvadine) and healed over the next 2 weeks without further incident. The only other evidence of airway fire was burned nasal hair. The surgeon suffered second degree burns to the right index and middle fingers that were severe enough to prevent him from operating for 1 week.

DISCUSSION

SJV is a useful technique for removing carbon dioxide and oxygenating patients during laser ablation of laryngeal papillomata and other masses of glottic and subglottic regions. Excellent coordination between the surgeon and the anesthesiologist is necessary to maintain a patent airway during surgery. The availability of short-acting muscle relaxants, hypnotics, and opioids has overcome our inability to provide accurate delivery or effective scavenging of volatile anesthetics *via* jet ventilation.

This patient experienced an unusual complication of SJV. An errant laser strike on the surgeon's latex glove ignited the glove, producing hot volatile fuel that was entrained by the jet ventilator. Combustion of the vaporized latex accelerated dramatically in the oxygen-enriched atmosphere of the airway. The gaseous products of combustion escaped through either the patient's nose or mouth (fig. 1) and in turn ignited his mustache, despite the "protective" wet drapes. It would be impossible to determine to what degree the patient's mustache contributed to his facial burns, or whether combustion alone under the drapes would have been adequate to cause the degree of injury sustained.

Several precautions against direct laser strike injury had been taken. The airway contained no extraneous flammable material, and the patient's face was shielded from direct laser strike by soaking wet drapes. This incident occurred despite those precautions.

The presence of high concentrations of oxygen in the airway clearly contributed to this incident. Our attempts to ignite latex surgical gloves using the same laser setting in room air were unsuccessful. In room air the laser melted

* Assistant Chief of Anesthesiology Service and Assistant Professor.

† Associate.

‡ Assistant Professor.

§ Chief of Anesthesiology Service and Associate Professor.

Received from Anesthesiology Service, Department of Veterans Affairs Medical Center, Iowa City, Iowa and Department of Anesthesia, The University of Iowa College of Medicine, Iowa City, Iowa. Accepted for publication October 21, 1991.

Address reprint requests to Dr. Wegrzynowicz: Anesthesiology Service (112A), Department of Veterans Affairs Medical Center, Iowa City, Iowa 52246.

Key words: Anesthesia techniques; jet ventilation. Complications: Airway fire. Surgery: laser coagulation.

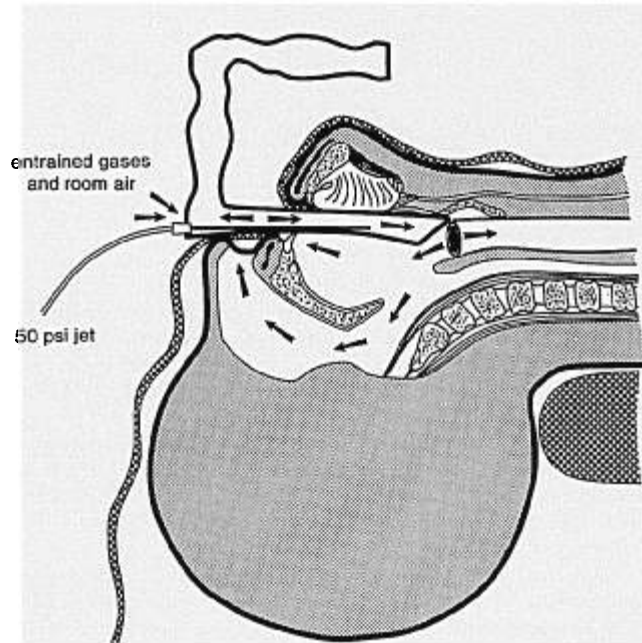


FIG. 1. Normal pathways for delivery of oxygen, entrainment of room air, and exhalation of gases during jet ventilation. In this incident, vaporized latex from the surgeon's glove was entrained by the jet into the airway. Combustion accelerated in the oxygen-enriched atmosphere of the pharynx, and burning latex escaped through the laryngoscope, mouth, and nares.

and charred the latex, but sustained combustion did not occur. Sustained surgical glove combustion occurred only at oxygen concentrations greater than 50%, and accelerated combustion occurred at oxygen concentrations greater than 65%.

In this patient, the jet used pure dry oxygen and relied on the Venturi effect to entrain room air. At the end of inspiration the SJV ceases to maintain the Venturi effect and no longer entrains room air to dilute the oxygen. When the Venturi effect is no longer contributing to ventilation, the jet is said to be "stalled." The oxygen injected *via* the jet ventilator during late inspiration collects in the pharynx, and some is passively exhaled *via* the laryngoscope. However, some of the oxygen-enriched gas is exhaled through the mouth and nose and accumulates under the drapes.

Dilution of oxygen with nitrous oxide would not have provided any additional margin of safety because nitrous oxide supports combustion as readily as oxygen and because equivalent amounts of fuel produce more thermal energy when consumed in an excess supply of nitrous

oxide than in oxygen.² However, relatively inert gases such as air, nitrogen, or helium should provide increased protection by diluting oxygen.

This incident does not mean that SJV should be abandoned in favor of more traditional methods of ventilation. Use of SJV eliminates the presence of a flammable polyvinyl chloride endotracheal tube.³ In this patient an errant laser strike igniting a combustible endotracheal tube may have caused complications more serious than a burned mustache and lip. In addition to thermal injury, ignition of a polyvinyl chloride endotracheal tube in the presence of combustion-supporting gases such as oxygen and nitrous oxide could produce injury from inhalation of toxic gases, including hydrogen cyanide, phosgene, hydrogen chloride, and chlorine.⁴⁻⁶

One goal in SJV should be to ventilate with the lowest oxygen concentration consistent with patient safety. 100% oxygen is not always necessary to maintain adequate Sp_{O_2} . Oxygen concentration should be decreased whenever possible by blending with nitrogen or air to reduce the possibility of unwanted combustion.

CONCLUSION

SJV has clear advantages over tracheal intubation for certain laser procedures. Nevertheless, SJV does have its limitations, and the anesthesiologist must always remain alert to the risk of fire despite the apparent absence of combustible material placed in the airway. The risk of fire is always present when increased oxygen concentrations and high energy sources (laser and electrocautery) are present in close proximity. With care this risk can be minimized.

REFERENCES

1. Scamman FL, McCabe BF: Supraglottic jet ventilation for laser surgery of the larynx in children. *Ann Otol Rhinol Laryngol* 95:142-145, 1986
2. Mushin WW, Jones PL: Oxidation, combustion, flames, deflagrations and detonations, *Physics For the Anaesthetist*. Oxford, Blackwell Scientific Publications, 1987, pp 539-540
3. Fried M: Complication of CO₂ laser surgery of the larynx. *Laryngoscope* 93:275-278, 1983
4. Dyer RF, Esch VH: Polyvinyl chloride toxicity in fires: Hydrogen chloride toxicity in fire fighters. *JAMA* 235:393-397, 1976
5. Crapo RO: Smoke inhalation injuries. *JAMA* 246:1694-1696, 1981
6. Fein A, Leff A, Hopewell PC: Pathophysiology and management of the complications resulting from fire and inhaled products of combustion: Review of the literature. *Crit Care Med* 8:94-98, 1980