

Anesthetic Management of Patients Undergoing Cardiomyoplasty

JOSÉ OTAVIO COSTA AULER, JR., M.D., PH.D.,* LUIZ FELIPE PINHO MOREIRA, M.D.,†
 MARIA JOSÉ DE CARVALHO, M.D.,‡ NOEDIR ANTONIO GROppo STOLF, M.D., PH.D.,§
 RUY VAZ GOMIDE DO AMARAL, M.D., PH.D.,¶ ADIB DOMINGOS JATENE, M.D., PH.D.**

Despite recent advances in cardiac transplantation and medical therapy, irreversible myocardial failure remains a significant cause of mortality.†† Cardiomyoplasty is a recently introduced surgical method to improve myocardial performance: it consists of the placement of a skeletal muscle flap around the heart and stimulation of the flap in synchrony with ventricular contraction.¹ Reversal of congestive heart failure and improvement in patients' functional capacity have been reported by several authors.²⁻⁴ We report the anesthetic management and hemodynamic changes in patients who underwent cardiomyoplasty.

CASE REPORTS

From May 1988 to September 1991, 21 patients with end-stage heart disease consented to and underwent cardiomyoplasty. This study was conducted in accordance with the Institutional Review Board. All patients fulfilled the clinical criteria for heart transplantation but presented psychosocial contraindications to transplantation. Despite medical therapy, 15 patients were in New York Heart Association Class III and 6 in Class IV. Seventeen patients had idiopathic dilated cardiomyopathy; 2 had Chagas' disease; and 2 had postischemic cardiomyopathy. Mean age was 47.3 yr (range 16-63 yr), and mean weight was 68 ± 5 kg (range 49.5-84.5). Preoperative diagnostic and functional studies (Doppler echocardiography and radioisotopic angiography) revealed severely compromised cardiac function (table 1).

* Associate Professor of Anesthesia.

† Staff Surgeon.

‡ Staff Anesthesiologist.

§ Associate Professor of Surgery.

¶ Chairman, Department of Anesthesia.

** Chairman, Department of Surgery.

Received from the Departments of Anesthesiology and Cardiothoracic Surgery, Instituto do Coração do Hospital das Clínicas da Faculdade de Medicina da Universidade de São Paulo, São Paulo, Brazil. Accepted for publication March 23, 1992.

Address reprint requests to Dr. Auler: Department of Anesthesiology, Instituto do Coração do Hospital das Clínicas da Faculdade de Medicina da Universidade de São Paulo, Av. Dr. Eneas de Carvalho Aguiar, 44, 05403-São Paulo, Brazil.

Key words: Anesthesia, cardiac surgery, cardiomyoplasty, heart, congestive failure; ventricular function.

†† Stevenson LW, Perloff JK: The dilated cardiomyopathies: Clinical aspects. *Cardiology Clinics* 6:187-218, 1988.

Surgical Procedure

Cardiomyoplasty was carried out using the reinforcement technique described by Carpentier and Chachques² without the use of cardiopulmonary bypass (fig. 1).

Initially, with the patient in the left lateral position, the latissimus dorsi muscle was mobilized and rotated on its neurovascular pedicle into the chest through a window created by partial resection of the second rib. Two intramuscular pacing electrodes were implanted in the proximal area of the latissimus dorsi muscle flap for neuromuscular stimulation. The cathode was placed in close proximity to the distribution of the main nerve branches into the muscle. The anode was implanted transversely into the muscle. Stimulation threshold and impedance were then recorded. To prevent failures in the electrophysiologic tests, neuromuscular blocking agent infusion was interrupted 20-30 min before testing and neuromuscular blockade maintained at 10% twitch depression.

Subsequently, patients were placed in the supine position, and the heart exposed through a median sternotomy. Access to the latissimus dorsi muscle flap and pacing leads was obtained with a long incision in the left pleura. The muscle flap was wrapped around the left and right ventricular surface, and an epicardial lead was implanted.

Anesthetic Procedure

All patients were monitored with a continuous electrocardiogram, pulse oximeter, end-tidal CO₂ concentration, and an esophageal temperature probe. Two intravenous catheters, an arterial cannula, and a flow-directed balloon-tipped pulmonary artery catheter were inserted under local anesthesia and sedation. Induction of anesthesia was performed with midazolam 10-15 mg and fentanyl 250 µg. Atracurium (0.4 mg/kg) was given to facilitate tracheal intubation. A double-lumen endobronchial tube was used to perform one-lung ventilation during rib resection and muscle flap introduction into the thoracic cavity. Conventional volume-controlled ventilation was applied. Initial settings were tidal volume 10-15 ml/kg, F_IO₂ = 0.5 in air, and PEEP 3-10 cmH₂O. These settings were readjusted based on end-tidal CO₂, PaCO₂, SpO₂, PaO₂, and cardiac output measurements. Anesthesia was maintained with intermittent doses of midazolam and fentanyl. Subsequent doses of atracurium were given to maintain neuromuscular blockade at approximately 60-80% twitch depression. Dopamine, dobutamine, and sodium nitroprusside were administered as dictated by the hemodynamic profile.

TABLE 1. Ventricular Function Data

	Preoperative	Follow-up		P*
		6 Months	12 Months	
Doppler echocardiography				
LVSW (%)	12 ± 3	17.8 ± 2.3	16.8 ± 2.8	0.001
LVSV (ml)	32.3 ± 7.9	32.3 ± 7.9	36.6 ± 10	0.006
CO (l · min ⁻¹)	2.31 ± 0.52	2.75 ± 0.47	3.19 ± 0.6	0.03
Radioisotopic angiography				
LVEF (%)	20.8 ± 3.9	25.6 ± 7.2	27.4 ± 8.9	0.01

Data are mean ± SD.

LVSW = left ventricular segmental wall shortening; LVSV = left ventricular stroke volume; CO = cardiac output; LVEF = left ven-

tricular ejection fraction.

* Preoperative *versus* follow-up data.

Results

Mean anesthesia time was 10.2 ± 1.2 h. All patients presented with low cardiac output and high pulmonary and systemic vascular resistances in the initial hemodynamic measurement (table 2). Dopamine, dobutamine, and sodium nitroprusside were administered to all patients to improve the hemodynamic profile. Mean intraoperative blood loss was 420 ± 65 ml. Red packed cells were given to three patients. In five patients, furosemide was necessary to maintain adequate urine output. Arterial blood pressure remained stable during the procedure except in the presence of arrhythmias, during muscle heart-wrapping, or, in five patients, during one-lung ventilation. Four patients presented Sp_{O₂} less than 85% during one-lung ventilation, despite PEEP and FI_{O₂} = 1. Hypoxemia was treated with conventional ventilation, temporary interruption of surgical maneuvers, and improved hemodynamic support. Two patients developed ventricular fibrillation during muscle heart-wrapping that required countershock. Stay in the intensive care unit was 7.2 ± 2 days.

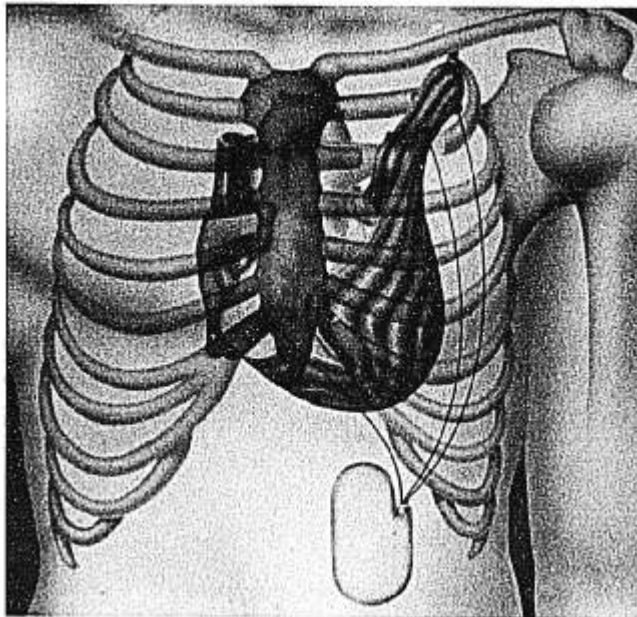


FIG. 1. Cardiomyoplasty procedure.

Mechanical ventilation was maintained for 72.3 ± 8 h. There were no intraoperative or early postoperative deaths.

Eight patients died in the late follow-up (2–42-month) period, two of pulmonary thromboembolism, three of progression of heart failure (in two patients, multiple organ failure associated with muscle flap ischemia), two of sudden death, and one of cerebral stroke. Actuarial 1- and 2-yr survival rates were 73.2% and 65.9%, respectively. Six patients reverted to New York Heart Association Class I, six to Class II, and one to Class III. Postoperative ventricular function assessment by Doppler echocardiography and radioisotopic angiography (table 1) showed a significant improvement (6- and 12-month follow-up *vs.* preoperative data).

DISCUSSION

Despite the promising results of cardiac transplantation, this procedure has limitations, including restricted availability of donor organs and the adverse effects of immunosuppressive therapy. As a result, dilated cardiomyopathy, present in more than 50% of transplantation candidates, remains a significant cause of death, especially in Brazil, where there is a high incidence of Chagas' disease.

Cardiomyoplasty has been suggested as an alternative surgical treatment to certain end-stage heart diseases.⁵ The adaptive response of skeletal muscle to a fatigue-resistant state suitable for chronic ventricular assistance is the principle on which dynamic cardiomyoplasty is based. After the initial postoperative period, sequential and progressive muscle electrostimulation results in the transformation of all glycolytic muscle fibers into oxidative fibers resistant to fatigue, having the histochemical and biochemical characteristics of myocardium.⁶ This process is usually initiated in the 2nd postoperative week and completed after 6 weeks. After the conditioning period, the muscle flap is paced in a one-to-one mode synchronously with the heart rate.

Initial experience with cardiomyoplasty reported by Carpentier and Chachques¹ were followed by clinical protocols in several centers.^{3–5} Our results confirm a significant improvement in cardiac performance, as shown by increments in left ventricular ejection fraction and seg-

TABLE 2. Intraoperative Hemodynamic Data

	A	B	C	D	E
CI ($l \cdot \text{min}^{-1} \cdot \text{m}^{-2}$)	1.66 ± 0.29	2.59 ± 0.57	2.80 ± 0.5	2.94 ± 0.56	2.92 ± 0.36
MAP (mmHg)	75 ± 7	75 ± 8	79 ± 8	76 ± 7	77 ± 6
PCWP (mmHg)	23 ± 4	20 ± 6	19 ± 8	21 ± 5	20 ± 6
CVP (mmHg)	13 ± 6	13 ± 5.5	12 ± 5.8	13 ± 3	12 ± 5
PVR ($\text{dyn} \cdot \text{s} \cdot \text{cm}^{-5}$)	285 ± 115	180 ± 63	185 ± 60	151 ± 42	146 ± 50
SVR ($\text{dyn} \cdot \text{s} \cdot \text{cm}^{-5}$)	1780 ± 525	1200 ± 270	1050 ± 240	1080 ± 230	1110 ± 245

Data are mean ± SD.

A = preanesthesia induction; B = after anesthesia induction; C = lateral decubitus; D = supine decubitus; E = preclosing; CI = cardiac

index; MAP = mean arterial pressure; PCWP = pulmonary capillary wedge pressure; CVP = central venous pressure; PVR = pulmonary vascular resistance; SVR = systemic vascular resistance.

mental wall shortening.⁷ However, cardiomyoplasty implies a delay of 2 weeks until muscle stimulation is initiated, and this fact may represent a limitation in patients with end-stage circulatory failure.

Cardiomyoplasty presents advantages over other surgical procedures because it does not require cardiopulmonary bypass and because it is independent of the availability of organ donors, a crucial limiting factor in transplantation. The absence of surgical mortality in our series supports the use of cardiomyoplasty as an alternative treatment for advanced heart failure.

Monitoring of neuromuscular blockade is important to avoid interference with electrophysiologic testing of the muscle flap. We chose atracurium because it has an intermediate duration of action, does not require hepatic or renal function for termination of effect, and does not have a cumulative effect. Vecuronium probably would be equally effective.

Pulmonary dysfunction represents a limitation to the use of this technique. After placement in the thorax, the latissimus dorsi muscle volume represents approximately 5%–10% of the hemithorax and allows conservation of nearly normal lung function. In our series of patients, dissection and transposition of the latissimus dorsi muscle lead to a vital capacity decrease of $18.4\% \pm 2.3\%$.⁷ This decrease, however, presented no clinical symptomatology. In our institution, patients with previous pulmonary diseases are not accepted as candidates for cardiomyoplasty.⁸

The use of one-lung ventilation during rib resection and muscle flap transposition is debatable. Bensasson and Kieffer do not use this ventilatory technique.⁹ However, despite the physiologic alterations and technical difficulties, we believe that one-lung ventilation greatly facilitates the surgical maneuvers in the thoracic cavity.

Severe mitral regurgitation and enlargement of the left ventricle, which occurs in a high percentage of patients with dilated cardiomyopathy, have been suggested as contraindications for cardiomyoplasty.⁷ In our series of patients, we observed less improvement of the ventricular function in a patient with greater left ventricular dimension.

In conclusion, cardiomyoplasty represents an alternative to orthotopic cardiac transplantation in patients with end-stage ventricular failure. Further studies are needed to establish the efficacy and the precise role of this procedure in the long-term treatment of heart failure.

The authors are indebted to Dr. Carlos Parsloe and Dr. Flavio Takooka for their review and suggestions in the preparation of this manuscript.

REFERENCES

1. Carpentier A, Chachques JC: Myocardial substitution with a stimulated skeletal muscle: First successful clinical case (letter). *Lancet* 1:1267, 1985
2. Chachques JC, Grandjean PA, Carpentier A: Latissimus dorsi dynamic cardiomyoplasty. *Ann Thorac Surg* 47:600–604, 1988
3. Magovern GJ, Park SB, Magovern GH, Jr., Benckart DH, Tullis G, Rozar E, Kao R, Christlieb I: Latissimus dorsi as a functioning synchronously paced muscle component in the repair of a left ventricular aneurysm (letter). *Ann Thorac Surg* 41:116, 1986
4. Moreira LFP, Stolf NAG, Bocchi EA, Barreto ACP, Meneghetti JC, Giorgi MPC, Moraes AV, Leite JJ, Luz PL, Jatene AD: Latissimus dorsi cardiomyoplasty in the treatment of patients with dilated cardiomyopathy. *Circ* 82:IV-257–IV-263, 1990
5. Molteni L, Almada H, Ferreira R: Synchronously stimulated skeletal muscle graft for left ventricular assistance. *Thorac Cardiovasc Surg* 97:439–446, 1989
6. Henriksson J, Salmons S, Lowry OH: Chronic stimulation of mammalian muscle: Enzyme and metabolite changes in homogenates and individual fibers, *Transformed Muscle for Cardiac Assist And Repair*. Edited by Chiu RCJ, Bourgeois IM. New York, Futura Publishing Co. Inc., 1990, pp 9–24
7. Moreira LFP, Stolf NAG, Jatene AD: Hemodynamic benefits of cardiomyoplasty in clinical and experimental myocardial dysfunction, *Transformed Muscle for Cardiac Assist And Repair*. Edited by Chiu RCJ, Bourgeois IM. New York, Futura Publishing Co. Inc., 1990, pp 179–188
8. Moreira LFP, Jatene AD: Cardiomyoplasty in dilated cardiomyopathy, *Cardiomyoplasty*. Edited by Carpentier A, Chachques JC, Grandjean PA. New York, Futura Publishing Co. Inc., 1991, pp 171–179
9. Bensasson D, Kieffer JP: Preoperative management and anesthesia, *Cardiomyoplasty*. Edited by Carpentier A, Chachques JC, Grandjean PA. New York, Futura Publishing Co. Inc., 1991, pp 99–103