

blood loss necessitated the initiation of resuscitative measures. While the attention of the anesthesiologist was focused on the securing of the central venous access, the back of the anesthesia chair bumped the knob, resulting in the sudden loss of gas and power supply, totally disabling the anesthesia machine. Fortunately, the brief alarm sound was noticed promptly, and the switch was turned on again. The consequences of missing this single alarm sound could have been fatal because no other alarms would follow.

This safety hazard can be eliminated either by placing a protective guard around the current switch or by replacing it with the corrugated knob.

ZBIGNIEW POMYKALA, M.D.
HOWARD SCHECHTER, M.D.

Anesthesiology
77:400, 1992

In Reply:—The safety of patients and operators is of utmost importance to Ohmeda. The switch referred to in this report has been used in Excel machines since mid-1989. Pomykala and Schechter's report is the first of its kind received by Ohmeda.

Ohmeda has conducted laboratory testing and has been able to duplicate the event described but with some degree of difficulty. When the event was duplicated, a machine alarm activated, as expected. This alarm condition is documented in the Excel's Operation and Maintenance Manual.

Given these facts, Ohmeda does not perceive the existence of a safety problem that would warrant modifying the switch. If other users have experienced similar events associated with the switch, Ohmeda

Anesthesiology
77:400-401, 1992

A Simple Alternate Technique for the Application of the Pulse Oximeter Probe to Infants

To the Editor:—Because of the difficulty in applying adhesive-backed oximeter probes to the extremities of small infants, we were interested in learning whether adult clip-on probes worked accurately in these patients. The clip-on probe for adults is placed on either part of the infant's hand, including some fingers, or part of the foot, including some toes (fig. 1). We concurrently applied two identical pulse oximeters, one using the adhesive infant probe and one using the clip-on adult probe, to the finger, hand, or foot of 12 infants undergoing ophthalmologic surgery. In each infant, we observed that the adult probe gave hemoglobin oxygen saturation readings that were within 1% of those obtained by the concurrent conventional procedure. We have successfully used this procedure in more than 100 infants and small children. Almost all of the procedures were completed within 1 h and without any complication. However, for long-duration anesthesia, caution should be exercised to prevent probe-induced complications (*i.e.*, pressure marks, burn, erosion, or necrosis). Further studies are therefore required to extrapolate this technique to neonates, whose skin is more delicate, and in lengthy cases during which burn or erosion may occur.

KATSUYA MIKAWA, M.D.
Instructor

NOBUHIRO MAEKAWA, M.D.
Associate Professor

*Department of Anesthesiology
St. Francis Hospital of Evanston
355 Ridge Avenue
Evanston, Illinois 60202*

REFERENCE

1. Cooper JB, Newbower RS, Kitz RJ: An analysis of major errors and equipment failures in anesthesia management: Considerations for prevention and detection. *ANESTHESIOLOGY* 60:34-42, 1984

(Accepted for publication April 27, 1992.)

would be interested in hearing from them. They can contact the Product Complaint Specialist at 1-800-521-0086.

VERNA M. FITZSIMMONS
*Product Safety Engineer
Ohmeda
Ohmeda Drive
P. O. Box 7550
Madison, Wisconsin 53707-7550*

(Accepted for publication April 27, 1992.)

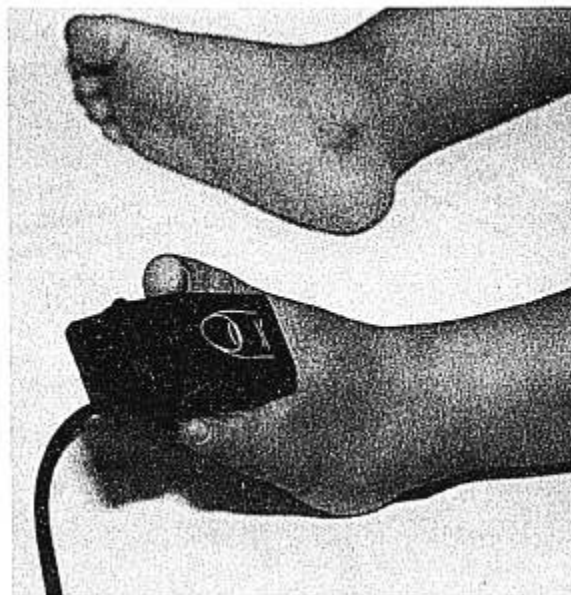


FIG. 1. Fixation of adult clip-on probe (Cardiicap[®], Datex, Finland) in a 10-month-old infant undergoing ophthalmologic surgery. This procedure can be applied to pulse oximeters from several companies (*e.g.*, Ohmeda and Nellcor).

RYOKICHI GOTO, M.D.

Instructor

HIDEAKI YAKU, M.D.

Clinical Fellow

HIDEFUMI OBARA, M.D.

Professor and Chairman

Department of Anaesthesiology
Kobe University School of Medicine
Kusunoki-cho 7, Chuo-ku
Kobe 650, Japan

(Accepted for publication May 11, 1992.)

Anesthesiology
77:401, 1992

Intubation and Extubation of the Patient with Pierre-Robin Syndrome

To the Editor:—Chadd *et al.*¹ should be congratulated for successfully managing the difficult airway of a 3-month-old patient with Pierre-Robin syndrome. However, even though their airway management techniques were useful, new, and innovative, the techniques ignore two useful and recent developments that might have been additionally helpful.

First, although the initial intubation for fundoplication and gastrostomy with conventional laryngoscopy "was successful after numerous attempts even though the vocal cords were never visualized," it may have been more prudent to accomplish the initial intubation over a fiberoptic instrument. Indeed, fiberoptic laryngoscopy was performed as part of the preoperative evaluation. One of the main lessons from the ASA closed claims studies is that repeated traumatic instrumentation of the upper airway may result in periglottic edema and loss of the ability to ventilate *via* mask.² Fiberoptic intubation can be accomplished after induction of anesthesia during continuous positive or negative pressure ventilation either *via* an anesthesia mask that has a dedicated self-sealing fiberoptic port³ or *via* a laryngeal mask airway.⁴ Similarly, the reintubation technique of the patient for tracheostomy involved blindly passing a guide through the laryngeal mask airway into the trachea. What if the guide did not go back into the trachea? Even though "capnography *via* the lumen of the guide" revealed the "presence of carbon dioxide," the reintubation guide could still have been in the pharynx (and perhaps within the rim of the laryngeal mask airway). Carbon dioxide can be retrieved and a normal-looking carbon dioxide waveform obtained from a pharyngeal location. The tracheal reintubation *via* a laryngeal mask airway could also have been visualized fiberoptically.⁴

Second, the guide that was used to facilitate extubation on the 2nd postoperative day could or should have been considered a jet stylet (not just a hollow reintubation stylet).^{2,5} Thus, although the laryngeal mask airway was intended to serve as the ventilation backup if spontaneous ventilation around the extubation guide was not adequate, this could have also been accomplished by using the extubation guide as a jet stylet. The laryngeal mask airway would not have been a good choice for backup ventilation if difficulty with ventilation was due to laryngeal edema or laryngospasm. The extubation guide can be used as a jet stylet if it passes out of the ventilation circuit through a self-sealing diaphragm in the elbow connector (see fig. 1 of ref. 6 or fig. 11 of ref. 2),^{2,6} whereas the extubation guide cannot be used as a jet

stylet if it passes up the ventilatory hosing, as appears in figure 1 of reference 1.

In summary, my main point is that useful techniques do not need to be mutually exclusive of one another. With respect to the initial intubation, fiberoptic equipment could be used in series with conventional equipment; with respect to the final intubation, the intubation guide through a laryngeal mask airway can be a fiberoptic instrument. Finally, the function of an extubation guide can easily be expanded to that of a jet ventilation stylet.

JONATHAN L. BENUMOF, M.D.

Professor of Anesthesia

Department of Anesthesiology

UCSD Medical Center

Mail Code 8812

225 Dickinson Street

San Diego, California 92103-8812

REFERENCES

1. Chadd GD, Crane DL, Phillips RM, Tunell WP: Extubation and reintubation guided by the laryngeal mask airway in a child with the Pierre-Robin syndrome. *ANESTHESIOLOGY* 76:640-641, 1992
2. Benumof JL: Management of the difficult adult airway: With special emphasis on awake tracheal intubation. *ANESTHESIOLOGY* 75: 1087-1110, 1991
3. Rogers S, Benumof JL: New and easy techniques for fiberoptic endoscopy-aided tracheal intubation. *ANESTHESIOLOGY* 59: 569-572, 1983
4. Benumof JL: Use of the laryngeal mask to facilitate fiberoptic-endoscopy intubation. *Anesth Analg* 74:313-314, 1992
5. Gaughan SD, Benumof JL, Ozaki G: Quantification of the jet function of a jet stylet. *Anesth Analg* 74:580-585, 1992
6. Goscowicz R, Gaughan S, Ozaki G, Benumof JL: It is not necessary to remove a jet stylet in order to determine tracheal tube location. *J Clin Anesth* 4:42-44, 1992

(Accepted for publication May 18, 1992.)

Anesthesiology
77:401-402, 1992

Position of the Laryngeal Mask Airway

To the Editor:—In the recent article by Chadd *et al.*,¹ we were pleased to read that the laryngeal mask airway (LMA) was used to resolve a problem with airway management in a child with Pierre-Robin syndrome. However, we would like to bring out an important misconception

that is shown in figure 1. The drawing shows the proximal end of the cuff of the LMA pressing against the epiglottis. This position was originally thought to be accurate. We have recently completed a study in which a sagittal midline scan was obtained using magnetic