

■ CASE REPORTS

Anesthesiology
78:191-194, 1993
© 1993 American Society of Anesthesiologists, Inc.
J. B. Lippincott Company, Philadelphia

The Diagnosis and Management of a Perianesthetic Cerebral Aneurysmal Rupture Aided with Transcranial Doppler Ultrasonography

Calvin C. Eng, M.D.,* Arthur M. Lam, M.D., F.R.C.P.C.,† Sheila Byrd, R.V.T.,‡ David W. Newell, M.D.§

INTRAOPERATIVE rupture of a cerebral aneurysm is associated with an increased risk of morbidity and mortality.¹ The incidence of aneurysm rupture is dependent on the size and the anatomic location of the aneurysm, and varies among neurosurgical centers. In awake patients, the diagnosis of recurrent hemorrhage usually is suggested by an acute deterioration in the patients' neurologic condition. However, during anesthesia, the clinical signs and symptoms of hemorrhage are masked. We report such a case when the diagnosis of a re-rupture was made using transcranial Doppler ultrasonography (TCD). In addition, the TCD was utilized to guide subsequent therapy and surgical management of the patient.

Case Report

A 53-year-old, 90-kg woman was transferred to the authors' medical center after suffering a subarachnoid hemorrhage from a basilar artery tip aneurysm. On arrival, the patient complained of a severe headache and was mildly lethargic, but had no focal neurologic signs and was following commands. She was classified as grade II on the Hunt and Hess scale (range I-V, with grade I describing a patient with headache only, and Grade V, a comatose patient).² She was treated with nimodipine, dexamethasone, famotidine, and codeine. Except for essential hypertension that was well controlled with verapamil and a

thiazide diuretic, she was otherwise healthy. While undergoing placement of a subclavian venous catheter in the neurosurgical intensive care unit, the patient suddenly became apneic along with complete loss of consciousness. A presumptive diagnosis of aneurysmal bleeding was made. The trachea was immediately intubated, the lungs were hyperventilated, and mannitol was administered to reduce intracranial pressure (ICP). A Camino[®] fiberoptic catheter (Camino Laboratory, San Diego, CA) was inserted into the right frontal region and the ICP was recorded at 70 mmHg. She was then brought to the operating room for emergent ventriculostomy under general anesthesia. The operation was uneventful and she began to improve postoperatively and was responsive to commands and moving all extremities by the next morning.

A decision was made to proceed with surgery for clipping of the aneurysm, and she was again brought to the operating room. Despite her inability to communicate verbally because of the endotracheal tube, she was responsive to commands, and there were no apparent focal neurologic deficits. An intra-arterial catheter and pulmonary artery catheter had been inserted previously. After attachment of standard monitors, anesthesia was induced with 0.5-1.0% isoflurane inspired in oxygen and 1.5 µg/kg fentanyl. Ten milligrams vecuronium was administered for neuromuscular blockade and subsequently given as needed. There were no changes in hemodynamic variables post-induction (blood pressure [BP] 130/70, heart rate [HR] 60-70 beats/min) compared to baseline. She was placed in the left lateral decubitus, and a lumbar subarachnoid drain was inserted without difficulty and with minimal loss of cerebrospinal fluid. She was then placed in the park bench position. The skin was infiltrated with 1% lidocaine prior to securing the pins on the head-holder, again without significant changes in hemodynamic variables (BP 120/70, HR 65 beats/min). The last ICP measurement was 7 mmHg prior to removal of the Camino[®] catheter.

As part of our routine protocol to examine changes in flow velocity pattern before and after aneurysm clipping, the major arteries of the Circle of Willis were insonated with a Transpect[®] transcranial Doppler (Medasonics, Fremont, CA). A normal flow pattern from insonation of the right middle cerebral artery was observed (fig. 1). Approximately 2 min after TCD recording was begun, there was an abrupt change in the velocity flow pattern to an oscillating flow pattern indicative of antegrade flow during systole and retrograde flow during diastole and consistent with a very high ICP. (fig. 2). It was suspected that she had suffered another rupture of the aneurysm. There were no indications from any hemodynamic monitoring. The drain from the ventriculostomy was transduced and the pressure was 120 mmHg, confirming the diagnosis of an intracranial hemorrhage.

Immediately before the oscillating pattern was observed on the TCD recording, an additional 100 µg fentanyl had been given and a decrease in HR from 80-90 beats/min to 50-60 beats/min was noted.

* Acting Instructor, Department of Anesthesiology.

† Professor, Department of Anesthesiology and Department of Neurosurgery

‡ Neurovascular technologist, Department of Neurosurgery.

§ Assistant Professor, Department of Neurosurgery.

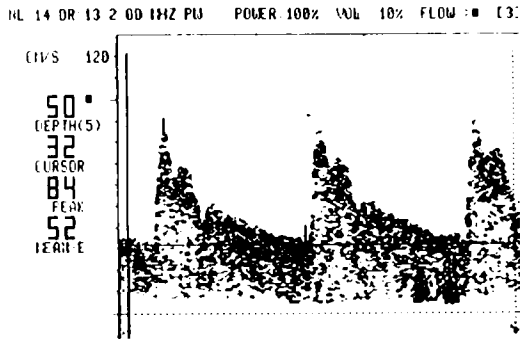
Received from the Departments of Anesthesiology and Neurosurgery, University of Washington, Harborview Medical Center, Seattle, Washington. Accepted for publication September 11, 1992.

Address reprint requests to Dr. Lam: Harborview Medical Center, Department of Anesthesiology, 325 Ninth Avenue, ZA-1, Seattle, Washington 98104.

Key words: Brain: blood flow velocity; intracranial pressure. Cerebral aneurysm: intracranial circulatory arrest; re-rupture. Measurement technique: transcranial Doppler ultrasonography.

CASE REPORTS

INITIAL PERIOPERATIVE TCD RECORDING (RMCA)



56 yr old white female, ruptured basilar tip aneurysm, rebleed 12 hr before. ICP 10-12 mmHg on arrival in OR. BP= 140/75

Fig. 1. The pre-rupture transcranial Doppler recording of the right middle cerebral artery flow velocity. This is a normal flow pattern (blood pressure 140/75, intracranial pressure 10-12 mmHg).

The decrease in HR was attributed to the fentanyl, since there was no significant change in BP (125/65).

Cerebral resuscitative therapy was immediately begun. Cerebral perfusion pressure (the difference between mean BP and ICP) was augmented by increasing systemic BP with an infusion of phenylephrine. Attempt to drain cerebrospinal fluid from the ventriculostomy catheter was not successful, probably because the ventricles were compressed by the high ICP. The lumbar subarachnoid drain was not used for fear of brainstem herniation. Intracranial pressure was decreased with the administration of thiopental (900 mg in divided increments), mannitol (150 g over 45 min), furosemide (10 mg), and hyperventilation (P_{aCO_2} reduced from 36 to 24 mmHg). With this treatment, the ICP decreased and the TCD signals slowly reverted toward a normal flow pattern (figs. 3 and 4). Approximately

Sudden development of retrograde diastolic flow ventricular catheter transduced - ICP= 120 mmHg

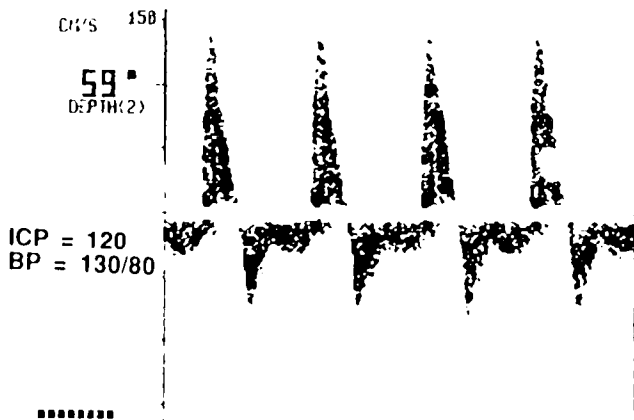


Fig. 2. The immediate post-rupture transcranial Doppler recording of the right middle cerebral artery flow velocity. This is an oscillating flow pattern with retrograde flow during diastole.

15 DR 20 2 00 1HZ PU POWER 100% VOL 3% FLOW 13

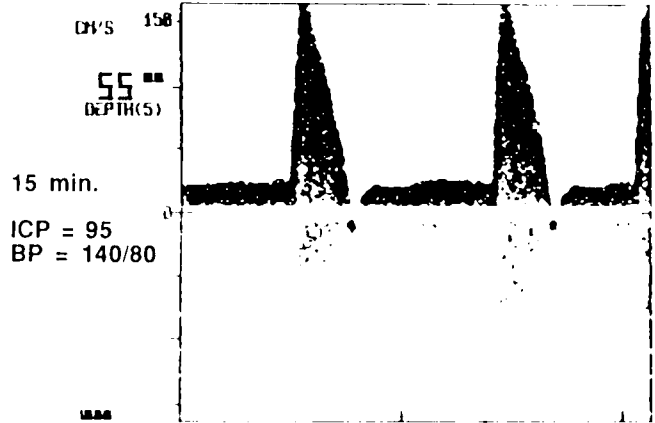


Fig. 3. The 15-min post-rupture transcranial Doppler recording of the right middle cerebral artery flow velocity. After treatment with mannitol, furosemide, and hyperventilation, a forward diastolic flow has reappeared.

24 min after the development of the oscillating flow, the ICP had decreased to 49 mmHg, and the velocity flow pattern was almost normal, although a high resistance pattern with low diastolic flow velocity was still apparent (fig. 5). Discussion between the attending anesthesiologist and surgeon then took place regarding the advisability of proceeding with surgery. We choose to proceed with the clipping because of the high likelihood of further hemorrhage with conservative management.

The surgical procedure was uneventful. Although there was evidence of a fresh hemorrhage, brain retraction was adequate for exposure and clipping of the aneurysm. The patient was returned to the neurosurgical intensive care unit for postoperative care. Over the next 15 days, she experienced intermittent vasospasm, as documented by TCD, and hydrocephalus. The vasospasm was treated

RL 15 DR 20 2 00 1HZ PU POWER 100% VOL 3% FLOW 13

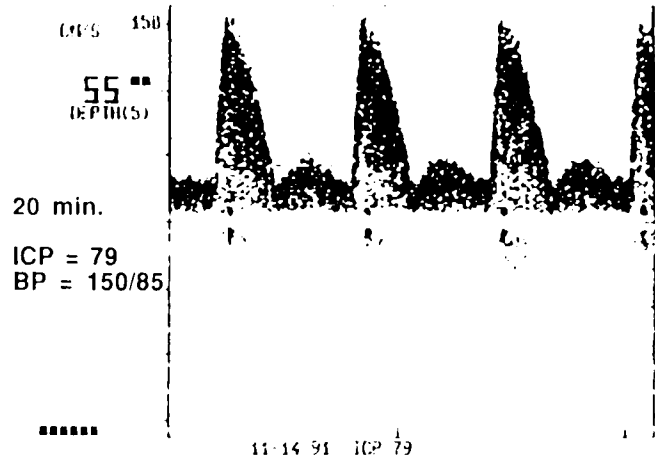


Fig. 4. The 20-min post-rupture transcranial Doppler recording of the right middle cerebral artery flow velocity. As the intracranial pressure continues to decrease, the diastolic flow component increases.

CASE REPORTS

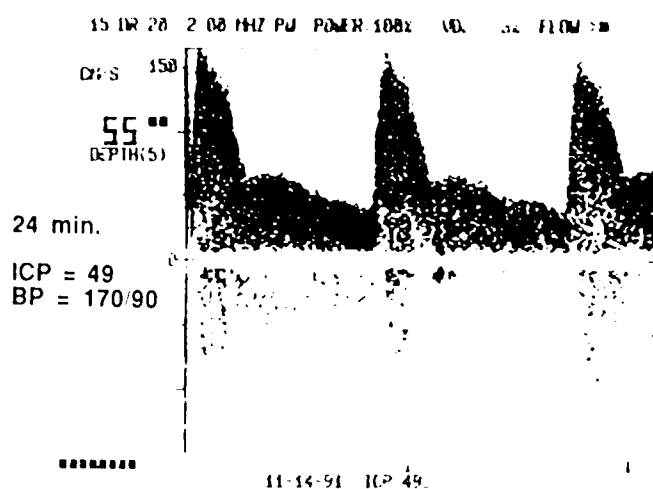


Fig. 5. The 24-min post-rupture transcranial Doppler recording of the right middle cerebral artery flow velocity. The flow velocity pattern is now almost normal.

with hypervolemic hypertension, and the hydrocephalus with repeated lumbar cerebrospinal fluid tap. Eventually a ventriculoperitoneal shunt was placed. After 1 month in the neurosurgical intensive care unit, she was transferred to the ward with a residual right third nerve palsy and decreased mental status; however, she was intermittently oriented and responsive to simple verbal communications.

Discussion

Transcranial Doppler was introduced by Aaslid in 1982³ and is now established as a useful diagnostic tool for the investigation of intracranial hemodynamics, management of vasospasm following subarachnoid hemorrhage, and confirmation of intracerebral circulatory arrest.^{4,5} Its potential as an intraoperative cerebral monitor remains to be explored. This case report demonstrates how the acute perioperative management of this patient was facilitated by TCD.

The acute changes in intracranial hemodynamics caused by a ruptured aneurysm have been described previously.⁴⁻⁷ The sudden increase in ICP increases cerebrovascular resistance and decreases cerebral perfusion if the systemic BP is not correspondingly increased. This is reflected in a highly pulsatile pattern on TCD with a normal or slightly decreased systolic velocity and a very low diastolic velocity. If the ICP is increased enough to cause intracranial circulatory arrest, a characteristic oscillating flow pattern (antero-

grade flow during systole and retrograde flow during diastole) with zero net forward flow is seen on the TCD.^{4,5} In the majority of the reported cases, the diagnosis was not made with the TCD as there were obvious clinical signs of neurologic deterioration, and the TCD was used simply to document the changes and/or assess the effects of therapy.

In an awake patient suffering a cerebral hemorrhage, the patient normally complains of a severe headache, focal neurologic signs develop, or the patient loses consciousness. What is unusual in our case is that the change on TCD was the first diagnostic sign of an acute hemorrhage as the patient was already anesthetized. The changes in cardiovascular signs were masked by the concurrent administration of opioids. Moreover, they were not specific enough to allow the diagnosis to be made. The evidence of a rupture by TCD was then confirmed by the high ICP recorded from the ventriculostomy.

In retrospect, the decrease in HR was more likely related to the response to the increased ICP^{||} than to the administration of fentanyl. A corresponding increase in BP was not observed at the time. Although this may have been due to anesthesia-induced suppression of sympathetic discharge, subsequent examination revealed that the arterial catheter was partially dampened and might have underestimated the actual BP. Had the TCD not been used, however, the diagnosis likely would not have been apparent until surgical incision had been made. Treatment would not have been instituted, the operating conditions would have been difficult, and clipping may have been impossible due to brain swelling.⁴ The precise time of the hemorrhage also could not have been determined.

The incidence of aneurysm rupture during the anesthetic induction period is low, and was reported to be 2% in one series in which the BP was not closely monitored and special precaution was not taken during laryngoscopy and tracheal intubation.⁸ Although there is no recently published data, with careful anesthetic techniques to prevent or minimize fluctuation in BP during intubation, positioning, and insertion of the head-pins, the incidence can be expected to be even lower. Moreover, the aneurysmal rupture in our patient was spontaneous and did not occur during the induction period as the trachea was already intubated prior to surgery and neither noxious stimulation nor fluctuation in BP occurred at the time of rupture. Therefore, the use of TCD as a routine diagnostic monitor specifically for aneurysm rupture during induction of anes-

^{||}Cushing H: Concerning a definite regulatory mechanism of the vasomotor centre which controls blood pressure during cerebral compression. *Bulletin of the Johns Hopkins Hospital* 12:290-292, 1901.

CASE REPORTS

thetia is not warranted. On the other hand, since the TCD is a noninvasive monitor with a low risk/benefit ratio, one can argue for its use whenever an acute aneurysmal hemorrhage is suspected.

Rupture of an aneurysm during induction of anesthesia is generally thought to increase the surgical morbidity and mortality.⁸ With an acutely swollen brain, unless the ICP can be controlled, clipping of the aneurysm may be technically difficult or impossible. This would mean either immediate cancellation of the surgical procedure and rescheduling if the patient survives, or proceeding with the prospect of a high surgical morbidity or mortality. The use of TCD in this case not only allowed the diagnosis of hemorrhage to be made, but also facilitated the difficult decision regarding timing of surgical intervention. The successful normalization of cerebral blood flow velocity (as documented with TCD from the oscillating flow pattern to a normal flow pattern with the administration of mannitol and induced hypertension) provided proof that the patient's condition had improved and that the operating condition was likely to be manageable.

The time course of the flow reversal also deserves some comment. The time elapsed from onset of oscillating flow pattern indicating intracerebral circulatory arrest to restoration of a normal flow pattern took approximately 24 min. Had intracranial circulatory arrest been present during this entire period, this duration would be in excess of what would be compatible with neurologic recovery. Fortunately the oscillating flow pattern was present only for approximately 10 min. Moreover, it is not possible to exactly pinpoint the time when intracerebral circulation was reestablished as

changes seen with the TCD were progressive and gradual during the recovery period. Presumably this occurred when the ICP decreased and an adequate perfusion pressure was restored. The mere presence of a positive perfusion pressure, of course, is no guarantee that perfusion exists, but the appearance of a net forward flow on TCD documents the presence of cerebral perfusion.⁴ The time course also provides confirmation that, if the oscillating flow pattern can be reversed promptly, then brain death need not be inevitable.

References

1. Kassell NF, Torner JC, Haley EC Jr, Jane JA, Adams HP, Kongable GL: The international cooperative study on the timing of aneurysm surgery: 1. Overall management results. *J Neurosurg* 73:18-36, 1990
2. Hunt WE, Hess RM: Surgical risk as related to time of intervention in the repair of intracranial aneurysms. *J Neurosurg* 28:14-20, 1968
3. Aaslid R, Markwalder TM, Nornes H: Noninvasive transcranial Doppler ultrasound recording of flow velocity in basal cerebral arteries. *J Neurosurg* 57:769-774, 1982
4. Hassler W, Steinmetz H, Gawlowske J: Transcranial Doppler ultrasonography in raised intracranial pressure and in intracranial circulatory arrest. *J Neurosurg* 68:745-751, 1988
5. Hassler W, Steinmetz H, Pirschel J: Transcranial Doppler study of intracranial circulatory arrest. *J Neurosurg* 71:195-201, 1989
6. Grote E, Hassler W: The critical first minutes after subarachnoid hemorrhage. *Neurosurgery* 22:654-661, 1988
7. Romner B, Ljunggren B, Brandt L, Saveland H: Transcranial Doppler sonography within 12 hours after subarachnoid hemorrhage. *J Neurosurg* 70:732-736, 1989
8. Tsementzis SA, Hitchcock ER: Outcome from "rescue clipping" of ruptured intracranial aneurysms during induction anaesthesia and endotracheal intubation. *J Neurol Neurosurg Psychiatry* 48:160-163, 1985