

## ■ CASE REPORTS

Anesthesiology  
78:361-363, 1993  
© 1993 American Society of Anesthesiologists, Inc.  
J. B. Lippincott Company, Philadelphia

### Dorsal Scapular Nerve Block: Description of Technique and Report of a Case

Kevin Haim, M.D.,\* Bruno J. Urban, M.D.†

ANESTHESIOLOGISTS working in pain clinics are occasionally asked to perform unusual nerve blocks. This report presents a case in which selective block of the dorsal scapular nerve was requested. We were unable to find a description for block of this nerve; however, upon reviewing the anatomy, we believed that it may be accessible for block.

#### Case Report

A 50-yr-old white man presented with an 18-month history of semirhythmic contractions of the left rhomboid muscle groups causing severe left thoracic discomfort. In 1989 he had undergone successful cervical laminectomy of C6-C7 for herniated nucleus pulposus. Later that year, while lifting wire at work, he suddenly experienced onset of new pain in the midthoracic spine radiating toward the left abdomen. A T7-T8 ruptured disc was diagnosed and discectomy/fusion was carried out without resolution of pain symptoms.

About 1 yr after this operation, the patient first noticed involuntary, semirhythmic, jerking movements of the left shoulder. These movements increased in frequency and severity and were finally present at all times when awake. Movements were associated with new pain that was localized to the left upper thoracic area and that the patient believed was distinctly different from his other pains. Treatment including nonsteroidal antiinflammatory drugs, muscle relaxants, benzodiazepines, Tegretol (Basel, Summit, NJ), Mysoline (Wyeth-Ayerst, Philadelphia, PA), antidepressants, and propranolol, physical therapy, local injections with anesthetics and steroids, and transcutaneous electrical nerve stimulation had been ineffective.

Physical examination revealed a muscular male in no acute distress. There were continuous rhythmic contractions of the left shoulder that seemed to originate and appeared to be confined to the rhomboid muscles. The remaining physical and neurologic examination results were within normal limits; specifically, no other abnormalities could be found when testing motor power and sensation.

Ancillary data consisted of normal x-rays and magnetic resonance imaging scans of the cervical and thoracic spine. Electromyograph

studies 2 months apart showed irregular firing of normal-appearing motor units within the rhomboid muscles in a bursting pattern at a rate of about 10 Hz. Electromyography examination results of other left periscapular, neck, and upper extremity muscles were normal; specifically, the abnormal firing pattern did not appear in any other C5 (or C6) innervated muscles.

The clinical impression of the neurology/neurosurgical members of the authors' pain clinic consisted of tremor/dystonia with pain restricted to the dorsal scapular nerve, probably of peripheral etiology.<sup>1</sup> They requested block of this nerve to confirm diagnosis and help with defining therapy.

The dorsal scapular nerve, a dorsal branch of the brachial plexus, is derived mostly from C5 but may have contributions from adjacent spinal segments. It is purely motor in function, serving the rhomboid muscles and, partially, the levator scapulae muscle. The nerve pierces the middle scalene muscle, traveling caudad either within its belly or on its posterior surface to the inferior part of the levator scapulae muscle, which it follows close to the superior angle of the scapula. It then courses parallel to the medial margin of the scapula on the inner surface of the rhomboid muscles (fig. 1).<sup>2</sup> There appear to be two possible approaches for the block: an anterolateral approach during its course within the middle scalene muscle or a posterior approach close to the levator scapulae muscle before descending beneath the rhomboids. In the absence of firm landmarks, either approach must depend on a nerve stimulator for exact localization.<sup>3</sup>

We attempted the dorsal scapular nerve block on three occasions. Initially, we approached the nerve *via* an anterolateral approach. A local anesthetic wheal was raised at the apex of the lateral triangle of the neck (between sternocleidomastoid and trapezius muscle at about the C5-C6 vertebral level). The middle scalene muscle was palpated. A 22-G insulated needle was inserted through the skin wheal into this muscle and advanced in an inward, downward, and backward direction with a nerve stimulator attached. Rhomboid muscle contraction synchronous with stimulation signaled the needle tip's proximity to the dorsal scapular nerve; stimulation did not produce a local motor response. The needle position was adjusted for maximal motor response from minimal stimulation intensity, and 4 ml 1.5% lidocaine was injected. Within 15 min the patient experienced an estimated 75% decrease in intensity of semirhythmic contractions and pain.

The block was repeated 1 week later utilizing identical technique but injecting 2 ml 2% lidocaine and 5 ml 1.5% etidocaine with epinephrine 1:200,000. Within 15 min the patient experienced a 100% reduction in muscle contractions and pain. However, he also experienced decreased sensation and motor weakness in the C6 distribution, indicating spillover of the anesthetic solution to the C6 nerve or brachial plexus.

One day later, block was repeated using the posterior approach. The rhomboids were palpated. In our lean patient, a groove could be felt cranial to these muscles between the splenius capitis and levator scapulae muscle. An insulated 22-G needle was inserted

\* Resident.

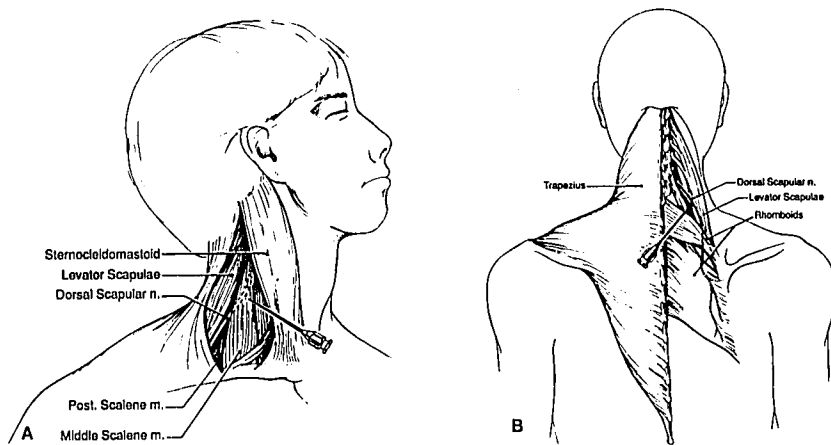
† Professor.

Received from the Department of Anesthesiology, Duke University Medical Center, Durham, North Carolina. Accepted for publication October 13, 1992.

Address reprint requests to Dr. Urban: Department of Anesthesiology, Box 3094, Duke University Medical Center, Durham, North Carolina 27710.

Key words: Anesthesia technique: dorsal scapular nerve block.

## CASE REPORTS



**Fig. 1.** Course of dorsal scapular nerve. *A:* View from the side. *B:* View from the back. Needles indicate possible site for blocking the nerve.

through a local anesthetic wheal into this groove. With the nerve stimulator connected, the needle was advanced through the trapezius muscle with a slightly outward direction toward the levator scapulae muscle. Synchronous contractions of both rhomboids occurred when the needle approached the latter muscle, indicating proximity of the tip to the dorsal scapular nerve. Needle position was fine-adjusted for maximal motor response with minimal stimulation intensity and 8 ml 2% lidocaine was injected. After 15 min the patient experienced an estimated 75% reduction in severity of semirhythmic contraction and in pain.

Results of blocks were interpreted as confirmatory to the clinical impression of tremor/dystonia of the dorsal scapular nerve producing pain.<sup>1</sup> Treatment with botulinus toxin was elected and 100 U was injected into the rhomboid muscles.<sup>4</sup> This resulted in short-lived (about 3 weeks) 50% reduction of involuntary movements and little change in pain. Repeat electromyographs demonstrated spread of rhythmic activity to the levator scapulae and trapezius muscle suggesting a more central etiology of symptoms.

## Discussion

Absence of an established technique to block a nerve should not present an obstacle or a reason to deny an indicated procedure. In our case, review of anatomy indicated two possible sites at which the dorsal scapular nerve could be approached. Utilizing standard technique with a nerve stimulator, we were successful in localizing the nerve at either site, as evidenced by stimulation-produced motor response in the rhomboid muscles and weakness following local anesthetic injection. We may have succeeded even without the aid of a stimulator by injecting larger amounts of the local anesthetic. However, stimulation added additional confirmation, and larger volumes of anesthetic solution are more apt to cause spillover affecting other nerves (e.g., during second block).

Our patient was thought to suffer tremor/dystonia associated with pain, which was believed to originate within a peripheral nerve, although subsequent spread to other muscles later suggested a more central etiology.<sup>1</sup> Block of the dorsal scapular nerve was performed to differentiate whether rhythmic contractions produced the patient's new pain or whether this pain was independent of movements, and thus, part of his chronic pain syndrome. All three blocks resulted in an estimated reduction of pain proportional to the observed decrease in rhomboid contractions.

Therapeutic considerations included botulinus toxin injection or surgical section or chemical or physical (freezing) neurolysis of the dorsal scapular nerve. We decided against surgical section or permanent neurolysis because these procedures would produce an irreparable deficit. Furthermore, other pains may be created by subsequent atrophy of the rhomboid muscles. Chemical neurolysis carried the additional risk of spillover to adjacent nerves with unwelcome numbness or weakness. Even with stimulation, we did not believe we could localize the dorsal scapular nerve with enough accuracy to ensure the needle tip resting in or on it to produce lasting results from only small amounts of neurolytic agent or from freezing. To perform either procedure accurately, the nerve probably should be surgically visualized and the cold probe or needle applied under direct vision.

Injection of botulinus toxin was chosen for treatment.<sup>4</sup> This has been shown to be effective in producing muscle weakness resulting in successful therapy of movement disorders. It was hoped that it would, in addition, alleviate pain in our patient. Unfortunately,

## CASE REPORTS

the toxin resulted in very short-lived reduction in movements only and in no change in pain. It is possible that nerve blocks may have little prognostic value for intramuscular botulinus toxin injection, similar to the poor correlation reported for nerve blocks and the long-term outcome of dorsal rhizotomy.<sup>5</sup> We had blocked the dorsal scapular nerve on three occasions, and each time pain decreased proportional to rhomboid paresis. Nevertheless, prolonged weakness of these muscles from botulinus toxin did not result in a similar reduction in pain.

Anesthesiology  
78:363-364, 1993  
© 1993 American Society of Anesthesiologists, Inc.  
J. B. Lippincott Company, Philadelphia

## False Desaturation Due to Intradermal Patent Blue Dye

Robert C. Morell, M.D.,\* Theodore Heyneker, M.D.,\* Hillel I. Kashtan, M.D.,\* Charlie Ruppe, CRNA†

THE intravenous administration of dye has been reported to falsely decrease oxygen saturation as determined by pulse oximetry.<sup>1,2</sup> We now report the first case of spurious desaturation due to a small *intradermal* injection of patent blue dye. The recent publication of a new surgical technique for intraoperative lymphatic mapping of early stage melanoma describes the intradermal injection of small aliquots of patent blue dye. This allows mapping of the lymphatic drainage of a malignant melanoma and the identification of a "sentinel node" indicating lymphatic spread of the disease. Morton *et al.* reported this technique and successfully utilized it to identify a sentinel node in 194 of 237 patients.<sup>3</sup> The first use of this technique at our

## References

1. Jankovic J, Van der Linden C: Dystonia and tremor induced by peripheral trauma. *J Neurol Neurosurg Psychiatry* 51:1512-1519, 1988
2. Gray's Anatomy of the Human Body. 29th American edition. Edited by Goss CM. Malvern, PA, Lea and Febiger, 1973, p 963
3. Raj PP, Rozenblat R, Montgomery SJ: Use of the nerve stimulator for peripheral blocks. *Reg Anesth* 5:14-21, 1980
4. Jankovic J, Brin MF: Therapeutic uses of botulinum toxin. *N Engl J Med* 324:1186-1194, 1991
5. Loeser JD: Dorsal rhizotomy for the relief of chronic pain. *J Neurosurg* 36:745-750, 1972

institution resulted in a delayed and marked decrease in oxygen saturation as determined by pulse oximetry.

### Case Report

A 54-yr-old, 80.8-kg, 157.5-cm tall woman was scheduled for excision of a malignant melanoma from her right arm. Lymphatic mapping and identification of a sentinel node also was planned. Her medical history included a subtotal thyroidectomy, knee surgery, and mild hypertension. She was allergic to penicillin. Her only medication was levothyroxine, 0.125 mg/day. Physical examination revealed a mildly obese female with a Mallampati class I airway. Laboratory studies were unremarkable. Monitoring included electrocardiogram (leads II and V<sub>5</sub>), automated blood pressure cuff, precordial stethoscope, pulse oximetry, capnography, and end tidal gas analysis.

A Nellcor N-100 pulse oximeter (Hayward, CA) with an Oxisensor D-25 oxygen transducer was placed on the index finger of the hand contralateral to the surgical side. Her room air hemoglobin oxygen saturation (SpO<sub>2</sub>) prior to the induction of anesthesia was 100%. Following premedication with 2 mg intravenous midazolam, anesthesia was induced with 250 mg sodium pentothal and 250 µg fentanyl. Neuromuscular relaxation was obtained with 10 mg vecuronium. Tracheal intubation was accomplished without difficulty following the administration of 160 mg 4% laryngotracheal lidocaine.

Following intubation, anesthesia was maintained with isoflurane, 50% N<sub>2</sub>O, 50% oxygen, with supplemental fentanyl administered incrementally to a total of 450 µg. The lungs were ventilated with an 800-ml tidal volume at a frequency of 6 breaths/min. Prior to administration of the patent blue dye, the SpO<sub>2</sub> was 99-100%. Intraoperatively, 1.5 ml 10% patent blue dye (compounded by our hos-

\* Assistant Professor of Anesthesia.

† Certified Registered Nurse Anesthetist.

Received from the Department of Anesthesia, Bowman Gray School of Medicine of Wake Forest University, Winston-Salem, North Carolina. Accepted for publication October 13, 1992.

Address reprint requests to Dr. Morell: Department of Anesthesia, Wake Forest University Medical Center, Medical Center Boulevard, Winston-Salem, North Carolina 27157-1009.

Key words: Measurement technique: Pulse oximetry. Patent blue dye.