

## CORRESPONDENCE

**Table 1. Incidence of Myocardial Ischemia Detected by Electrocardiography (ECG) Alone, Echocardiography Alone (Precordial or Transesophageal) or ECG or Echocardiography in the Different Intraoperative Periods**

Event	ECG		P*	Echocardiography		P	ECG or Echocardiography	
	Desflurane	Sufentanil		Desflurane	Sufentanil		Desflurane	Sufentanil
Induction (+ intubation)	9/99	0/98	.003	5/39	0/29	.067	14	0
Induction (- intubation)	6/99	0/98	.023	4/39	0/29	.13	10	0
Incision	3/99	1/98	.6	6/91	2/84	.3	9	3
Maintenance (- induction)	7/99	3/98	.3	15/91	6/84	.07	19	7
Maintenance (+ induction)	12/99	3/98	.03	20/91	6/84	.01	28	7
<i>De novo</i> maintenance + induction	8/99	1/98	.04					

*De novo* refers to those patients who developed new intraoperative ischemia without the occurrence of preoperative ischemia.

\* Fisher's exact test.

for more echocardiographic ischemia (16%) in the desflurane group than in the sufentanil group (7%). We calculated the relative risk to be 2.3 (95% confidence interval 0.9–5.7). On further analysis of the ischemic data, it appears that we even may have underestimated the risk of myocardial ischemia under desflurane anesthesia if we combined the induction with the prebypass periods, or combined the electrocardiogram with the echocardiographic ischemic episodes (table 1). We took a conservative approach in the original analysis, *i.e.*, to separately analyze electrocardiographic and echocardiographic data, because it is not clear whether the true incidence of myocardial ischemia is the sum of the two. Nevertheless, these additional analyses further substantiate our conclusion that "further studies are necessary to investigate the induction and maintenance effects of desflurane in the at-risk patient undergoing noncardiac surgery" because extrapolation of the present data in the cardiac surgical patients to the noncardiac surgical patients is not warranted. Finally, and most importantly, why desflurane has a propensity to cause tachycardia and systemic and pulmonary hypertension remains unresolved. The mechanism of these changes and whether these effects can be blunted by adjunctive agents should be addressed by further studies.

Anesthesiology  
78:398–399, 1993  
© 1993 American Society of Anesthesiologists, Inc.  
J. B. Lippincott Company, Philadelphia

**James D. Helman, M.D.**  
**Jacqueline M. Leung, M.D.**  
**Wayne H. Bellows, M.D.**  
**Dennis T. Mangano, Ph.D., M.D.**  
Department of Anesthesia  
University of California, San Francisco,  
School of Medicine and Anesthesiology Service (129)  
Veterans Administration Medical Center  
4150 Clement Street  
San Francisco, California 94121

## Reference

1. Leung JM, O'Kelly B, Browner WAS, Tubau J, Hollenberg M, Mangano DT, SPI Research Group: Prognostic importance of post-bypass regional wall-motion abnormalities in patients undergoing coronary artery bypass graft surgery. *ANESTHESIOLOGY* 71:16–25, 1989

(Accepted for publication November 5, 1992.)

## Perioperative Dislocation in a Patient with a Prosthetic Hip

*To the Editor:*—Hip dislocation is a known postoperative complication following total hip arthroplasty (THA). We present a case of dislocation 3 weeks following THA during the administration of a spinal anesthetic.

A 77-yr-old physician was scheduled for a transurethral resection of the prostate. His past surgery included bilateral THA with revision of the left hip prosthesis 3 weeks earlier.

He requested a spinal anesthetic and was placed in the sitting position with legs together, knees bent, and feet resting on a chair. He was assisted in leaning forward with his arms supported in front

of him. During insertion of the spinal needle *via* a midline approach, he complained of sharp pain, which he described as "2 to 3 centimeters inferior and lateral to the puncture site." On physical examination, the patient had a noticeable deformity of the left hip. The orthopedics service was consulted, and radiographs of the left hip demonstrated posterior dislocation.

General anesthesia was induced, as requested by the patient, and the dislocation was reduced manually without difficulty; the prostatic resection proceeded under the same general anesthetic without complications.

## CORRESPONDENCE

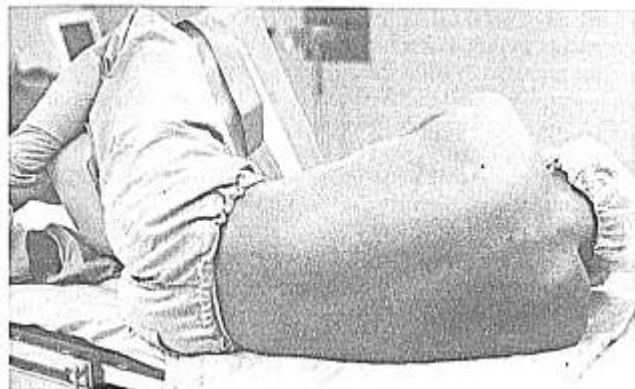


Fig. 1. Suggested regional anesthesia positioning for a patient at risk for dislocation following total hip arthroplasty.

Total hip arthroplasty has become a common reconstructive hip procedure.<sup>1</sup> It is likely that an increasing number of patients with hip prostheses will return to the operating room for other procedures, and simple positioning maneuvers may potentially decrease the incidence of complications such as that described above.

The incidence of hip dislocation following primary THA is approximately 3%,<sup>2</sup> with the greatest risk in the 3 months following operation.<sup>3</sup> Previous hip surgery is an additional risk factor for dislocation following THA; in this setting, the risk of dislocation is approximately 20%.<sup>4</sup> Other factors include medical disorders that produce mental confusion or muscle weakness, concurrent neurologic disease, or faulty positioning of the arthroplastic components.<sup>5</sup> Placing the hip in a position of extreme flexion, internal rotation, and adduction increases the risk of dislocation.<sup>1</sup> For this reason, following THA, a triangular pillow wedge or abduction splint is placed between the thighs to keep the hips abducted and neutrally rotated. The physical activity required to dislocate the hip following THA may be minor, such as rolling over in bed or tying one's shoes. Although the amount of trauma associated with dislocation of the hip following THA is usually minor, most patients will recognize immediately that something is wrong with the hip once dislocated. The vast majority of postoperative hip dislocations can be treated with closed reduction.<sup>6</sup>

The risk factors for hip dislocation in our patient included THA within the past 3 months and previous hip surgery. His hip instability was exacerbated by positioning for his spinal anesthetic, which included hip flexion, adduction, and possibly internal rotation.

Anesthesiology  
78:399-400, 1993  
© 1993 American Society of Anesthesiologists, Inc.  
J. B. Lippincott Company, Philadelphia

## Prevention of Awareness during Total Intravenous Anesthesia

*To the Editor:*—Kelly and Roy<sup>1</sup> recently reported a case of awareness during the administration of propofol as the sole anesthetic. Based upon my understanding of the pharmacokinetic and pharma-

As a result of our experience, we believe special caution should be used in regional anesthesia positioning for patients at risk for dislocation following THA. Because these patients may not fully understand the implications of positioning, it is the anesthesiologist's responsibility to protect the unstable hip in this setting. The advantage of spinal and epidural anesthetics administered to patients in the lateral position with minimal flexion of the back, the prosthetic hip nondependent, and an abduction splint or pillow placed between the thighs should be considered (fig. 1). The use of a knee immobilizer also prevents flexion, adduction, and internal rotation by holding the knee in extension.<sup>7</sup> We suggest that these simple maneuvers may decrease the risk of dislocation in patients who have had recent hip arthroplasty.

The authors are indebted to Dr. Nasim Rana, Department of Orthopedics, for his suggestions and review of the manuscript.

Paul Samuels, M.D.  
Resident in Anesthesia  
Carolyn Brent, M.D.  
Associate Professor of Anesthesia  
Department of Anesthesia  
Northwestern University, The Medical School  
303 East Superior Street, Room 360  
Chicago, Illinois 60611

### References

1. Harkess JW: Arthroplasty of the hip, Campbell's Operative Orthopaedics. Edited by Crenshaw AH. St. Louis, CV Mosby, 1992, pp 442-541
2. Lewennek GE, Lewis JL, Tarr R, Compere CL, Zimmerman JR: Dislocations after total hip replacement arthroplasties. *J Bone Joint Surg* 60A:217-220, 1978
3. Coventry MB, Bechenbaugh RD, Nolan DR, Ilstrum DM: Two thousand twelve total hip arthroplasties: A study of postoperative course and early complications. *J Bone Joint Surg* 56A:273-284, 1974
4. Fackler CD, Poss R: Dislocation in total hip arthroplasties. *Clin Orthop* 151:169-178, 1980
5. Khan MA, Brakenbury PH, Reynolds ISR: Dislocation following total hip arthroplasty. *J Bone Joint Surg* 63B:214-218, 1981
6. Woo YG, Morrey BF: Dislocations after total hip arthroplasty. *J Bone Joint Surg* 64A:1295-1306, 1986
7. Rao JP, Bronstein R: Dislocations following arthroplasties of the hip: Incidence, prevention and treatment. *Orthop Rev* 20:261-264, 1991

(Accepted for publication November 5, 1992.)

dynamic concepts related to intravenous anesthesia,<sup>2-6</sup> it is not surprising that this patient was aware during the surgical procedure. Simulating the dosing profile administered by Kelly and Roy<sup>1</sup> would