

CASE REPORTS

20. Cohen Y, Chang LH, Litt L, Kim F, Severinghaus JW, Weinstein PR, Davis RL, Germano I, James TL: Stability of brain intracellular lactate and ^{31}P -metabolite levels at reduced intracellular pH during prolonged hypercapnia in rats. *J Cereb Blood Flow Metab* 10:277–284, 1990

21. Prys-Roberts C, Smith WD, Nunn JF: Accidental severe hypercapnia during anaesthesia: A case report and review of some physiological effects. *Br J Anaesth* 39:257–267, 1967

22. Frumin J, Epstein RM, Cohen G: Apneic oxygenation in man. *ANESTHESIOLOGY* 20:789–797, 1959

Anesthesiology
78:1181–1184, 1993
© 1993 American Society of Anesthesiologists, Inc.
J. B. Lippincott Company, Philadelphia

Prolonged Neuromuscular Block Following Mivacurium

V. R. Maddineni, M.D., F.F.A.R.C.S.I.,* R. K. Mirakhur, M.D., Ph.D.†

MIVACURIUM chloride is a new short-acting nondepolarizing neuromuscular blocking agent that undergoes hydrolysis by plasma cholinesterase.^{1,2} The rate of hydrolysis of mivacurium *in vitro*, as catalyzed by purified human plasma cholinesterase, is between 70% and 88% of the rate of succinylcholine. We report a case of prolonged neuromuscular block in a young, healthy patient who presented for elective surgery.

Case Report

A 22-year-old woman was admitted for extraction of impacted wisdom teeth. Medical history was not significant except for polycystic ovarian disease. The patient was taking oral contraception containing 150 μg desogestrel and 30 μg ethinyl estradiol (Marvelon, Organon, Cambridge, UK) for the previous 12 months. She had no known allergies. There was no known history of significant illness in the family, and neither the patient nor anyone in her immediate family had any experience of anesthesia. The patient was 146 cm tall and weighed 54 kg, and physical examination revealed no abnormal physical findings. Results of preoperative routine biochemistry and hematology investigations were normal.

The patient was premedicated with 20 mg temazepam and was anesthetized with 250 mg thiopental, 0.1 mg fentanyl, and 66% ni-

trous oxide in oxygen until intubating conditions were assessed, after which 0.5–0.75% halothane was added to the inspired gas mixture. Monitoring consisted of electrocardiogram, noninvasive blood pressure, oxygen saturation, end-tidal carbon dioxide concentration, and temperature. Monitoring of the neuromuscular block was carried out by transcutaneous stimulation of ulnar nerve at the wrist with supramaximal stimuli in a train-of-four (TOF) mode at 2 Hz every 12 s. The resultant force of contraction of adductor pollicis muscle was measured and recorded using a force transducer and a neuromuscular function analyzer (Myograph 2000, BioMeter, Denmark). The detailed neuromuscular monitoring was carried out because the patient was in a study assessing the clinical effects of mivacurium, which at this stage is not licensed for general use in the United Kingdom.

After stabilization of control responses over 5 min, 11 mg (0.2 mg/kg) mivacurium was administered over 10 s. The first measurable effect (lag time) and complete neuromuscular block (onset time) developed in 34 and 90 s, respectively (fig. 1). Tracheal intubation was carried out 2.5 min after mivacurium administration, and the conditions were excellent. No signs of recovery were observed in the neuromuscular function at the usual expected time of about 20–25 min. The surgery lasted 70 min, but there was still no measurable degree of recovery. The patient was kept anesthetized, and monitoring of the neuromuscular block continued.

The first signs of recovery from neuromuscular block were observed 235 min after the initial administration of mivacurium. The rate of recovery was very slow, taking 7 min for the first response in TOF (T1) to recover from 5–6% of control. It was decided that neostigmine be administered to hasten the recovery. Accordingly, 2.5 mg neostigmine with 0.5 mg glycopyrrolate was administered 242 min after the first administration of mivacurium, when the T1 had attained a height of 6%. The T1 increased to 25% and 50% in 1.7 and 4.3 min, respectively, and to a maximum height of 68% in 8.0 min, after which no further recovery was observed. The maximum TOF ratio attained was 0.34 in 11 min. The patient started to breathe spontaneously at this stage.

Fifteen minutes after the initial administration of neostigmine, another dose of 1.25 mg neostigmine with 0.25 mg glycopyrrolate was administered. The T1 recovered to 80% of its control height 9 min after the second dose of neostigmine. The TOF ratio reached a maximum of 0.45 another 3 min later, when no further recovery was

* Research Fellow.

† Senior Lecturer.

Received from the Department of Anaesthesia, Queen's University of Belfast, Ireland, United Kingdom. Accepted for publication February 16, 1993.

Address reprint requests to Dr. Mirakhur: Department of Anaesthesia, The Queen's University of Belfast, Whitla Medical Building, 97 Lisburn Road, Belfast BT9 7BL, Ireland, United Kingdom.

Key words: Metabolism: mivacurium, plasma cholinesterase. Neuromuscular block: prolonged. Neuromuscular relaxants: mivacurium.

CASE REPORTS

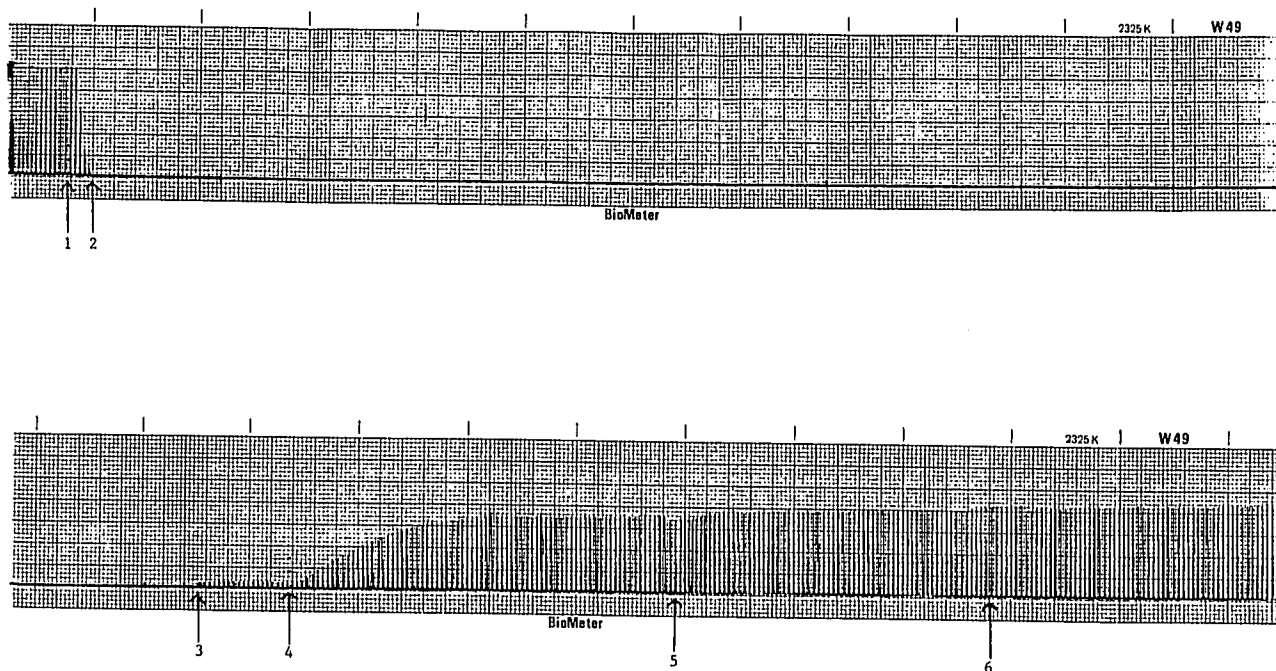


Fig. 1. Mechanomyographic recording of the adductor pollicis muscle. 1 = administration of mivacurium; 2 = onset of complete block; 3 = first return of twitch; 4 = administration of the first dose of neostigmine; 5 = administration of the second dose of neostigmine; 6 = attainment of maximum recovery. The paper is running at 0.1 mm/s throughout the process of recording except that the recording (and not the monitoring) was interrupted for a long period during which there was no response.

observed. A tetanic stimulus at 50 Hz for 5 s at this stage, however, showed only a minimal degree of fade. The spontaneous breathing continued to improve, and within 10 min the patient was able to maintain a normal end-tidal carbon dioxide concentration.

Although the TOF ratio had not returned to the usually accepted level of 0.7, the trachea was extubated because the patient was breathing adequately, as shown by end-tidal carbon dioxide concentration of 4.9–5.4%, and was becoming restless. After tracheal extubation and awakening, the patient was able to sustain a head-lift and cough effectively. She was observed in the postoperative recovery ward over the next hour and later was discharged to her own ward. She made an uneventful recovery and was discharged home the following morning according to the usual routine of the surgical unit. Her only complaint was of a moderately sore throat.

The plasma cholinesterase activity and dibucaine number of a blood sample were found to be very low. The sample of plasma was forwarded to the Cholinesterase Research Unit at the Hammersmith Hospital, London, for genotyping. Plasma cholinesterase activity was measured colorimetrically using benzoylcholine as the substrate. Genotyping was done using differential inhibition of the enzyme by dibucaine, fluoride, and RO-20683 (a specific cholinesterase inhib-

itor). The results are given in table 1 and show a low plasma cholinesterase activity consistent with an abnormal genotype.

Discussion

Since mivacurium is metabolized primarily by plasma cholinesterase, it is likely that an occasional case of prolonged apnea will be encountered. A recent case report described how no response was observed to peripheral nerve stimulation for 3.5 h after administration of 0.12 mg/kg mivacurium in a 12-yr-old patient subsequently shown to have homozygous atypical plasma cholinesterase.³ The quantification of TOF ratios was not undertaken in this patient.

An inverse correlation has been noted between plasma cholinesterase activity and duration of action of mivacurium in patients with normal plasma cholinesterase phenotype.⁴ In patients heterozygous for the atypical gene, mivacurium-induced neuromuscular block has been found to be prolonged by approximately 50%.[‡] Ostergaard *et al.*⁵ have reported that, in patients homozygous for the atypical plasma cholinesterase gene, a small dose of mivacurium (0.03 mg/kg, ED₁₀) resulted in a prolonged block with a mean time to reap-

‡ Ostergaard D, Jensen FS, Jensen E, Viby-Mogensen J: Mivacurium induced neuromuscular blockade (NMB) in patients heterozygous for the atypical gene for plasma cholinesterase (abstract). *ANESTHESIOLOGY* 71:A782, 1989.

CASE REPORTS

Table 1. Laboratory Investigations

Plasma cholinesterase activity	29 units (normal 80–120)
Dibucaine number	20 (normal 77–83)
Fluoride number	29 (normal 57–68)
Genotype	E ₁ ^a E ₁ ^b

pearance of T1 of 62 min (range 26–128 min). Considering this, it is not surprising or unexpected that a dose of 0.2 mg/kg (approximately 2.9 × ED₉₅) in a homozygous atypical individual produced a block in which T1 reappeared only after 235 min. Patients with similar dibucaine and fluoride numbers and genetic makeup are known to be sensitive to the effects of succinylcholine.^{6–8} It would be anticipated that the sensitivity to mivacurium would be greater since mivacurium is metabolized at a slower rate than succinylcholine. The prolonged recovery period of about 4 h in our patient is thus consistent with what one would expect in this situation.

Oral contraceptives containing estrogen have been reported to decrease plasma cholinesterase activity by about 20%.⁹ Whether this decrease is a dose-related phenomenon is not known. The patients in the study by Robertson⁹ were taking contraceptive pills containing 50 µg ethinyl estradiol, whereas in the present case, the patient was taking the contraceptive pill containing 30 µg ethinyl estradiol. Hence, the prolonged apnea with mivacurium in this patient is unlikely to have been due to a reduction in the plasma cholinesterase activity due to the estrogen-containing contraceptive pill. Moreover there needs to be much greater reduction than 20% in plasma cholinesterase activity to give a prolonged response to agents such as succinylcholine¹⁰ and possibly mivacurium. Genotyping, in any case, showed this not be the reason.

There is no doubt that the patient described here will be sensitive to succinylcholine administration as well. However, mivacurium has the advantage of being a competitive muscle relaxant—its effects can be antagonized by anticholinesterase agents. This was achieved in our case to a certain extent. The slow recovery after administration of neostigmine is expected when one considers that antagonism was attempted at a profound degree of block. It might, in retrospect, have been preferable to let further spontaneous recovery take place and then to consider pharmacologic antagonism. It could be argued that edrophonium may be preferable because of the minimal inhibition of plasma cholin-

esterase activity associated with it.¹¹ However, it is well known that edrophonium is less effective than neostigmine in the antagonism of profound blocks. It is worth noting that in the case reported by Peterson *et al.*, neither neostigmine nor edrophonium were able to effectively antagonize the prolonged mivacurium-induced block.³ It is clearly prudent to administer antagonists including neostigmine at a greater degree of spontaneous recovery in such patients as reported here.

Screening of all patients for abnormal plasma cholinesterase is expensive, time-consuming, and disproportionate to the fact that clinically significant prolonged apnea occurs with a frequency of 1 in 2,500 cases.¹² About 65% of all cases of prolonged apnea probably are due to inherited variants of serum cholinesterase.¹³ In a study reported from Denmark, 46.7% of inherited variants were homozygous for the atypical enzyme, and 5.4% heterozygous for atypical and silent gene.⁷

Heterozygous occurrence of the silent gene normally can be demonstrated with certainty only by means of extensive family studies, since the results of different inhibition reactions are identical for E₁^aE₁^a and E₁^aE₁^s.⁷ The final genotype of our patient, whether heterozygous for atypical and silent gene or homozygous for atypical gene, probably will be resolved after investigating the family members.

In summary, we report a case of prolonged neuromuscular block following administration of mivacurium in a patient with low plasma cholinesterase activity and subsequent confirmation of having a genetically abnormal variant of the enzyme.

The authors are grateful to the Cholinesterase Research Unit at the Hammersmith Hospital, London, for plasma cholinesterase measurement and genotyping. Mivacurium used in the current study was provided by the Wellcome Foundation, Crewe, United Kingdom.

References

1. Savarese JJ, Ali HH, Basta SJ, Embree PB, Scott RPF, Sunder N, Weakly JN, Wastila WB, El-Sayad HA: The clinical neuromuscular pharmacology of mivacurium chloride (BW B1090U): A short-acting nondepolarizing ester neuromuscular blocking drug. *ANESTHESIOLOGY* 68:723–732, 1988
2. Cook DR, Stiller RL, Weakly JN, Chakravorti S, Brandom BW, Welch RM: In vitro metabolism of mivacurium chloride (BW B1090U) and succinylcholine. *Anesth Analg* 68:452–456, 1989
3. Petersen RS, Bailey PL, Kalameghan R, Ashwood ER: Prolonged neuromuscular block after mivacurium. *Anesth Analg* 76:194–196, 1993
4. Ostergaard D, Jensen FS, Jensen E, Skovgaard LT, Viby-Mogensen

CASE REPORTS

J: Influence of plasma cholinesterase activity on recovery from mivacurium induced neuromuscular blockade in phenotypically normal patients. *Acta Anaesthesiol Scand* 36:702-706, 1992

5. Ostergaard D, Jensen E, Jensen FS, Viby-Mogensen J: The duration of action of mivacurium-induced neuromuscular block in patients homozygous for the atypical plasma cholinesterase gene (abstract). *ANESTHESIOLOGY* 75:A774, 1991

6. Lehmann H, Liddell J: Human cholinesterase (pseudocholinesterase): Genetic variants and their recognition. *Br J Anaesth* 41: 235-244, 1969

7. Viby-Mogensen J, Hanel HK: Prolonged apnoea after suxamethonium: An analysis of the first 225 cases reported to the Danish cholinesterase research unit. *Acta Anaesthesiol Scand* 22:371-380, 1978

8. Whittaker M: Plasma cholinesterase variants and the anaesthetist. *Anaesthesia* 35:174-197, 1980

9. Robertson GS: Serum protein and plasma cholinesterase changes in association with contraceptive pills. *Lancet* 1:232-235, 1967

10. Vickers MD: The cholinesterases and their significance to the anaesthetist using muscle relaxants. *Anaesthesia* 35:528-534, 1963

11. Mirakhur RK: Edrophonium and plasma cholinesterase activity. *Can J Anaesth* 33:588-590, 1986

12. Viby-Mogensen J, Hanel HK: A Danish cholinesterase research unit. *Acta Anaesthesiol Scand* 21:405-412, 1977

13. Whittaker M, Vickers MD: Initial experiences with the cholinesterase research unit. *Br J Anaesth* 42:1016-1020, 1970

Anesthesiology
78:1184-1186, 1993
© 1993 American Society of Anesthesiologists, Inc.
J. B. Lippincott Company, Philadelphia

Cervical Epidural Block Can Relieve Postoperative Intractable Hiccups

Shigehito Sato, M.D.,* Nobuaki Asakura, M.D.,† Takuo Endo, M.D.,† Hiroshi Naito, M.D., Ph.D.‡

PERSISTENT hiccups after abdominal surgery are stressful for patients. While a variety of treatments for hiccups have been reported,¹⁻³ no "cure" stands out as the most effective. We describe two patients in whom intractable postoperative hiccups were treated successfully by cervical epidural block.

Case Reports

Case 1

A 57-yr-old man underwent cholecystectomy for cholecystitis under a combination of general (nitrous oxide, enflurane) and epidural

anesthesia. During the operation, hiccups occurred twice and were treated with 20 mg succinylcholine on each occasion.

Three days after surgery, hiccups recurred. No subphrenic abscess was confirmed by echography. Nasopharyngeal stimulation, aspiration of the stomach, 20 mg metoclopramide, and 50 mg intravenous chlorpromazine failed to stop the hiccups. The patient became severely depressed and experienced difficulty sleeping because the hiccups were continuous. On the 7th day after surgery, melena and fresh blood from the nasogastric tube were observed. Gastroscopy revealed a gastric ulcer, and gastrectomy was planned. General anesthesia was maintained with nitrous oxide and enflurane, and muscle relaxation was achieved using 6 mg pancuronium bromide. After the administration of pancuronium bromide, the hiccups disappeared. Gastrectomy was performed, and surgeons could find no cause of the hiccups. After reversal of paralysis, the hiccups recurred.

In the surgical postoperative unit, a continuous infusion of droperidol (1.6 mg/h) was started, and epidural block at the T5 intervertebral space was performed with 10 ml 1.5% lidocaine. Although analgesia was obtained from T3 to T11, the hiccups continued. On the next day, a cervical epidural catheter was placed at the C7 intervertebral space and 8 ml 1.5% lidocaine was injected through the catheter. Hiccups stopped 10 min after the injection. The hiccups did not appear for the next 1.5 h. The analgesic level was from C3 to T4 bilaterally. The position of the diaphragm in the chest x-ray appeared unchanged from where it had been before the block, and the patient did not complain of dyspnea. As 8 ml 0.5% bupivacaine was effective in suppressing the hiccups for 4-5 h, the same dose was injected every 6 h. Although minimal hiccups appeared just before the next injection, a bolus 6 ml 1.5% lidocaine was effective

* Associate Professor of Anesthesiology.

† Resident.

‡ Professor and Chairman of Anesthesiology.

Received from the Department of Anesthesiology, Institute of Clinical Medicine, University of Tsukuba, Tsukuba-shi, Ibaraki-ken, Japan. Accepted for publication February 18, 1993.

Address reprint requests to Dr. Sato: Department of Anesthesiology, Institute of Clinical Medicine, University of Tsukuba, Tsukuba-shi, Ibaraki-ken, Japan 305.

Key words: Anesthetic techniques: cervical epidural; phrenic nerve block. Complications: intractable hiccups.