

CORRESPONDENCE

flumazenil on sedation and hypoxic ventilatory response. *Anesth Analg* 68:473-478, 1989

18. Khamnei S, Robbins PA: Hypoxic depression of ventilation in humans: Alternative models for the chemoreflexes. *Respir Physiol* 81:117-134, 1990

19. Georgopoulos D, Bereczanski D, Anthonisen NR: Effects of CO₂ breathing on ventilatory response to sustained hypoxia in normal adults. *J Appl Physiol* 66:1071-1078, 1989

(Accepted for publication March 2, 1993.)

Anesthesiology
78:1192, 1993
© 1993 American Society of Anesthesiologists, Inc.
J. B. Lippincott Company, Philadelphia

A Right-angled Alligator Clip for Use with Insulated Nerve Block Needles

To the Editor:—Insulated needles with a nerve stimulator are used frequently to perform peripheral nerve blocks.¹ Typically, the anode is grounded to the patient, and stimulation of the needle tip is accomplished by attaching the cathode alligator clip to the metal hub of an insulated needle.

This needle assembly has a number of drawbacks. It is cumbersome and can be difficult to manipulate, particularly if the alligator clip is attached to a small needle. The wire from the alligator clip trails at a right angle from the needle, enabling it to enter the sterile field. Furthermore, the alligator clip has a tendency to move when the needle is manipulated during nerve blockade.

A solution to these problems is suggested by employing a right-angled alligator clip. This can be made by carefully breaking off that part of the alligator clip (Archer mini alligator clips 1-1/4", cat no. 270-380A) that bears the "teeth" using pliers. The teeth are then soldered at a right angle to the ends of another alligator clip that have been shortened and flattened using pliers. When the teeth of the right-angled alligator clip grasp the hub of the block needle, the wire lies parallel to the extension tube and can be wound around it for added support (fig. 1). The right-angled alligator clip appears more compact and convenient to use than the standard alligator clip, particularly with short needles.

Ed Lee, M.B., B.Ch., F.F.A.R.C.S.I.
Department of Anesthesiology
Vanderbilt University Hospital




Fig. 1. Right-angled alligator clip attached to the hub of a 25-G sheathed pencil-point needle with extension set.

Veterans Administration Medical Center
1310 24th Avenue S
Nashville, Tennessee 37212-2637

Reference

1. Pither CE, Raj PP: The use of peripheral nerve stimulators for regional anesthesia: A review of experimental characteristics, techniques, and clinical applications. *Reg Anesth* 10:49-58, 1985

(Accepted for publication March 16, 1993.)

Anesthesiology
78:1192-1193, 1993
© 1993 American Society of Anesthesiologists, Inc.
J. B. Lippincott Company, Philadelphia

Parents in the Operating Room?

To the Editor:—Many centers in which an appreciable number of pediatric surgical operations are performed allow parents or other responsible adults into the operating room during the anesthetic induction of children. Hopefully, this effects a less frightening and

traumatic experience for the child by providing a familiar face in unfamiliar surroundings. The presence of parents in the operating room is not without its pitfalls, as illustrated by the following unusual experience.

CORRESPONDENCE

A healthy, 7-yr-old girl was scheduled for umbilical hernia repair under general anesthesia. Preoperatively, the child was anxious and refused to leave her grandmother, who had accompanied her to the hospital. It was decided to allow the grandmother to be in the operating room to help comfort the child during induction of anesthesia. In the operating room, routine monitors were applied and the patient sat in the anesthesiologist's lap while halothane/oxygen/nitrous oxide was administered by mask for induction. As the child proceeded through the second stage of anesthesia, she became slightly excited and began to struggle. The grandmother became greatly distressed by this and felt that we were "choking" the patient. Suddenly, she grabbed the child and carried her out of the operating room. The grandmother and child returned to the outpatient surgery center reception area, where the patient was found to be in good condition despite having undergone partial induction of anesthesia.

This case illustrates that allowing parents or other relatives into the operating room may not always be the best solution for dealing with anxious children. Parents, also, should be assessed preoperatively as being "anxious" or "calm," and only the "calm" parents permitted to accompany the child into the operating room.¹ If parents

are determined to be unsuitable candidates for going into the operating room, alternative methods, *e.g.*, sedation, should be considered to help calm an overly anxious child.

Julius R. Bowie, M.D.

Assistant Professor

Department of Anesthesiology

University of South Florida College of Medicine
12901 Bruce B. Downs Boulevard, MDC 59

Tampa, Florida 33612

Reference

1. Bevan JC, Johnston C, Haig MJ, Tousignant G, Lucy S, Kirnon V, Assimes IK, Carranza R: Preoperative parental anxiety predicts behavioural and emotional responses to induction of anaesthesia in children. *Can J Anaesth* 37:177-182, 1990

(Accepted for publication March 19, 1993.)

Anesthesiology

78:1193-1194, 1993

© 1993 American Society of Anesthesiologists, Inc.

J. B. Lippincott Company, Philadelphia

Intravenous Oxygenator Use in Adult Respiratory Distress Syndrome

To the Editor:—We have read with interest the recent article by High *et al.*¹ describing the clinical use of an intravenous oxygenator (IVOX) in patients with adult respiratory distress syndrome (ARDS). We would like to report our experience with two patients with acute respiratory failure who have been treated with IVOX. Both patients recovered completely from ARDS and could be separated from mechanical ventilation.

The first patient was a 52-yr-old, 128-kg man who was referred to our unit 3 days after suffering a blunt chest trauma. X-ray studies had revealed bilateral rib fractures as well as left clavicular and scapular fractures. On admission to our unit, the patient showed signs of pneumonia associated with severe respiratory embarrassment. The patient's trachea was intubated, and controlled mechanical ventilation was started. At an inspired oxygen concentration (F_{iO_2}) of 1.0, the Pa_{O_2}/F_{iO_2} ratio was 60, with the intrinsic positive end-expiratory pressure (PEEP) being 12 cmH₂O (fig. 1). After 2 days of conventional ventilator treatment, the decision was made to implant an IVOX *via* the right femoral vein into the vena cava as described by Mortensen and Berry.² Immediately after implantation of a #8 IVOX, the arterial oxygen saturation (Sa_{O_2}) increased from 89% to 94% and the mixed-venous oxygen saturation (Sv_{O_2}) from 61% to 71%. There was constant improvement in oxygenation over the following days. The F_{iO_2} could be reduced to 0.45. Thus, intravascular oxygenation was stopped on day 9, and the IVOX was removed on day 10, with the Pa_{O_2}/F_{iO_2} ratio being 228. The patient's trachea was extubated on the second day

after removal of the IVOX. He was discharged from the intensive care unit 1 week later.

The maximum oxygen transfer rate of the IVOX was measured to be between 59 and 123 ml/min, corresponding to 14–28% of the patient's oxygen consumption. The carbon dioxide transfer rate ranged between 41 and 83 ml/min. Despite the heparin-coating of the IVOX fibers, the patient was systemically anticoagulated with heparin to achieve an activated clotting time of 200 s. A marked

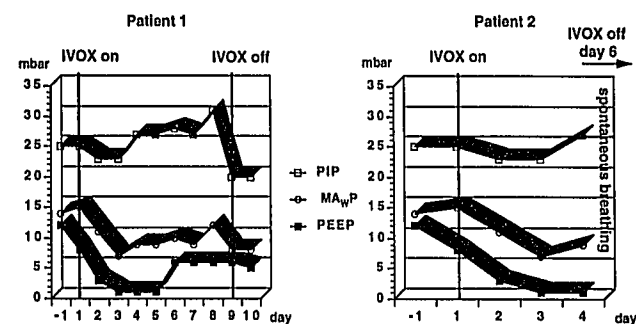


Fig. 1. Peak inspiratory pressures (PIP), mean airway pressures (MAWP) and positive end-expiratory pressures (PEEP) in the two patients during intravascular oxygenator (IVOX) treatment.