

CORRESPONDENCE

A healthy, 7-yr-old girl was scheduled for umbilical hernia repair under general anesthesia. Preoperatively, the child was anxious and refused to leave her grandmother, who had accompanied her to the hospital. It was decided to allow the grandmother to be in the operating room to help comfort the child during induction of anesthesia. In the operating room, routine monitors were applied and the patient sat in the anesthesiologist's lap while halothane/oxygen/nitrous oxide was administered by mask for induction. As the child proceeded through the second stage of anesthesia, she became slightly excited and began to struggle. The grandmother became greatly distressed by this and felt that we were "choking" the patient. Suddenly, she grabbed the child and carried her out of the operating room. The grandmother and child returned to the outpatient surgery center reception area, where the patient was found to be in good condition despite having undergone partial induction of anesthesia.

This case illustrates that allowing parents or other relatives into the operating room may not always be the best solution for dealing with anxious children. Parents, also, should be assessed preoperatively as being "anxious" or "calm," and only the "calm" parents permitted to accompany the child into the operating room.¹ If parents

are determined to be unsuitable candidates for going into the operating room, alternative methods, *e.g.*, sedation, should be considered to help calm an overly anxious child.

Julius R. Bowie, M.D.

Assistant Professor

Department of Anesthesiology

University of South Florida College of Medicine
12901 Bruce B. Downs Boulevard, MDC 59

Tampa, Florida 33612

Reference

1. Bevan JC, Johnston C, Haig MJ, Tousignant G, Lucy S, Kirnon V, Assimes IK, Carranza R: Preoperative parental anxiety predicts behavioural and emotional responses to induction of anaesthesia in children. *Can J Anaesth* 37:177-182, 1990

(Accepted for publication March 19, 1993.)

Anesthesiology

78:1193-1194, 1993

© 1993 American Society of Anesthesiologists, Inc.

J. B. Lippincott Company, Philadelphia

Intravenous Oxygenator Use in Adult Respiratory Distress Syndrome

To the Editor:—We have read with interest the recent article by High *et al.*¹ describing the clinical use of an intravenous oxygenator (IVOX) in patients with adult respiratory distress syndrome (ARDS). We would like to report our experience with two patients with acute respiratory failure who have been treated with IVOX. Both patients recovered completely from ARDS and could be separated from mechanical ventilation.

The first patient was a 52-yr-old, 128-kg man who was referred to our unit 3 days after suffering a blunt chest trauma. X-ray studies had revealed bilateral rib fractures as well as left clavicular and scapular fractures. On admission to our unit, the patient showed signs of pneumonia associated with severe respiratory embarrassment. The patient's trachea was intubated, and controlled mechanical ventilation was started. At an inspired oxygen concentration (F_{iO_2}) of 1.0, the Pa_{O_2}/F_{iO_2} ratio was 60, with the intrinsic positive end-expiratory pressure (PEEP) being 12 cmH₂O (fig. 1). After 2 days of conventional ventilator treatment, the decision was made to implant an IVOX *via* the right femoral vein into the vena cava as described by Mortensen and Berry.² Immediately after implantation of a #8 IVOX, the arterial oxygen saturation (Sa_{O_2}) increased from 89% to 94% and the mixed-venous oxygen saturation (Sv_{O_2}) from 61% to 71%. There was constant improvement in oxygenation over the following days. The F_{iO_2} could be reduced to 0.45. Thus, intravascular oxygenation was stopped on day 9, and the IVOX was removed on day 10, with the Pa_{O_2}/F_{iO_2} ratio being 228. The patient's trachea was extubated on the second day

after removal of the IVOX. He was discharged from the intensive care unit 1 week later.

The maximum oxygen transfer rate of the IVOX was measured to be between 59 and 123 ml/min, corresponding to 14–28% of the patient's oxygen consumption. The carbon dioxide transfer rate ranged between 41 and 83 ml/min. Despite the heparin-coating of the IVOX fibers, the patient was systemically anticoagulated with heparin to achieve an activated clotting time of 200 s. A marked

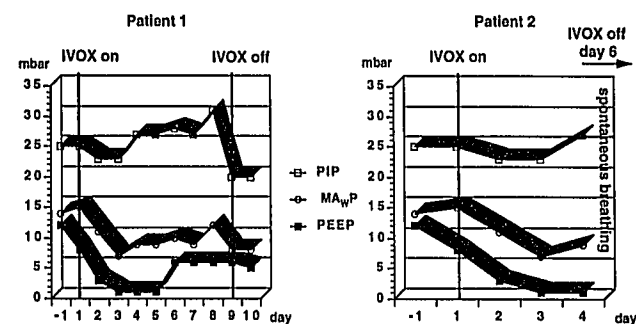


Fig. 1. Peak inspiratory pressures (PIP), mean airway pressures (MAWP) and positive end-expiratory pressures (PEEP) in the two patients during intravascular oxygenator (IVOX) treatment.

CORRESPONDENCE

hematoma developed around the insertion site of the oxygenator, thus necessitating local surgical intervention on day 4 after implantation. After additional bleeding from the chest tubes, the activated clotting time was aimed at 160 s. There was no further evidence of hemorrhage. On explanation of the IVOX, several minor thrombi were found between the fibers.

The second patient was an 18-yr-old, 80-kg man with fractures of both femurs and tibias who developed severe ARDS following fat embolism. After 2 days of conventional treatment at an F_{iO_2} of 1.0 and a PEEP of 10 cmH₂O, resulting in a P_{aO_2}/F_{iO_2} ratio of 50 (fig. 2), the decision was made to insert an IVOX device. On the 1st day after implantation of the #8 IVOX, the F_{iO_2} could be reduced to 0.7. Separation from mechanical ventilation was started 3 days later, and the trachea was extubated on day 5 after implantation. After extubation, positive airway pressure was continued *via* face mask. The IVOX device was removed on the following day under local anesthesia, and the patient was discharged from the intensive care unit 4 days later.

The oxygen transfer rates ranged between 64 and 84 ml/min, corresponding to 23–28% of the patients' oxygen consumption. The carbon dioxide transfer rates ranged between 26 and 39 ml/min. Systemic anticoagulation with heparin was aimed at an activated clotting time of 150 s. After removal of the IVOX device, there was no evidence of thrombus formation on the fibers of the catheter.

Thus, a reduction in F_{iO_2} was achieved in both patients within 24 h after implantation of the IVOX device. Peak inspiratory pressures could not be reduced, but always remained less than 31 cmH₂O in patient 1 and less than 27 cmH₂O in patient 2. Respiratory minute ventilation also remained unchanged in both patients; it did not exceed 78 ml/kg in patient 1 and 145 ml/kg in patient 2. Hypercapnia was allowed up to arterial P_{CO_2} values of 70 mmHg.

Since the currently available IVOX system only provides a low oxygen transfer in the range of about 20–30% of the patient's oxygen consumption, we believe that IVOX implantation should occur at an early stage of acute respiratory failure to avoid aggressive mechanical ventilation and prevent further ventilation-induced lung damage. In contrast to the patients described by High *et al.*¹ who were near death from severe hypoxia, our patients were part of a phase 2 study enabling us to select patients at an earlier stage of ARDS. When using the currently available device, we would question the usefulness of IVOX in advanced stages of ARDS. However, intravenous oxygenation might be a useful adjunct in the early stage of ARDS.

Anesthesiology
78:1194–1195, 1993
© 1993 American Society of Anesthesiologists, Inc.
J. B. Lippincott Company, Philadelphia

In Reply:—My coauthors and I were heartened to read this report of two patients with adult respiratory distress syndrome who survived while receiving the intravenous oxygenator (IVOX) as described by Schmidt and colleagues. The first patient had improved oxygenation after IVOX insertion. It is less clear that the second patient's oxygenation improved as a result of IVOX insertion because the improvement in inspired oxygen requirement occurred over the 1st day of treatment. We expect any gas exchange effect as a result of

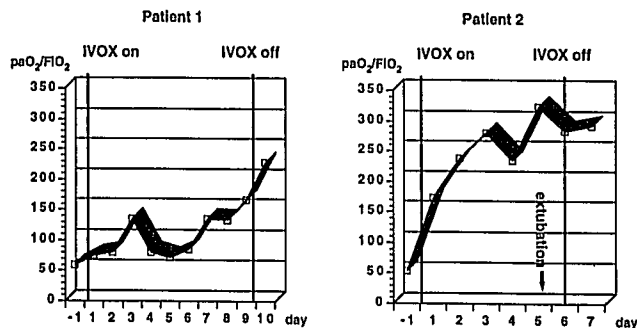


Fig. 2. P_{aO_2}/F_{iO_2} ratio during intravascular oxygenator (IVOX) treatment in the two patients.

Heinfried Schmidt, M.D.
Resident

Hubert Böhrer, M.D.
Staff Anesthesiologist

Johann Motsch, M.D.
Staff Anesthesiologist

Department of Anesthesia

Ahmed Tanzeem, M.D.
Staff Cardiac Surgeon

University of Heidelberg
Neuenheimer Feld 110
D-W-6900 Heidelberg, Germany

References

1. High KM, Snider MT, Richard R, Russell GB, Stene JK, Campbell DB, Aufero TX, Thieme GA: Clinical trials of an intravenous oxygenator in patients with adult respiratory distress syndrome. *ANESTHESIOLOGY* 77:856–863, 1992
2. Mortensen JD, Berry G: Conceptual and design features of a practical, clinically effective intravenous mechanical blood oxygen/carbon dioxide exchange device (IVOX). *Int J Artif Organs* 12:384–389, 1989

(Accepted for publication March 22, 1993.)

IVOX itself to be apparent within 30 min after beginning oxygen flow through the device.

From the information given, it is difficult to compare our results with those described in these two patients. Certainly, the patients we described had more profound respiratory failure. Further, the function of the IVOX in oxygen or carbon dioxide exchange is also difficult to compare. The effect of IVOX on the partial pressures in mixed venous and arterial blood depends not only on the quantity