

## CORRESPONDENCE

hematoma developed around the insertion site of the oxygenator, thus necessitating local surgical intervention on day 4 after implantation. After additional bleeding from the chest tubes, the activated clotting time was aimed at 160 s. There was no further evidence of hemorrhage. On explanation of the IVOX, several minor thrombi were found between the fibers.

The second patient was an 18-yr-old, 80-kg man with fractures of both femurs and tibias who developed severe ARDS following fat embolism. After 2 days of conventional treatment at an  $F_{iO_2}$  of 1.0 and a PEEP of 10 cmH<sub>2</sub>O, resulting in a  $P_{aO_2}/F_{iO_2}$  ratio of 50 (fig. 2), the decision was made to insert an IVOX device. On the 1st day after implantation of the #8 IVOX, the  $F_{iO_2}$  could be reduced to 0.7. Separation from mechanical ventilation was started 3 days later, and the trachea was extubated on day 5 after implantation. After extubation, positive airway pressure was continued *via* face mask. The IVOX device was removed on the following day under local anesthesia, and the patient was discharged from the intensive care unit 4 days later.

The oxygen transfer rates ranged between 64 and 84 ml/min, corresponding to 23–28% of the patients' oxygen consumption. The carbon dioxide transfer rates ranged between 26 and 39 ml/min. Systemic anticoagulation with heparin was aimed at an activated clotting time of 150 s. After removal of the IVOX device, there was no evidence of thrombus formation on the fibers of the catheter.

Thus, a reduction in  $F_{iO_2}$  was achieved in both patients within 24 h after implantation of the IVOX device. Peak inspiratory pressures could not be reduced, but always remained less than 31 cmH<sub>2</sub>O in patient 1 and less than 27 cmH<sub>2</sub>O in patient 2. Respiratory minute ventilation also remained unchanged in both patients; it did not exceed 78 ml/kg in patient 1 and 145 ml/kg in patient 2. Hypercapnia was allowed up to arterial  $P_{CO_2}$  values of 70 mmHg.

Since the currently available IVOX system only provides a low oxygen transfer in the range of about 20–30% of the patient's oxygen consumption, we believe that IVOX implantation should occur at an early stage of acute respiratory failure to avoid aggressive mechanical ventilation and prevent further ventilation-induced lung damage. In contrast to the patients described by High *et al.*<sup>1</sup> who were near death from severe hypoxia, our patients were part of a phase 2 study enabling us to select patients at an earlier stage of ARDS. When using the currently available device, we would question the usefulness of IVOX in advanced stages of ARDS. However, intravenous oxygenation might be a useful adjunct in the early stage of ARDS.

Anesthesiology  
78:1194–1195, 1993  
© 1993 American Society of Anesthesiologists, Inc.  
J. B. Lippincott Company, Philadelphia

*In Reply:*—My coauthors and I were heartened to read this report of two patients with adult respiratory distress syndrome who survived while receiving the intravenous oxygenator (IVOX) as described by Schmidt and colleagues. The first patient had improved oxygenation after IVOX insertion. It is less clear that the second patient's oxygenation improved as a result of IVOX insertion because the improvement in inspired oxygen requirement occurred over the 1st day of treatment. We expect any gas exchange effect as a result of

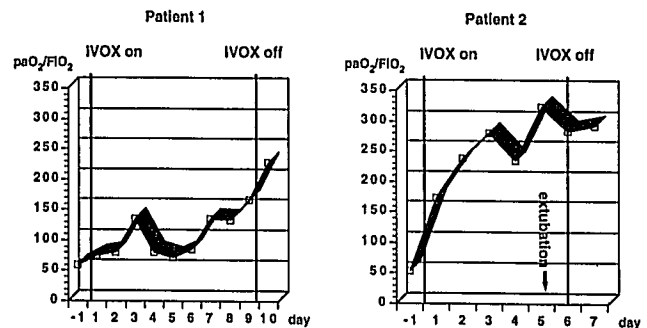


Fig. 2.  $P_{aO_2}/F_{iO_2}$  ratio during intravascular oxygenator (IVOX) treatment in the two patients.

Heinfried Schmidt, M.D.  
Resident

Hubert Böhrer, M.D.  
Staff Anesthesiologist

Johann Motsch, M.D.  
Staff Anesthesiologist

Department of Anesthesia

Ahmed Tanzeem, M.D.  
Staff Cardiac Surgeon

University of Heidelberg  
Neuenheimer Feld 110  
D-W-6900 Heidelberg, Germany

## References

1. High KM, Snider MT, Richard R, Russell GB, Stene JK, Campbell DB, Aufero TX, Thieme GA: Clinical trials of an intravenous oxygenator in patients with adult respiratory distress syndrome. *ANESTHESIOLOGY* 77:856–863, 1992
2. Mortensen JD, Berry G: Conceptual and design features of a practical, clinically effective intravenous mechanical blood oxygen/carbon dioxide exchange device (IVOX). *Int J Artif Organs* 12:384–389, 1989

(Accepted for publication March 22, 1993.)

IVOX itself to be apparent within 30 min after beginning oxygen flow through the device.

From the information given, it is difficult to compare our results with those described in these two patients. Certainly, the patients we described had more profound respiratory failure. Further, the function of the IVOX in oxygen or carbon dioxide exchange is also difficult to compare. The effect of IVOX on the partial pressures in mixed venous and arterial blood depends not only on the quantity

## CORRESPONDENCE

of gas exchanged but also on the patient's cardiac output and hemoglobin concentration. As detailed in our article,<sup>1</sup> the method used to determine oxygen and carbon dioxide transfer across the IVOX membrane makes special technologic demands. Schmidt *et al.*'s letter omits any details of this measurement. Particularly, the calculation of oxygen exchange is difficult because of both the small difference between the inlet and outlet oxygen mole fractions and the difference in total gas flow rate in and out of the IVOX caused by different rates of carbon dioxide and oxygen transfer.

We agree that earlier intervention in the course of ARDS with such modalities as IVOX may reduce the effects of mechanical ventilation, but we believe when and how to intervene with IVOX has not yet been determined. Because of the wide variation in clinical outcome with adult respiratory distress syndrome, a randomized, prospective study with rigorous entry criteria will be needed to demonstrate the efficacy of IVOX.

**Kane M. High, M.D.**  
Associate Professor

**Michael T. Snider, M.D., Ph.D.**  
Professor

**John K. Stene, M.D., Ph.D.**  
Associate Professor

Department of Anesthesia  
The Milton S. Hershey Medical Center  
The Pennsylvania State University  
P.O. Box 850  
Hershey, Pennsylvania 17033

## Reference

1. High KM, Snider MT, Richard R, Russell GB, Stene JK, Campbell DB, Aufiero TX, Thieme GA: Clinical trials of an intravenous oxygenator in patients with adult respiratory distress syndrome. *ANESTHESIOLOGY* 77:856-863, 1992

(Accepted for publication March 22, 1993.)

Anesthesiology  
78:1195-1196, 1993  
© 1993 American Society of Anesthesiologists, Inc.  
J. B. Lippincott Company, Philadelphia

## A New Transparent Disposable Plastic Face Mask for Children and Adults

*To the Editor:*—Since the introduction of the anesthesia face mask in the last century, many significant improvements in face mask design and fit have been made, including removable head-strap hook-rings, malleable nasal bridges, and inflatable facial cushions with Luer-lock filling nipples. More recent design advancements have included low-dead-space masks, especially the pediatric Rendell-Baker/Soucek masks,<sup>1</sup> and transparent masks that permit close observation of color changes and secretions.

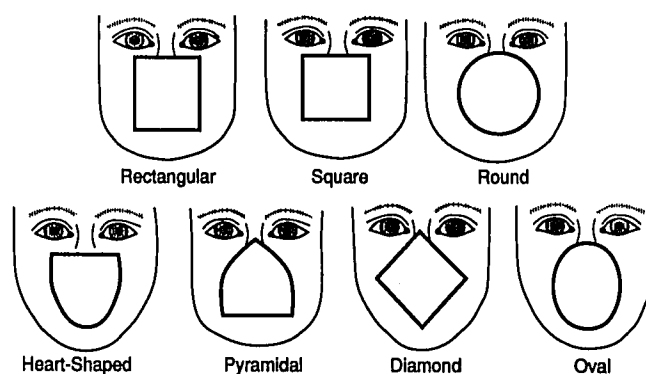
Foreign and domestic medical product companies have now flooded U.S. markets with a profusion of new plastic face masks in a variety of colors, shapes, sizes, and even scents. As the new products meet the current markets at higher costs, anatomy remains the same, and the perfect mask fit remains elusive.

There are only seven basic facial shapes—all of which change from flat to angular with age (fig. 1). Thus, there always will be a need for face masks in child and adult sizes. Rarely, uncommon conditions such as mucopolysaccharidoses and craniofacial deformities so distort facial anatomy that unusual face mask applications are needed to improve mask fit. I recently recommended the upside-down application of an air-cushioned pediatric face mask for children with Hurler syndrome.<sup>2</sup> With this application, the broad chin edge of the mask contours to frontal bossing, and the narrow nasal bridge covers a small mouth and contains a protruding tongue.<sup>2</sup>

Figure 2 depicts a new transparent plastic face mask, featuring a body of malleable plastic sheeting that can be hand-molded easily to fit the seven basic facial shapes shown in figure 1. The new face mask also has a removable head-strap hook-ring, a malleable nasal bridge, and an inflatable facial cushion with a Luer-lock filling nipple.

Child sizes include premie, neonate, infant, preschool, and school-aged. Scents may be impregnated by manufacturers or selected by the child and applied by the anesthesiologist. Adult sizes include small, medium, and large.

Such a new face mask design would combine modern improvements, the latest plastics technology, and a unique capability to be hand-molded to the seven basic facial shapes by the anesthesiologist (fig. 1). If adopted by manufacturers, such a face mask may bring anesthesiologists closer to that elusive perfect mask fit.



**Fig. 1.** The seven basic facial shapes with an overlay of transparent plastic sheeting that is malleable enough to be contoured to fit the underlying shape.