

## CASE REPORTS

Anesthesiology

79:602-604, 1993

© 1993 American Society of Anesthesiologists, Inc.

J. B. Lippincott Company, Philadelphia

### Transesophageal Echocardiographic Diagnosis of Pulmonary Artery Catheter Entrapment and Coiling

Christopher A. Troianos, M.D.,\* Richard W. Stypula, Jr., M.D.†

COMPLICATIONS associated with pulmonary artery (PA) catheter insertion include dysrhythmias,<sup>1,2</sup> heart block,<sup>3,4</sup> pulmonary artery rupture,<sup>5</sup> pulmonary infarction,<sup>6</sup> balloon rupture, arterial puncture, air embolism, infection, pneumothorax, and knotting of the catheter.<sup>7</sup> Transesophageal echocardiography (TEE) is being used with increasing frequency, as a qualitative technique for monitoring cardiac function, and as a diagnostic technique for assessing abnormalities of cardiac and aortic structures. The main pulmonary artery and PA catheter can be imaged by positioning the TEE probe in the basal short axis view at the level of the aortic root. The following case reports describe the utility of TEE in determining the cause of PA catheter entrapment and in the recognition of PA catheter coiling during cardiac surgery.

#### Case Report

##### Case 1

A 71-yr-old, 74-kg, 165-cm woman with a 4-yr history of mitral regurgitation presented for mitral valve repair or replacement because of recent onset of congestive heart failure. A PA catheter (7.5 FR VIP, Baxter, Irvine, CA) was inserted through a percutaneous sheath introducer (8.5 FR, Arrow, Reading, PA) placed in the right internal jugular vein. The catheter was inserted until a PA wedge pressure tracing was obtained at an insertion depth of 55 cm. After anesthetic induction and tracheal intubation, a 5.0-MHz single-plane TEE probe (128 XP/E; Acuson, Mountain View, CA) was inserted into the esophagus to evaluate the mitral valve before repair or possible replacement. No obvious abnormalities were noted in the TEE examination of the right atrium. Two vena cava cannulae (36 FR, Sarns,

Ann Arbor, MI) were inserted into the right atrium for cardiopulmonary bypass. The mitral valve was replaced with a 31-mm Medtronic Hall (Minneapolis, MN) prosthetic valve, because the native mitral valve could not be repaired. No obvious abnormalities were noted on the postcardiopulmonary bypass TEE examination, and the prosthetic mitral valve appeared to be functioning appropriately.

Two days after surgery, an attempt to withdraw the PA catheter was discontinued because unusual resistance was encountered. A chest radiograph revealed a single coil in the PA catheter in the area of the right atrium, with the catheter tip positioned in the right pulmonary artery. No other abnormalities of the PA catheter were noted. The patient was transferred to the operating room for surgical exploration. After anesthetic induction and tracheal intubation, the TEE probe was inserted to determine whether the PA catheter was entrapped in the atrial purse-string sutures or in the mitral valve annular sutures. The PA catheter was visualized abutting the free wall of the right atrium. Entrapment of the PA catheter in the atrial purse-string sutures was confirmed by visualizing invagination of the lateral free wall of the atrium, when the PA catheter was pulled back within the introducer (fig. 1). The right atrial purse-string sutures were released through a median sternotomy, and the catheter was withdrawn without resistance.

##### Case 2

A 62-yr-old, 90-kg, 163-cm woman with a history of rheumatic heart disease and mitral stenosis presented for mitral valve replacement because of increasing symptoms of shortness of breath, orthopnea, and pulmonary hypertension. A PA catheter (7.5 FR VIP, Baxter) was inserted through a percutaneous sheath introducer (8.5 FR, Arrow) placed in the right internal jugular vein before induction of anesthesia. A right ventricular pressure tracing was observed with insertion of the PA catheter to 28 cm. A wedge pressure tracing was observed at 55 cm. After anesthetic induction and tracheal intubation, a 5.0-MHz single-plane TEE probe (128 XP/E; Acuson) was inserted into the esophagus to evaluate the mitral valve and to assess the prosthetic mitral valve function after replacement of the native mitral valve.

Imaging of the pulmonary artery revealed the tip of the PA catheter positioned in the right pulmonary artery (fig. 2). The tip of the PA catheter was identified by the characteristic greater echogenicity of the thermistor and by inflation of the balloon. As the catheter was withdrawn within the introducer, imaging of the catheter tip demonstrated no movement until 12 cm of catheter were withdrawn. The balloon on the PA catheter was then reinflated, and a wedge pressure tracing was obtained at 48 cm catheter insertion.

#### Discussion

Entrapment of the PA catheter in the atrial purse-string sutures may occur during any cardiac surgical proce-

\* Vice Chairman for Research, Director, Intraoperative Transesophageal Echocardiography, Department of Anesthesiology.

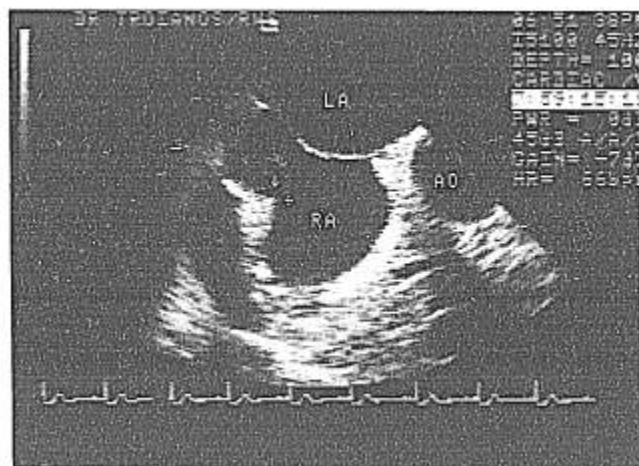† Vice Chairman for Education, Department of Anesthesiology.

Received from the Department of Anesthesiology, Mercy Hospital of Pittsburgh, Pittsburgh, Pennsylvania. Accepted for publication May 13, 1993.

Address reprint requests to Dr. Troianos: Department of Anesthesiology, Mercy Hospital of Pittsburgh, 1400 Locust Street, Pittsburgh, Pennsylvania 15219.

Key words: Measurement techniques: transesophageal echocardiography. Monitoring: pulmonary artery pressure. Surgery, cardiac: complications; pulmonary artery catheter entrapment.

## CASE REPORTS



**Fig. 1.** Two-dimensional echocardiogram demonstrating invagination of the right atrial wall as the pulmonary artery catheter is withdrawn. RA = right atrium; LA = left atrium; AO = aortic root. Arrows indicate invagination of right atrial free wall. Top is posterior.

cedure requiring right atrial cannulation. Several reports of PA catheters entrapped by sutures appear in the literature,<sup>8-13</sup> with recommendations for percutaneous release of the catheter entrapment. The current report demonstrates that TEE may be useful in identifying the location of an entrapment or the presence of PA catheter coiling.

Entrapment of the PA catheter into the annular sutures during a mitral or aortic valve replacement or annuloplasty procedure may necessitate another cardiac surgical procedure with cardiopulmonary bypass to release the PA catheter. Entrapment of the PA catheter by right atrial sutures will usually not require cardiopulmonary bypass and, in some instances, the entrapment may be percutaneously relieved.<sup>8-13</sup>

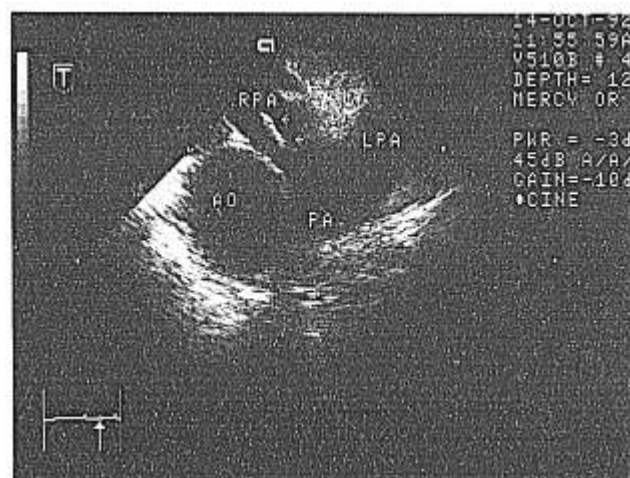
Knotting of the PA catheter is another cause of resistance to withdrawal, and may simulate entrapment. Knotting is more likely to occur with the smaller, more flexible 5 FR catheters.<sup>14</sup> Excessive advancement of any PA catheter beyond normally anticipated distances may lead to knotting.<sup>7</sup> The cause of the resistance to withdrawal, therefore, is important information in guiding further intervention.

Transesophageal echocardiography was employed in the first case presented to determine the site of PA catheter entrapment and to direct surgical correction. Invagination of the right atrium while withdrawing the PA catheter confirmed its attachment to the lateral free wall of the right atrium. The implication of this finding

was that institution of cardiopulmonary bypass for direct examination inside the right atrium was not required. More importantly, the TEE examination determined that release of mitral annular sutures and, possibly, resuturing the prosthetic mitral valve were not necessary.

In the second case, unrecognized coiling of the PA catheter was demonstrated using TEE imaging of the catheter tip in the pulmonary artery. The catheter tip did not move as the catheter was withdrawn without resistance within the introducer. An actual coil is usually not observed with TEE imaging, because the entire coiled segment of catheter is not in the same plane as the ultrasound sector. Coiling is suspected whenever a wedge pressure tracing is observed at a PA catheter insertion depth of greater than 50 cm *via* the right internal jugular vein. However, it is not unusual for patients with right heart failure or tall patients to require an insertion depth of greater than 50 cm. In these situations, the diagnosis of coiling is more difficult, and may be unrecognized, as in case 2, in which the patient had some degree of right heart failure secondary to mitral stenosis and pulmonary hypertension.

We recommend identifying patients who are at increased risk for PA catheter entrapment and performing the following maneuvers for diagnosing PA catheter entrapment and coiling during cardiac surgical procedures that employ TEE. The right atrium is imaged



**Fig. 2.** Two-dimensional echocardiogram, basal short axis view at the level of the aortic root, demonstrating the tip of the pulmonary artery catheter in the right pulmonary artery. RPA = right pulmonary artery; LPA = left pulmonary artery; PA = main pulmonary artery; AO = aortic root. Arrows indicate tip of PA catheter. Top is posterior.

in the four-chamber view after atrial decannulation. Invagination of the lateral free wall of the right atrium, while the PA catheter is withdrawn, may reveal possible PA catheter entrapment in the atrial purse-string sutures. In addition, we suggest TEE visualization of catheter movement in the pulmonary artery during withdrawal, to confirm that the catheter is not entrapped along its entire length. If the catheter is coiled, it can be withdrawn without resistance, but there is no associated movement of its distal tip in the pulmonary artery. If the catheter is entrapped, withdrawal meets resistance, and the catheter tip does not move. Performing these maneuvers requires the attention of the anesthesiologist. If the patient is hemodynamically unstable after bypass, these maneuvers should not take precedence over primary patient care until the patient is hemodynamically stable.

We recommend performing these maneuvers on higher-risk patients before sternal closure. Increased risk for entrapment occurs whenever a right or left atrial suture line is performed. The performance of two atriotomies for bicaval cannulation also increases the risk. In this case, PA catheter entrapment is more likely to occur within the inferior atriotomy sutures. A mid-right atrial cannulation site is also a predisposition for entrapment. This cannulation site is used for reoperations, because the right atrial appendage is removed during the initial operation. Identifying patients who are at greater risk, and performing the maneuvers described in this paper, may help to eliminate the need for post-operative interventions by identifying PA catheter entrapment or coiling intraoperatively.

The authors wish to thank Drs. E. S. Siker, B. Wolfson, and S. R. Chaplan, for their editorial assistance, and Jodie J. Allen and Jo Ann

Kirley, for their secretarial assistance in preparation of this manuscript.

## References

1. Katz JD, Cronau LH, Barash PG, Mandel SD: Pulmonary artery flow-guided catheters in the perioperative period: Indications and complications. *JAMA* 237:2832-2834, 1977
2. Geha DG, David NJ, Lappas DG: Persistent atrial arrhythmias associated with placement of a Swan-Ganz catheter. *ANESTHESIOLOGY* 39:651-653, 1973
3. Abernathy WS: Complete heart block caused by a Swan-Ganz catheter. *Chest* 65:349, 1974
4. Thomson IR, Dalton BC, Lappas DG, Howenstein E: Right bundle branch block and complete heart block caused by the Swan-Ganz catheter. *ANESTHESIOLOGY* 51:359-362, 1979
5. Lapin ES, Murray JA: Hemoptysis with flow-directed cardiac catheterization (letter). *JAMA* 220:1246, 1972
6. Foote GA, Schabel SI, Hodges M: Pulmonary complications of the flow-directed balloon-tipped catheter. *N Engl J Med* 290:927-931, 1974
7. Lipp H, O'Donoghue K, Resnekov L: Intracardiac knotting of flow-directed balloon catheter (letter). *N Engl J Med* 284:220, 1971
8. Block PC: Snaring of a Swan-Ganz catheter. *J Thorac Cardiovasc Surg* 71:917-919, 1976
9. Block PC: Vent stitch entrapment (letter). *Anesth Analg* 64:379, 1985
10. Wholey MH, Zikria EA, Boyle B: Inadvertent atrial fixation of a Swan-Ganz catheter by suture and a method for its percutaneous removal. *Cardiovasc Intervent Radiol* 10:171-174, 1987
11. Eliassen P, Vejlsted H: A mechanical complication with a balloon-tipped catheter during open-heart surgery. *Scand J Thorac Cardiovasc Surg* 14:205, 1980
12. Vucins EJ, Rusch JR, Grum CM: Vent stitch entrapment of Swan-Ganz catheters during cardiac surgery. *Anesth Analg* 63:772-774, 1984
13. Lazzam C, Sanborn TA, Christian F Jr: Ventricular entrapment of a Swan-Ganz catheter: A technique for nonsurgical removal. *J Am Coll Cardiol* 13:1422-1424, 1989
14. Buckbinder N, Ganz W: Hemodynamic monitoring: Invasive techniques. *ANESTHESIOLOGY* 45:146-155, 1976