

CASE REPORTS

Anesthesiology
80:227-229, 1994
© 1994 American Society of Anesthesiologists, Inc.
J. B. Lippincott Company, Philadelphia

Threatening Spinal Cord Compression during Anesthesia in a Child with Mucopolysaccharidosis VI

Ulf Linstedt, M.D.,* Christoph Maier, M.D.,† Hans Joehnk, M.D.,‡ Ulrich Stephani, M.D.§

MUCOPOLYSACCHARIDOSES (MPS) are uncommon diseases with an incidence of about 1 in 30,000.¹ Because of a specific enzyme deficiency, mucopolysaccharides (now termed glycosaminoglycans) accumulate in different tissues. With increased incidence, such patients undergo surgery, especially for hernia repair, tonsillectomy, and malformations of the jaw.² Significant disturbances related to anesthesia are dysfunction of the liver, frequent pulmonary infections, and upper airway obstruction. The latter may lead to a difficult or impossible intubation of the trachea. Deaths during induction of anesthesia have been reported.³

Less known during anesthesia is the possibility of compressive myelopathy due to a thickening of the dura caused by storage of mucopolysaccharides. In addition, there is danger of dislocation of the cervical spine and compression of the spinal cord, caused by a malformation of the odontoid process in MPS. These patients may develop a slowly progressing myelopathy in the course of the disease or an accidental cervical cord transection due to hyperextension of the occiput, such as during tracheal intubation.⁴⁻⁶ There have been no reports about prevention of an incipient paraplegia during anesthesia.

We describe perioperative management and monitoring in a patient with MPS type VI (Maroteaux-Lamy), in whom a reversible spinal cord compression occurred intraoperatively.

Case Report

This 12-yr-old girl of normal intelligence had MPS type VI. She had typical symptoms, including multiple dysostoses, dwarfism, low body weight (28 kg, less than the 3rd percentile), hepatosplenomegaly, loss of hearing, dense corneal clouding, systolic murmur, and hoarseness. A meticulous ear-nose-throat investigation was impossible. Indication for surgery was a progressing instability of the jaw caused by tooth retention. Magnetic resonance imaging (MRI) of the brain performed about 1 yr earlier because of headache revealed enlarged cerebrospinal fluid spaces. A second evaluation of this MRI scan before the operation also revealed a thickened dura mater with critical narrowing of the spinal canal and a hypoplastic odontoid (fig. 1). Despite this finding, the patient did not complain of symptoms related to radiculopathy, nor could any neurologic deficits be detected by detailed neurologic examinations, including changing the head and neck position and testing somatosensory evoked potentials (SEP). The only symptom was headache reported 1 yr earlier.

Anesthesia was induced with methohexital 1.5 mg/kg. Oral surgery required nasotracheal intubation, despite the increased risk of bleeding in MPS patients.² Tracheal intubation in the spontaneously breathing patient was assisted by fiberoptic guidance. A narrowing of the larynx resulting from extreme thickening of the aryepiglottic fold was found. Anesthesia was maintained with nitrous oxide-oxygen 1:1, isoflurane 0.4-0.8 vol%, and three supplemental doses of fentanyl 0.025 mg. SEP were monitored while the median nerve was stimulated with a Neuropack 4 Mini (Nihon Kohden, Tokyo, Japan). Electrodes were attached to the brachial plexus at the midpoint of the right clavicle (Erb's point), to the seventh and second cervical vertebrae, and to the sensory cortex at position C3' (10-20 international system). Electrode impedance was maintained at less than 2 k Ω ; 200 stimuli were delivered at a rate of 5 stimuli/s (stimulus duration 0.2 ms). An intensity sufficient to cause a digital twitch was used, and the bandpass was set at 30-3,000 Hz.

During the first several hours of the operation the head was maintained in a neutral position with the use of a specially designed support. The SEP were normal (fig. 2A). After 3 h of uneventful surgery, without obvious changes of the head position, the cortical waves of the SEP disappeared for approximately 10 min (fig. 2B). An acute

* Resident in Anesthesiology, Department of Anesthesiology.

† Staff Anesthesiologist, Department of Anesthesiology.

‡ Assistant in Maxillofacial Surgery, Clinic for Maxillofacial Surgery.

§ Professor, Chairman in Neuropediatrics, Clinic for Neuropediatrics.

Received from the Christian-Albrechts-Universität, Kiel, Germany. Accepted for publication August 27, 1993.

Address reprint requests to Dr. Linstedt: Klinik für Anaesthesiologie und Operative Intensivmedizin, Christian-Albrechts-Universität Kiel, Schwanebergweg 21, D-24105 Kiel, Germany.

Key words: Anesthesia: pediatric. Monitoring: somatosensory evoked potentials. Spinal cord.

CASE REPORTS

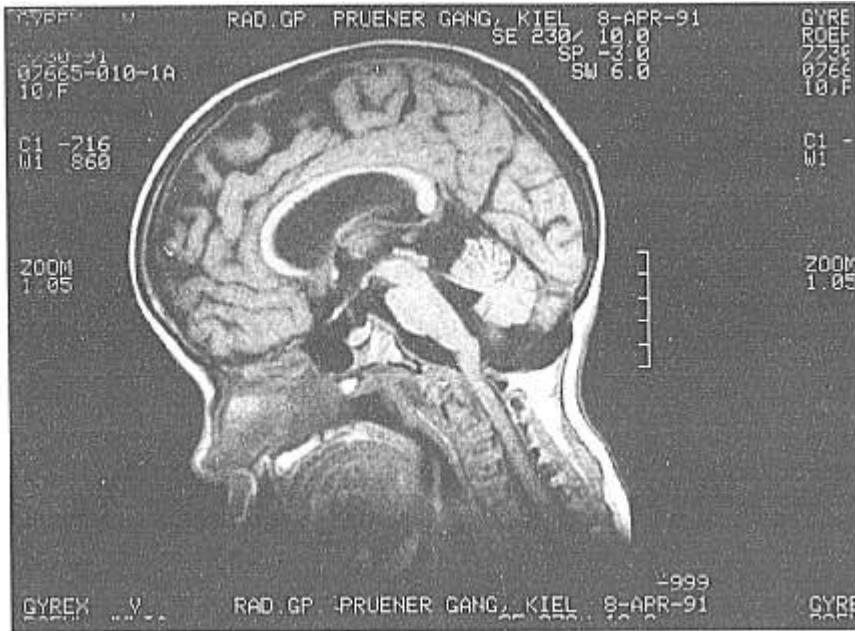


Fig. 1. Cranial magnetic resonance imaging scan. Large cerebral fluid spaces are visible. In the atlantooccipital region, a thickened dura mater (critically narrowing the cervical spine) and a hypoplastic odontoid are evident. (Reproduced by permission of the Practice of Radiology, Pruener Gang, Kiel.)

spinal cord compression was suspected, and the operation was interrupted. The head was carefully repositioned by slight anteflexion. After this procedure the cortical waves of the SEP reappeared immediately (fig. 2C), and, as the anesthetic state was decreased, spon-

taneous movements of the arms and legs were seen. The 8-h operation continued uneventfully.

After completion of surgery the trachea was extubated. Once the patient was awake, there were no disturbances in sensory or motor

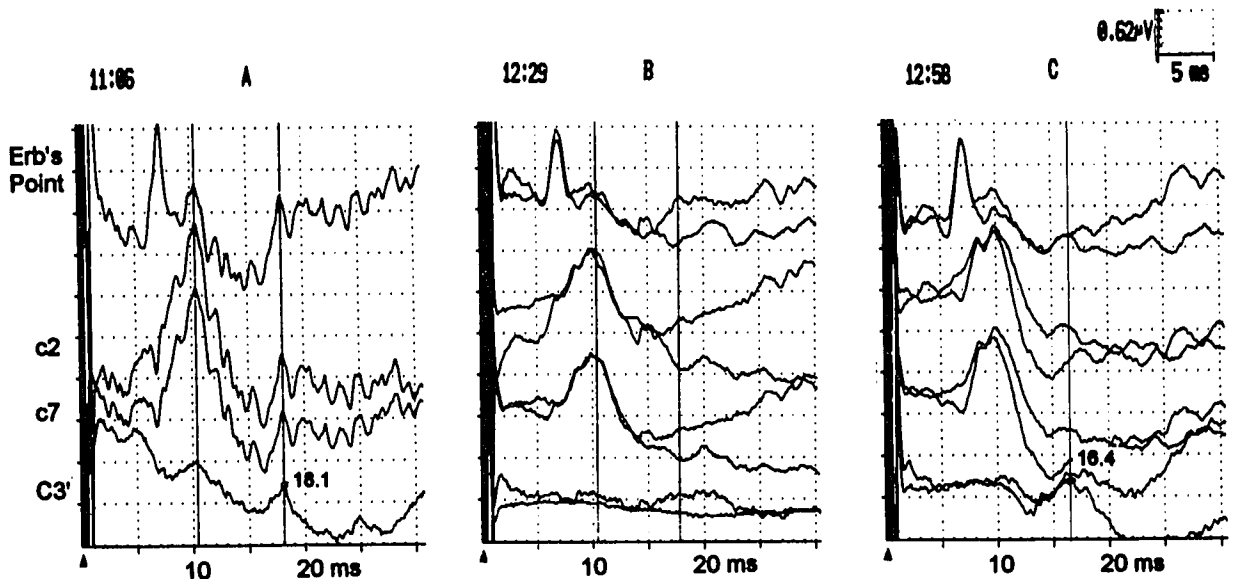


Fig. 2. Intraoperative median nerve somatosensory evoked potentials before (A), during (B), and after (C) the period of suspected cervical cord compression. The single (A) or pairs of curves (B and C) show, from top to bottom, potentials recorded from the brachial plexus (Erb's point), from the seventh (C7) and second (C2) cervical vertebrae, and from the sensory cortex (electrode position C3'). The trace on the position C3' in A shows a wave with a latency of 18.1 ms. This wave disappeared in trace (B), providing the diagnosis of conduction disturbance between the second cervical vertebra and the cortex. After the head was repositioned, the cortical wave reappeared on 16.4 ms (C).

CASE REPORTS

function at rest or by change of head and neck position. The patient was discharged 6 days later without any neurologic deficits.

Discussion

Most MPS symptoms are direct consequences of excessive and progressive storage of glycosaminoglycans in different tissues. Therefore, the symptoms most often begin at the end of infancy and are characterized by continuous progression. There is, however, a case report of an 23-month-old girl suffering from MPS IV and undergoing an operation because of spinal cord compression.⁷

In the current case, the MPS posed several typical risks for anesthesia. The malformation of the larynx and the possibility of spinal cord compression were known preoperatively, the latter as an incidental result of an MRI scan that had been performed only because of headache. Significantly, the malformations of the cervical spine present before surgery were not accompanied by clinical neurologic symptoms or findings. Nevertheless, along with the slightly altered position of the head and neck during surgery, these malformations probably induced a compression of the spinal cord intraoperatively. Intraoperative spinal cord compression was diagnosed by SEP monitoring.

Symptoms due to definite spinal cord compression are found in patients with MPS types I, II, IV, and VI. They are consequences of thickening of the dura and hypoplasia of the odontoid. Single cases of acute paraplegia have been reported.^{3,5} Fiberoptic guidance may be necessary during intubation to avoid hyperextension of the head and to facilitate intubation when pathologic conditions exist in the larynx and the cervical spine. The high perioperative morbidity and mortality rate (20–30%) in patients with MPS as a result of difficult or even impossible tracheal intubation has been reported.⁸

Because patients suffering from MPS are at risk when undergoing anesthesia, extensive preliminary diagnostic procedures are recommended. These include examination of the upper respiratory tract, spine, heart, and lungs, and, especially, a careful neurologic examination. Spinal cord compression can follow intubation by direct laryngoscopy or by improper positioning of the head during anesthesia, even (as in the current case) after a delay of several hours.

To assess this risk, it is very helpful to obtain an MRI scan of the spine. Only MRI is sensitive enough to show dura thickening and odontoid hypoplasia. If clinical neurologic symptoms of spinal cord compression are obvious, or if MRI reveals an anatomic malformation of the spinal column, intraoperative SEP monitoring is essential.

References

1. King DH, Jones RM, Barnett MB: Anaesthetic considerations in the mucopolysaccharidoses. *Anaesthesia* 39:126–131, 1984
2. Martz DG, Schreiberman DL, Matjasko MJ: Neurological diseases, *Anesthesia and Uncommon Diseases*. Edited by Katz J, Benumof JL, Kadis LB, Philadelphia, WB Saunders, 1990, pp 525, 579–580
3. Sostrin RD, Hasso AN, Peterson DI, Thompson JR: Myelographic features of mucopolysaccharidoses: A new sign. *Radiology* 125:421–424, 1977
4. Beighton P, Craig J: Atlanto-axial subluxation in the Morquio syndrome. *J Bone Joint Surg* 55:478–481, 1973
5. Kaufman HH, Rosenberg HS, Scott CI, Lee YY, Pruessner JL, Butler IJ: Cervical myelopathy due to compression in mucopolysaccharidosis. *Surg Neurol* 17:404–410, 1982
6. Sjogren P, Pedersen T, Steinmetz H: Mucopolysaccharides and anaesthetic risks. *Acta Anaesthesiol Scand* 31:214–218, 1987
7. Tazanova I, Schwarz M, Jantzen JP: Die Sicherung der Atemwege von Kindern mit Morquio-Brailsford-Syndrom. *Anaesthesist* 42:477–481, 1993
8. Stoelting RK, Dierdorf SF, McCammon RL: *Anesthesia and Co-existing Disease*. New York, Churchill Livingstone, 1988, pp 539–540