

## Local Anesthetic Myotoxicity: A Case and Review

Quinn Hogan, M.D.,\* Rose Dotson, M.D.,† Scott Erickson, M.D.,‡ Robert Kettler, M.D.,§ Kirk Hogan, M.D. ||

MYOTOXICITY of local anesthetic agents in clinical concentrations has been recognized since 1959<sup>1</sup> and documented in studies on rats, primates, and humans.<sup>2-5</sup> Hypercontracted myofibrils are evident 5 min after exposure of skeletal muscle to local anesthetics.<sup>6,7</sup> Lytic degeneration of striated muscle sarcoplasmic reticulum (SR) and mitochondria begins within 15 min after injection, progressing to myocyte edema and necrosis, followed by phagocytosis of cellular debris over the next 24-48 h.<sup>2,4,8,9</sup> The basal lamina, satellite cells (myoblasts), vasculature, and neural elements remain intact; thus, complete regeneration ensues within 3-4 weeks.<sup>8-10</sup> All local anesthetics that have been tested are myotoxic.<sup>1,3,11</sup> Procaine produces the least and bupivacaine the most severe injury.<sup>8</sup> Injection of local anesthetics intramuscularly<sup>4,8</sup> or into adjacent subcutaneous tissue<sup>1,2</sup> results in myonecrosis. The extent of muscle injury from local anesthetics is dose-dependent<sup>1,11</sup> and worsens with serial administra-

tion.<sup>9,12</sup> Injecting steroid<sup>13</sup> or epinephrine<sup>14</sup> with the local anesthetic injection worsens the myonecrosis. Permanent histologic changes not limited to muscle cells may follow serial injections<sup>12,15</sup> or coinjection of epinephrine with the local anesthetic.<sup>8</sup>

Local anesthetics are injected into muscle for treatment of myofascial pain,<sup>16</sup> into wound margins during surgery, and for neural blockade during surgical anesthesia. Although experimental myotoxic responses are intense and reproducible, there are few reports of myotoxic complications from local anesthetic injections in patients. We describe a patient in whom bupivacaine produced clinically important muscle injury.

### Case Report

A healthy 71-kg, 40-yr-old female, underwent capsular release of the left shoulder. She previously received local anesthetics without complications. Her personal and family history included no anesthetic intolerance nor neurologic or muscular complaints. Because continuous passive shoulder motion and physical therapy were planned for the immediate postoperative period, neural blockade during and after the procedure was planned. A 3.2-cm 20-G intravenous catheter (Angiocath, Becton Dickinson, Sandy, UT) was placed in the left interscalene groove at the level of the cricoid cartilage, eliciting a paresthesia to the hand. The catheter was secured with a transparent dressing after removal of the needle. Bupivacaine (0.5%) with epinephrine (5 µg/ml) was injected incrementally to a total volume of 45 ml, producing sensory and motor blockade of the shoulder, arm, and hand. General anesthesia (thiopental, fentanyl, isoflurane (0.6% maximum), nitrous oxide, vecuronium) also was used during the 4-h procedure.

Normal sensation in the hand was noted by 15 h after the initial injection. The patient first complained of shoulder pain at 16 h and was treated with 45 ml 0.5% bupivacaine with 5 µg/ml epinephrine through the catheter, producing complete relief but no sensory change in the hand. At 20.5 h, 50 ml of the same solution was used successfully to treat pain. A further injection at 28 h of 40 ml of the same solution produced adequate but incomplete relief of shoulder pain. A final injection at 34 h of 48 ml failed to produce analgesia, and the catheter was removed. The total dose was 1,140 mg (average 33.5 mg/h). There were no complaints during the injections, no evidence of bleeding, and no apparent mass as the solution was administered. Minimal force was required for the injections.

Anesthesia resolved in the arm and shoulder but persisted in the left side of the neck from the posterior border of the sternocleidomastoid muscle (SCM) to the midline and from the clavicle to the

\* Assistant Professor, Department of Anesthesiology, Medical College of Wisconsin.

† Assistant Professor, Department of Neurology, Medical College of Wisconsin.

‡ Associate Professor, Department of Radiology, Medical College of Wisconsin.

§ Associate Professor, Department of Anesthesiology, Medical College of Wisconsin.

|| Associate Professor, Department of Anesthesiology, William S. Middleton Memorial Veterans Hospital and the University of Wisconsin.

Received from the Departments of Anesthesiology, Neurology, and Radiology, Medical College of Wisconsin, Milwaukee, Wisconsin; the Department of Anesthesiology, William S. Middleton Memorial Veterans Hospital, Madison, Wisconsin; and the University of Wisconsin, Madison, Wisconsin. Accepted for publication November 29, 1993.

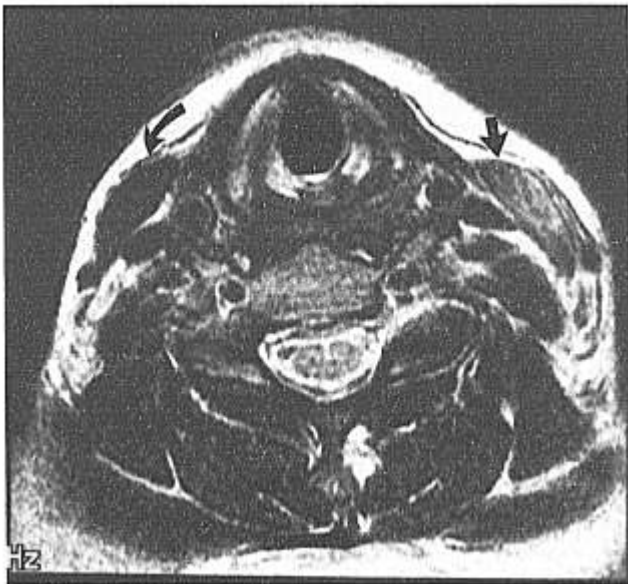Address reprint requests to Dr. Hogan: Department of Anesthesiology, Milwaukee County Medical Complex, 8700 West Wisconsin Avenue, Milwaukee, Wisconsin 53226.

Key words: Anesthetics, local: bupivacaine. Anesthetics, local: myotoxicity. Muscle, skeletal: local anesthetic toxicity. Toxicity: local anesthetics.

## CASE REPORTS

ramus of the mandible. On the 3rd postoperative day, tenderness of the left SCM was noted. Minimal swelling was observed, but no ecchymosis, fluctuance, localized warmth, or fever. The leukocyte count and differential were normal, but the erythrocyte sedimentation rate was elevated to 46 ml/h (normal 0–20). Turning the head to the left side aggravated the pain, which was relieved only by turning the head right and depressing the left ear to the left shoulder. Transcutaneous electrical nerve stimulation, immobilization with a foam collar, nonsteroidal anti-inflammatory drugs, and tricyclic antidepressants provided no relief. On the 19th postoperative day, an electromyograph (EMG) examination showed spontaneous activity and diminished recruitment in the left SCM, with normal trapezius and paraspinal activity.

Because of persistent pain, magnetic resonance imaging was performed on the 45th day (fig. 1). The images were obtained on a 1.5T Signa unit (GE Medical Systems, Milwaukee, WI) using a specially designed anterior neck coil. Axial T1-weighted and fast spin-echo T2-weighted images showed the left SCM to be enlarged with a uniformly increased signal intensity compared to the right (fig. 1). Because this suggested tissue injury, further EMG evaluation was performed on the 50th day. Small, brief, polyphasic motor unit action potentials were confirmed, indicative of myopathy restricted to the left SCM. A biopsy of the left SCM caudal to the site of EMG needle insertion was performed on the 54th day, showing degenerating and regenerating muscle fibers, myophagia, fiber splitting, and inflammatory infiltrates with many eosinophils (fig. 2). Vessels, muscle spindles, and intramuscular nerve twigs were normal. Immunofluorescent staining for immunoglobulins, complement, and fibrin was negative. Findings typical of neurogenic disease, including type grouping, angular atrophic fibers, and target fibers were not observed.



**Fig. 1.** T2-weighted fast spin echo (TR = 5,000, TE<sub>effective</sub> = 90) axial image at the level of the 6th cervical vertebra, showing an enlarged left sternocleidomastoid muscle (SCM; straight arrows), with increased signal intensity compared to the normal right SCM (curved arrows).

Oral prednisone (60 mg/kg) was administered for 4 weeks. The patient's complaints gradually abated during the 3rd postoperative month.

## Discussion

This patient's neck pain followed interscalene injections of bupivacaine and epinephrine. Converging lines of evidence, including clinical presentation, time course, laboratory investigations, EMG evaluation, magnetic resonance imaging, and histology support the diagnosis of local myopathy due to bupivacaine injection. The clinical signs of muscle tenderness, intensification of pain with stretch, and relief by shortening fit the diagnosis of myopathy of the SCM. The gradual onset of pain can be explained by inflammation, as reflected in the elevated erythrocyte sedimentation rate, although this nonspecific finding may follow surgical stress. Electron microscopic examination of primate responses to bupivacaine shows the maximal inflammatory response develops on the 3rd or 4th day.<sup>10</sup> The neurogenic features revealed by the first EMG are also characteristic of necrotic or inflammatory myopathy.<sup>17</sup> Since more distal muscles were not affected, motor nerve damage is an unlikely primary etiology. Subsequent EMG examination revealed the electrical wave forms pathognomonic for myopathy.<sup>17</sup>

Magnetic resonance images showed diffuse abnormality of the left SCM. Increased signal intensity evident on the T1-weighted images can represent hemorrhage, increased fat, protein, or flowing blood. Edema shows decreased signal intensity on T1-weighted images. The images are compatible with increased protein, corresponding to an ongoing process of inflammation and regeneration.<sup>18</sup>

Histologic findings are characteristic of local anesthetic myopathy, in which preservation of basal lamina and satellite cells allows regeneration of myotubes. Variable injury of adjacent fibers<sup>10</sup> and presence of eosinophils<sup>1,19,20</sup> are also typical. A pathologic response prolonged through the 2nd month has not been identified previously after brief exposures to local anesthetics, but only single injections have been examined in primates.<sup>5</sup> Local anesthetic myonecrosis has been noted in human SCM muscle, but no observations were made after 18 h.<sup>4</sup> In rats, weekly<sup>21</sup> or monthly<sup>22</sup> bupivacaine injections produce striking myopathic changes lasting months after the last injection, including fiber splitting and central nuclei like those found in our patient (fig. 3).

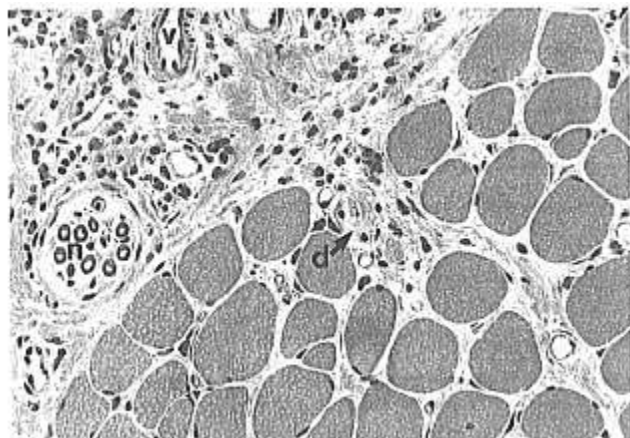


Fig. 2. Sternocleidomastoid muscle (hematoxylin and eosin stain, magnification 125 $\times$ ) showing inflammation with eosinophils, degenerating myofibers (d), nerve twig (n), and normal veins (v).

Other diagnoses are inadequate to explain the findings. There was no evidence of a pre-existing myopathy, and physical examination showed no infection or hematoma. The normal leukocyte count and differential argue against an infectious or immunologic etiology, and the protracted time course fits none of these alternatives. Surgery did not involve the painful area, and the head was in a neutral position during the procedure. Succinylcholine was not used, and there was no temperature elevation during surgery, as would be expected from volatile anesthetic-induced myopathy (malignant hyperthermia). Needle trauma to muscles produces a minor and focal lesion.<sup>11</sup> Minimal pressure was required during injection, and ischemia from a localized high compartment pressure would result in destruction of all tissue components. The anesthetic solutions contained no preservative. Physical examination and EMG studies provided no evidence for a diffuse myopathy. The muscle biopsy findings do not support the diagnosis of a dystrophy, metabolic myopathy, or neurogenic process. Sensory dysfunction of the anterior cervical branches may represent inflammation from the adjacent SCM, which they pass as they emerge from the cervical plexus. Alternatively, this may be due to direct bupivacaine neurotoxicity.<sup>9</sup>

Large doses of bupivacaine were used in our patient because of the desire to produce analgesia suitable for the near surgical stimulation produced by postoperative manipulations. Published catheter techniques for prolonged brachial plexus blockade have used bupivacaine either without epinephrine<sup>2,3-25</sup> or with much smaller

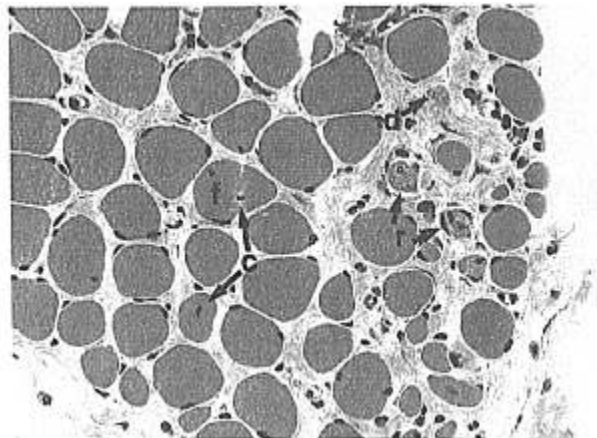


Fig. 3. Sternocleidomastoid muscle (hematoxylin and eosin stain, magnification 125 $\times$ ) demonstrating inflammation with degenerating (d) and regenerating (r) myofibers, central nuclei (c), and fiber splitting (f).

doses,<sup>23,26</sup> without reported toxic complications. Experimental studies show that both of these factors limit toxicity. In our patient, injections progressively failed to produce blockade, indicating that the catheter tip was dislodged from the interscalene groove. Up to 25% of interscalene catheters become dislodged, and even functioning catheters spill injectate outside the interscalene groove.<sup>25</sup> Local anesthetics produce myopathy even when injected outside the muscle into adjacent tissues,<sup>1,2</sup> and bupivacaine myotoxicity has been documented after continuous brachial plexus block in rabbits.<sup>20</sup>

The molecular mechanism of local anesthetic myotoxicity has not been elucidated fully. Irreversible injury by local anesthetics of mature myocytes in culture eliminates denervation secondary to blockade of the action potential or neuromuscular junction from etiologic consideration.<sup>27</sup> Tetrodotoxin, a local anesthetic without direct effects on intramuscular calcium,<sup>28</sup> is not myotoxic; therefore, inhibition of the sarcolemmal Na<sup>+</sup> channel cannot play a role.<sup>29</sup> Local anesthetics fail to elicit contractures, the earliest phase of local anesthetic toxicity, if SR accumulation of Ca<sup>2+</sup> is prevented by pretreatment with quercetin, indicating that toxicity is not caused by a direct site of action on the myofibrils.<sup>30</sup> Replication of local anesthetic myonecrosis with caffeine alone,<sup>29</sup> together with sparing of satellite cells that lack an internal membrane system capable of Ca<sup>2+</sup> sequestration,<sup>31</sup> points to pathologic efflux of intracellular Ca<sup>2+</sup> from the SR of mature multinucleated myocytes as a key element in local anesthetic myotox-

## CASE REPORTS

icity. Since SR vesicles, which lack the ATP-dependent  $\text{Ca}^{2+}$  pump, still show an increase in  $\text{Ca}^{2+}$  permeability when exposed to local anesthetics,<sup>32</sup> this pump is not the pathogenic site. Either a direct action of local anesthetics on the  $\text{Ca}^{2+}$  release channel, or a nonspecific increase in SR permeability to  $\text{Ca}^{2+}$  could lead to myoplasmic  $\text{Ca}^{2+}$  elevation. Incubation of SR vesicles with the  $\text{Ca}^{2+}$  release channel inhibitor ruthenium red does not prevent tetracaine-induced SR  $\text{Ca}^{2+}$  release, in support of the latter mechanism.<sup>30</sup> Recently, Barmatz and Zchut<sup>33</sup> showed that lidocaine and prilocaine increased ryanodine binding to isolated skeletal muscle  $\text{Ca}^{2+}$  release channels, proving a direct action of local anesthetics on this protein. Verapamil prevents local anesthetic myotoxicity<sup>29</sup>; however, when its action is limited to sarcolemmal  $\text{Ca}^{2+}$  channels by using concentrations that have no intracellular effects,<sup>34</sup> it fails to prevent local anesthetic myonecrosis,<sup>35</sup> further supporting SR  $\text{Ca}^{2+}$  release channels as the pathogenic site.

Reports of local anesthetic inhibition of SR  $\text{Ca}^{2+}$  release apparently contradict this proposition.<sup>36-38</sup> Inhibition is inversely proportional to ionized  $\text{Ca}^{2+}$ , however,<sup>30</sup> and occurs at local anesthetic concentrations up to 1 mM, whereas  $\text{Ca}^{2+}$  release requires higher (>1 mM) myoplasmic drug levels.<sup>32</sup> In culture, bupivacaine concentrations above 10 mM kill all adult myocytes, but 0.75 mM or less has no effect<sup>27</sup>; the concentrations used clinically (0.5% = 15 mM) are therefore in the toxic range that releases SR  $\text{Ca}^{2+}$ . Because it is the amount of free base reaching the SR that corresponds to the magnitude of injury,<sup>39</sup> the biphasic dose dependency is also pH-sensitive. Local anesthetic toxicity is potentiated at high pH,<sup>39</sup> and the pKa of the drug correlates with its capacity to destroy muscle at tissue pH. Clinical evidence of the dose dependency of toxicity is highlighted by the failure of local anesthetics to elicit muscle damage after systemic administration or in an intravenous (Bier) block of an extremity.<sup>40,41</sup> However, prolonged high systemic concentrations of local anesthetic occur with cocaine abuse, and lethal muscle destruction is a well recognized complication of this intoxication.<sup>42-45</sup>

The myotoxicity of local anesthetics is sufficiently predictable and intense in experimental settings to be employed as a research tool<sup>7,22</sup> and therapeutic adjunct.<sup>46</sup> However, clinical reports are uncommon. Myonecrosis has been alleged after trigger point injections<sup>16,17</sup> and retrobulbar blocks that included injection into the extraocular muscles,<sup>48</sup> but these reports

are not substantiated by radiographic imaging, histology, or electrophysiologic examination. There may be several explanations for the rare recognition of clinically significant myotoxicity despite extremely strong experimental evidence for its widespread occurrence. Local anesthetic injection for neural blockade only occasionally requires intramuscular injection of large volumes, such as for obturator and psoas compartment blocks. These are not usually repeated, and the injection site is difficult to examine. Small volumes are used with injections for intercostal, supraspinatus, or musculocutaneous nerve blocks and with trigger point injections and stellate ganglion blocks. Because experimental studies show myonecrosis after single injections of even minimal doses of local anesthetic, it is likely that myopathy occurs after most injections but is not recognized because of rapid and complete recovery. Local pain for which trigger point injections are performed may disguise myopathic changes, and discomfort and dysfunction after injections performed for surgical anesthesia can be readily attributed to surgery or concealed by surgical pain. Splinting prevents tenderness from being identified. The pain of inflammation develops only after 3 or 4 days, and the appearance of atrophy takes longer; thus, these events frequently may be missed or not correlated to administration of anesthetic agents.

In summary, we report a case of probable local anesthetic-induced myotoxicity. Efforts to maintain intense blockade despite a displaced catheter led to the use of doses that evidently may produce clinically relevant muscle injury. Because local anesthetic myotoxicity in animal models is most injurious after repeated administration of large volumes, doses that may be safe for single injection in patients may be inappropriate for repeat administration. High concentrations of bupivacaine<sup>9,11</sup> and the use of epinephrine<sup>14</sup> also are associated with increased myotoxicity and should be avoided if injections are to be made into or adjacent to muscle. Local anesthetic injury should be suspected when localized muscle dysfunction and tenderness follow anesthetic injection into the area. Biopsy (using procaine for local anesthesia) aids in differential diagnosis, and magnetic resonance spectroscopy might be used in establishing the diagnosis noninvasively.<sup>41</sup> In view of our case report and extensive laboratory confirmation, it will be of interest to see whether further investigations confirm a predictable myopathic response to local anesthetics in clinical settings.

## References

1. Brun A: Effect of procaine, Carbocaine and xylocaine on cutaneous muscle in rabbits and mice. *Acta Anaesthesiol Scand* 3:59-73, 1959
2. Benoit PW, Belt D: Destruction and regeneration of skeletal muscle after treatment with a local anesthetic, bupivacaine (Marcaine). *J Anat* 107:547-556, 1970
3. Pizzolato P, Renegar OJ: Histopathologic effects of long exposure to local anesthetics on peripheral nerves. *Anesth Analg* 38:138-141, 1959
4. Yagiela JA, Benoit PW, Buoncristiani RD, Peters MP, Fort NF: Comparison of myotoxic effects of lidocaine with epinephrine in rats and humans. *Anesth Analg* 60:471-480, 1981
5. Carlson BM, Shepard B, Komorowski TE: A histological study of local anesthetic-induced muscle degeneration and regeneration in the monkey. *J Orthop Res* 8:485-494, 1990
6. Hall-Craggs ECB: Early ultrastructural changes in skeletal muscle exposed to the local anesthetic bupivacaine (Marcaine). *Br J Exp Pathol* 61:139-149, 1980
7. Nonaka I, Takagi A, Ishiura S, Nakase H, Sugita H: Pathophysiology of muscle fiber necrosis induced by bupivacaine hydrochloride (Marcaine). *Acta Neuropathol* 60:167-174, 1983
8. Foster AH, Carlson BM: Myotoxicity of local anesthetics and regeneration of the damaged muscle fibers. *Anesth Analg* 59:727-736, 1980
9. Kytta J, Heinon E, Rosenberg PH, Wahlstrom T, Gripenberg J, Huopaniemi T: Effects of repeated bupivacaine administration on sciatic nerve and surrounding muscle tissue in rats. *Acta Anaesthesiol Scand* 30:625-629, 1986
10. Komorowski TE, Shepard B, Okland S, Carlson BM: An electron microscopic study of local anesthetic-induced skeletal muscle fiber degeneration and regeneration in the monkey. *J Orthop Res* 8:495-503, 1990
11. Benoit PW, Belt WD: Some effects of local anesthetic agents on skeletal muscle. *Exp Neurol* 34:264-278, 1972
12. Benoit PW: Microscarring in skeletal muscle after repeated exposures to lidocaine with epinephrine. *J Oral Surg* 36:530-533, 1978
13. Guttu RL, Page DG, Laskin DM: Delayed healing of muscle after injection of bupivacaine and steroid. *Ann Dent* 49:5-8, 1990
14. Benoit PW: Reversible skeletal muscle damage after administration of local anesthetics with and without epinephrine. *J Oral Surg* 36:198-201, 1978
15. Basson MD, Carlson BM: Myotoxicity of single and repeated injections of mepivacaine (Carbocaine) in the rat. *Anesth Analg* 59:275-282, 1980
16. Travell JG, Simons DG: *Myofascial Pain and Dysfunction*. Baltimore, Williams & Wilkins, 1983, p 79
17. Kimura J: *Electrodiagnosis of Diseases of Nerve and Muscle: Principles and Practice*. Philadelphia, FA Davis, 1989, pp 249-274
18. Lamminen AE, Hekali PE, Tiula E, Suramo I, Korhola OA: Acute rhabdomyolysis: Evaluation with magnetic resonance imaging compared with computed tomography and ultrasonography. *Br J Radiol* 62:326-331, 1989
19. Kalichman MW, Powell HC, Meyers RR: Pathology of local anesthetic-induced nerve injury. *Acta Neuropathol* 75:583-589, 1988
20. Pere P, Watanabe H, Pitkanen M, Wahlstrom T, Rosenberg PH: Local myotoxicity of bupivacaine in rabbits after continuous supraclavicular brachial plexus block. *Reg Anesth* 18:304-307, 1993
21. Sadeh M, Czyzewski K, Stern L: Chronic myopathy induced by repeated bupivacaine injections. *J Neurol Sci* 67:229-238, 1985
22. Bradley WG: *Muscle fiber splitting, Muscle Regeneration*. Edited by Munro A. New York, Raven, 1979, pp 215-232
23. Manriquez RG, Pallares V: Continuous brachial plexus block for prolonged sympathectomy and control of pain. *Anesth Analg* 57:128-130, 1978
24. Rosenblatt R, Pepitone-Rockwell F, McKillop MJ: Continuous axillary analgesia for traumatic hand injury. *ANESTHESIOLOGY* 51:565-566, 1979
25. Tuominen M, Hassio J, Herkali R, Rosenberg PH: Continuous interscalene brachial plexus block: Clinical efficacy, technical problems and bupivacaine plasma concentrations. *Acta Anaesthesiol Scand* 33:84-88, 1989
26. Ang ET, Lassale B, Goldfarb G: Continuous axillary brachial plexus block: A clinical and anatomical study. *Anesth Analg* 63:680-684, 1980
27. Schultz E, Lipton BH: The effect of Marcaine on muscle and non-muscle cells in vitro. *Anat Rec* 191:351-369, 1978
28. Narahashi T: Chemicals as tools in the study of excitable membranes. *Physiol Rev* 54:813-819, 1974
29. Benoit PW, Yagiela JA, Fort NF: Pharmacological correlation between local anesthetic-induced myotoxicity and disturbances of intracellular calcium distribution. *Toxicol Appl Pharmacol* 52:187-198, 1980
30. Pike GK, Abramson JJ, Salama G: Effects of tetracaine and procaine on skinned muscle fibers depend on free calcium. *J Muscle Res Cell Motil* 10:337-349, 1989
31. Mazanet R, Franzini-Armstrong C: *The satellite cell, Myology*. Edited by Engles AG, Banker BQ. New York, McGraw-Hill, 1986, pp 285-308
32. Johnson PN, Inesi G: The effects of methylxanthines and local anesthetics on fragmented sarcoplasmic reticulum. *J Pharmacol Exp Ther* 169:308-314, 1969
33. Shoshan-Barmatz V, Zehut S: The interaction of local anesthetics with the ryanodine receptor of the sarcoplasmic reticulum. *J Membrane Biol* 133:171-181, 1993
34. Janis RA, Scriabine A: Sites of action of Ca<sup>2+</sup> channel inhibitors. *Biochem Pharmacol* 32:3499-3507, 1983
35. Steer JH, Mastaglia FL, Papadimitriou JM, Van Bruggen I: Bupivacaine-induced muscle injury: The role of extracellular calcium. *J Neurol Sci* 73:205-217, 1986
36. Palade P, Dettbarn C, Brunder D, Stein P, Hals G: Pharmacology of calcium release from sarcoplasmic reticulum. *J Bioenerg Biomemb* 21:295-320, 1989
37. Klein MG, Simon BJ, Schneider MF: Effects of procaine and caffeine on calcium release from the sarcoplasmic reticulum in frog skeletal muscle. *J Physiol (Lond)* 453:341-366, 1992
38. Pizarro G, Csernoch L, Uribe I, Rios E: Differential effects of tetracaine on two kinetic components of calcium release in frog skeletal muscle fibers. *J Physiol (Lond)* 457:525-538, 1992
39. Bianchi CP: *Cellular pharmacology of contraction of skeletal muscle, Cellular Pharmacology of Excitable Tissues*. Edited by Narahashi T. Springfield, Charles C Thomas, 1975, pp 485-519
40. Kalso EA, Lalla ML, Rosenberg PH, Tuominen MK, Santavirta S, Gripenberg J: Evaluation of the myotoxicity of bupivacaine in Bier

## CASE REPORTS

blocks: A biochemical and electron microscopic study. *Anesth Analg* 62:796-801, 1983

41. Newman RJ, Radda GK: The myotoxicity of bupivacaine, a <sup>31</sup>P n.m.r. investigation. *Br J Pharmacol* 79:395-399, 1983

42. Lohmanee F, Tobak M: Fatal malignant hyperthermia associated with recreational cocaine and ethanol abuse. *Am J Forensic Med Pathol* 7:246-248, 1986

43. Merigan KS, Roberts JR: Cocaine intoxication: Hyperpyrexia, rhabdomyolysis and acute renal failure. *Clin Toxicol* 25:135-148, 1987

44. Merlin SI, Brissic RM, Kapila A, Hauser T: Hyperpyrexia, seizures and hypotension in a 31-year old man. *Alabama J Med Sci* 25:274-279, 1988

45. Warrian WG, Halikas JA, Crosby RD, Carlson GA, Crea F: Observations on increased CPK levels in "asymptomatic" cocaine abusers. Cocaine: Physiological and Pathophysiological Effects. Binghamton, Haworth, 1992, pp 83-95. NIDA monographs

46. Danko I, Fritz JD, Jiao S, Hogan K, Latendresse JS, Wolf JA: Pharmacological enhancement of *in vivo* foreign gene expression in muscle. *Gene Ther* (in press)

47. Parris WCV, Dettbarn WD: Muscle atrophy following bupivacaine trigger point injection. *Anesth Rev* 16:50-53, 1989

48. Rainin EA, Carlson BM: Postoperative diplopia and ptosis: A clinical hypothesis based on the myotoxicity of local anesthetics. *Arch Ophthalmol* 103:1337-1339, 1985

Anesthesiology

80:947-950, 1994

© 1994 American Society of Anesthesiologists, Inc.

J. B. Lippincott Company, Philadelphia

## Paradoxical Air Embolism during Venous Air Embolism: Transesophageal Echocardiographic Evidence of Transpulmonary Air Passage

Eric A. Bedell, M.D.,\* Keith H. Berge, M.D.,† Thomas J. Losasso, M.D.†

PARADOXICAL air embolism (PAE) can occur during venous air embolism (VAE) and may have devastating consequences.<sup>1,2</sup> Although intracardiac right-to-left shunting has been the proposed mechanism of PAE in the majority of cases, a number of case reports have documented PAE in which no cardiac defects could be detected either by intraoperative transesophageal echocardiography (TEE)<sup>3</sup> or at autopsy.<sup>4-6</sup> In the cases reported by Cucchiara *et al.*,<sup>3</sup> it is suggested that PAE could have occurred either through an undetected intracardiac defect, specifically a patent foramen ovale, or by transpulmonary air passage. Although PAE *via* pulmonary shunts have been identified in dogs,<sup>7-10</sup> this

mechanism of PAE has not been clearly demonstrated in humans. We present a case of TEE-detected PAE in a patient without a demonstrable intracardiac right-to-left shunt in whom there was direct evidence of transpulmonary PAE using intraoperative TEE.

### Case Report

A 65-yr-old man was scheduled for an occipital artery to posterior inferior cerebellar artery bypass *via* suboccipital craniectomy for unstable brain stem ischemia and impending infarction. The patient had a 1-yr history of progressive imbalance, ataxia and speech disturbances secondary to brainstem ischemia. He had suffered acute focal deficits 6 weeks preoperatively with evidence, by magnetic resonance imaging, of a cerebellar infarction, and a second infarction 1 week preoperatively with worsening dysarthria and new cranial nerve (VII, IX, and XII) deficits. Other pertinent medical problems included a history of mild chronic obstructive lung disease and an inferior wall myocardial infarction suffered 6 yr earlier. The patient had no known drug allergies and was medicated with Carafate (sucralfate) and heparin. Cerebral arteriogram demonstrated patent carotid arteries, a completely occluded left vertebral artery, 99% occlusion of the right vertebral artery and brainstem blood flow *via* meningeal collaterals. Electrocardiogram demonstrated normal sinus rhythm and findings consistent with an old inferior wall infarction. Pulmonary function studies demonstrated mild obstructive lung disease with moderate loss of diffusing capacity (forced vital capacity

\* Resident in Neuroanesthesia, Mayo Graduate School of Medicine.

† Assistant Professor of Anesthesiology, Mayo Medical School.

Received from the Department of Anesthesiology, Mayo Clinic, Rochester, Minnesota. Accepted for publication November 30, 1993.

Address reprint requests to Dr. Berge: Department of Anesthesiology, Mayo Clinic, 200 First Street, Southwest, Rochester, Minnesota 55905.

Key words: Anesthesia: neurosurgical. Complications: embolism. Embolism: air. Equipment: echocardiography.