

■ CASE REPORTS

Anesthesiology
80:1162-1164, 1994
© 1994 American Society of Anesthesiologists, Inc.
J. B. Lippincott Company, Philadelphia

Bronchial Trifurcation at the Carina Complicating Use of a Double-lumen Tracheal Tube

Rebecca Stene, M.D.,* Mindy Rose, M.D.,* Matthew B. Weinger, M.D.,† Jonathan L. Benumof, M.D.,‡ James Harrell, M.D.§

ANOMALOUS right upper lobe bronchus takeoff from the trachea has been reported to occur in 1 of 250 otherwise normal patients.¹ When inserting a double-lumen tube into a patient with such an anomaly, one can encounter many auscultatory findings, depending on the relationship of the endobronchial and tracheal cuffs and lumens to the trachea, main-stem bronchi, and right upper lobe bronchus takeoff. The case described below, of the intubation of the bronchus intermedius with the endobronchial lumen of a double-lumen tube in a patient with bronchial trifurcation at the carina, which previously has been unreported, provided a unique combination of auscultatory and bronchoscopic findings.

Case Report

A 29-yr-old, 60-kg, 152-cm-tall Hispanic woman with congenital thoracolumbar kyphoscoliosis was scheduled to undergo a T8-L3 fusion procedure through a right thoracotomy approach. She had undergone a similar procedure, through a left thoracotomy approach, in Mexico 11 yr before being admitted to our institution. No records of this previous procedure were available; the patient and her family were not aware of any perioperative complications.

A general anesthetic was designed to allow accurate intraoperative monitoring of evoked potentials. Other monitoring consisted of arterial oxygen saturation, partial pressure of end-tidal carbon dioxide,

electrocardiogram, and direct intraarterial pressure. Vital signs were within normal limits. Before anesthesia was induced, the patient breathed 100% oxygen *via* a mask for 5 min. The patient underwent induction of general anesthesia with etomidate (0.2 mg/kg intravenously) and succinylcholine (1.5 mg/kg intravenously). A left-sided, 35-French double-lumen tube was placed easily in the usual manner,² using direct laryngoscopy. Oxygen saturation remained at 100%, an appropriate mechanical ventilation carbon dioxide waveform was noted on the capnograph after intubation, and the patient was hemodynamically stable.

Breath sounds were grossly equal in the upper lung fields bilaterally when the tracheal cuff was inflated. When the bronchial (left) lumen was clamped after both cuffs had been inflated, breath sounds on the right were markedly decreased, although not completely absent. Breath sounds on the left were unchanged. When the tracheal (right) lumen was clamped, breath sounds ceased on the left, but were still evident on the right. At this time, it was thought that a right main-stem bronchial intubation, rather than the desired left main-stem bronchial intubation, had occurred. The double-lumen tube was removed and easily reinserted, only to yield the same auscultatory findings.

The fiberoptic bronchoscope then was inserted down the tracheal lumen and revealed what appeared to be the tracheal carina and a somewhat small right main-stem bronchus. More careful auscultation of all lung fields with clamping maneuvers revealed that with clamping of the tracheal lumen, breath sounds ceased in both the upper and lower lung fields on the left but were preserved over the right lung. Clamping of the bronchial lumen produced markedly decreased breath sounds in the right lower lung fields, but only partially diminished breath sounds over the right upper lung field, and preserved breath sounds over the left lung fields.

The double-lumen tube again was withdrawn. A 7.0-mm ID Univent tube (Fuji Systems, Tokyo, Japan) was inserted *via* direct laryngoscopy with the intention of using the bronchial blocker to achieve right lung collapse. The fiberoptic bronchoscope was inserted down the main lumen of the Univent tube and revealed a trifurcation, rather than the usual bifurcation, at the carina (fig. 1). A bronchoscopic examination revealed that the most rightward lumen was the right upper lobe bronchus, which terminated in a normal trifurcation that gave rise to the segmental bronchi. The middle lumen led to a bifurcation. Distal to this bifurcation, we found normal-appearing segmental bronchial anatomy for the right middle lobe and right lower lobe. The left lumen was the left main-stem bronchus, which gave rise to normal lobar and segmental bronchial anatomy in the left lung. The Univent tube was withdrawn. The double-lumen tube was reinserted so the tracheal cuff was just distal to the vocal cords. The fiberoptic bronchoscope then was passed down the endobronchial lumen, the trifurcation was sighted, and the fiberoptic bronchoscope was passed into the left main-stem bronchus. The left lumen of the

* Resident in Anesthesiology.

† Associate Professor of Anesthesiology.

‡ Professor of Anesthesiology.

§ Clinical Professor of Medicine.

Received from the Departments of Anesthesiology and Medicine, University of California at San Diego Medical Center, Department of Anesthesiology. Accepted for publication December 16, 1993.

Address reprint requests to Dr. Benumof: UCSD Medical Center, Mailcode 0801, 402 Dickinson Street, San Diego, California 92103-0801.

Key words: Airway: anomalous tracheobronchial tree; congenital anomaly; right main-stem bronchus; right upper lobe bronchus; trachea. Anesthetic techniques: one-lung ventilation. Equipment: bronchial blocker tube; double-lumen tube; Univent bronchial blocker tube. Lung(s): separation. Surgery: thoracic.

CASE REPORTS

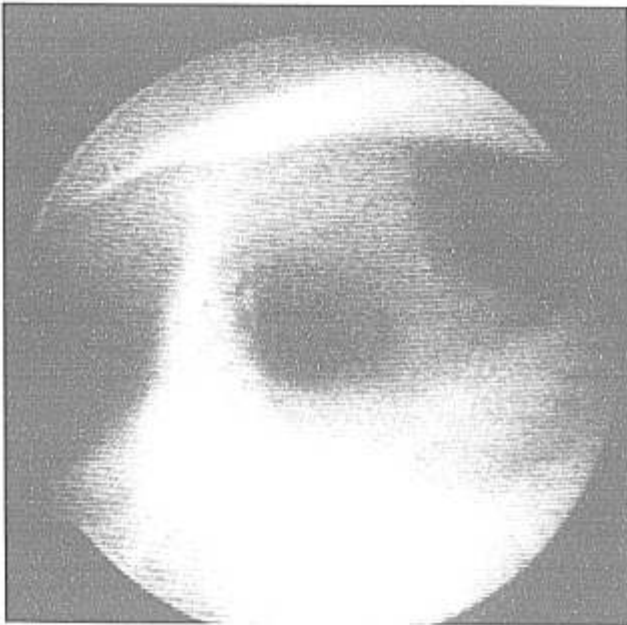


Fig. 1. Photograph of the tracheobronchial tree trifurcation. The right lumen is the right upper lobe bronchus, the middle lumen is the bronchus intermedius, and the left lumen is the left main-stem bronchus.

double-lumen tube was passed over the fiberoptic bronchoscope into the left main-stem bronchus. Auscultatory findings were then consistent with correct placement of a left-sided double-lumen tube.

The case proceeded uneventfully. At the end of the procedure, because of concern that the multiple laryngoscopies and tracheal intubations at the beginning of the procedure might have caused some laryngeal trauma, the double-lumen tube was removed over a tube changer, and an 8.0-mm ID single-lumen endotracheal tube was placed. Examination the following day, using a fiberoptic bronchoscope through the nasopharynx, revealed edema of the arytenoids, vocal cords, and epiglottis. Based on these findings, extubation was delayed until the 4th postoperative day. The patient did well and was discharged to her home on the 16th postoperative day.

Discussion

Difficulty with double-lumen tube placement in a patient with an aberrant right upper lobe takeoff has been described previously.³ Our case, however, is the first reported case of attempted double-lumen tube placement in a patient with a right upper lobe takeoff at the level of the carina that resulted in the passage of the endobronchial lumen into the bronchus intermedius (fig. 2). In retrospect, both the auscultatory and the bronchoscopic findings can be explained by cannulation of the bronchus intermedius with the endobron-

chial portion of the double-lumen tube. When the endobronchial lumen was clamped, breath sounds over the right lower and middle lung fields were markedly decreased, while breath sounds in the right upper lobe and left lung fields were preserved. The tracheal lumen allowed ventilation of the right upper lobe and the entire left lung; when the tracheal lumen was clamped, breath sounds on the left ceased, while those in the right upper lung field were not noticeably diminished, probably because of the transmission of breath sounds from the right middle and lower lobes. The initial bronchoscopic view from the tracheal (right) lumen of the double-lumen tube appeared to confirm the desired position only because the lumen of right upper lobe takeoff was large enough to mimic the right main-stem bronchus. The true left main-stem bronchus was obscured from view by the presence of the endobronchial lumen of the double-lumen tube in the bronchus intermedius, which initially was mistaken for the left main-stem bronchus.

There are several reports in the literature of the auscultatory findings associated with malpositioned double-lumen tubes.^{4,5} Sequences of cuff inflations, lumen clampings, and auscultation that attempt to ensure

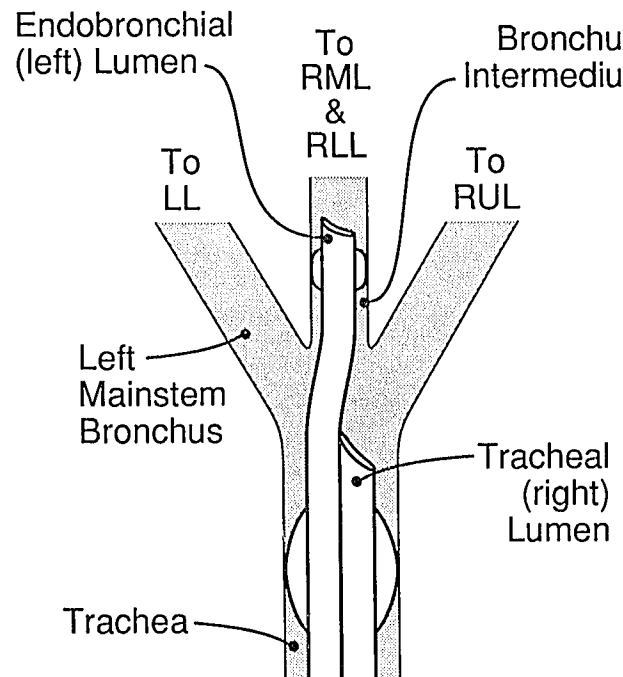


Fig. 2. Schematic drawing of the cannulation of the bronchus intermedius with the endobronchial lumen of the left-sided double-lumen tube.

CASE REPORTS

proper tube placement and function have been described.^{2,6} Because these sequences are not uniformly successful in achieving their goal,⁷ routine use of the bronchoscope to place or to confirm correct placement of a double-lumen tube has been advocated strongly.⁸⁻¹⁰ Malpositioned double-lumen tubes have been reported to be found at bronchoscopy in 38-78% of cases in which auscultatory findings suggested appropriate tube placement.⁸⁻¹¹ In our case, however, the fiberoptic bronchoscope examination findings after the second double-lumen tube insertion proved misleading due to the fact that cannulation of the bronchus intermedius obscured visibility of the left main-stem bronchus. Ultimately, the key to understanding this patient's anatomy and to placing the double-lumen tube correctly was provided only by the use of supracarinal tracheoscopy and subcarinal bronchoscopy.

References

1. Atwell SW: Major anomalies of the tracheobronchial tree. *Chest* 52:611-615, 1967
2. Benumof JL: *Anesthesia for Thoracic Surgery*. Philadelphia, WB Saunders, 1987, pp 230-236
3. Brodsky JB, Mark JBD: Bilateral upper lobe obstruction from a single double-lumen tube. *ANESTHESIOLOGY* 74:1163-1164, 1991
4. Brodsky JB, Shulman MS, Mark JBD: Malposition of left-sided double-lumen endobronchial tubes. *ANESTHESIOLOGY* 62:667-669, 1985
5. Burk WJ III: Should a fiberoptic bronchoscope be used routinely to position a double-lumen tube? *ANESTHESIOLOGY* 68:826, 1988
6. Katz JA, Fairley HB: *Pulmonary surgery, Anesthesia for Thoracic Procedures*. Edited by Marshall BE, Longnecker DF, Fairley HB. Boston, Blackwell Scientific Publications, 1988, pp 363-413
7. Read RC, Friday CD, Eason CN: Prospective study of the Robertshaw endobronchial catheter in thoracic surgery. *Ann Thorac Surg* 24:156-161, 1977
8. Benumof JL: The position of a double-lumen tube should be routinely determined by fiberoptic bronchoscopy (editorial). *J Cardiothorac Vasc Anesth* 7:513-514, 1993
9. Alliaume B, Coddens J, Deloof T: Reliability of auscultation in position of double-lumen endobronchial tubes. *Can J Anaesth* 39:687-690, 1992
10. Lewis JW, Serwin JP, Gabreil FS, Bastanfar M, Jacobsen G: The utility of a double-lumen tube for one-lung ventilation in a variety of noncardiac thoracic surgical procedures. *J Cardiothorac Vasc Anesth* 5:705-170, 1992
11. Cohen E, Goldofsky S, Newstein S, Camunas JC, Thys D: Fiberoptic evaluation of endobronchial tube position: Red rubber vs. polyvinylchloride (abstract). *Anesth Analg* 68:S54, 1989

Anesthesiology

80:1164-1166, 1994

© 1994 American Society of Anesthesiologists, Inc.

J. B. Lippincott Company, Philadelphia

Meningioma as a Cause of Severe and Intractable Postoperative Nausea and Vomiting

Joel Allen, M.D., Ch.B.,* Kerry Siminoski, M.D., F.R.C.P.C.†

POSTOPERATIVE nausea and vomiting accompanies approximately 20-30% of general anesthetics,¹ an association that has been recognized since the introduction of anesthesia.² Most of the literature on the subject

has focused on the role of anesthetic agents, techniques for anesthetic delivery, and new therapies.¹ Severe and intractable postoperative nausea and vomiting is much less common, with an incidence of about 0.1%,³ and has received much less attention.

We report a case of severe and intractable postoperative nausea and vomiting due to meningioma. This case illustrates a cause of these complications not directly related to anesthesia and suggests that extensive investigation may be indicated in some instances.

Case Report

A 76-yr-old woman was admitted for elective total knee replacement. She had been receiving oral hypoglycemic agents for diabetes mellitus and enalapril for hypertension. There was no history of car-

* Medical Resident.

† Assistant Professor, Division of Endocrinology and Metabolism.

Received from the Department of Medicine, University of Alberta, Edmonton, Alberta, Canada. Accepted for publication January 5, 1994. KS is a Scholar of the Alberta Heritage Foundation for Medical Research.

Address reprint requests to Dr. Siminoski: 362 HMRC, University of Alberta, Edmonton, Alberta, Canada T6G 2S2.

Key words: Anesthetic techniques; spinal. Brain; meningioma. Complications: nausea; vomiting.