

Anesthesiology
80:1410-1411, 1994
© 1994 American Society of Anesthesiologists, Inc.
J. B. Lippincott Company, Philadelphia

Kinking of a Right-sided Double-lumen Tube in the Right Upper Lobe Bronchus

To the Editor:—Various designs of right-sided double-lumen bronchial tubes (DLT) are currently available. We report a case in which the special design of a disposable DLT (Sheridan Catheter Corporation, Argyle, NY) is believed to have resulted in an acute ventilation problem.

A 66-yr-old, 180-cm, 98-kg man was scheduled for left pneumonectomy. Preoperative fiberoptic bronchoscopy revealed obstruction of the left mainstem bronchus due to a bronchial tumor. Chest x-rays showed atelectasis of the left lung, a left hilar enlargement, and deviation of the mediastinum to the left. After induction of anesthesia, a 41-French right-sided DLT (Sheridan) was advanced and rotated clockwise until moderate resistance was encountered.

After cuff inflation, chest auscultation revealed asymmetrical breath sounds and absence of sounds over the left chest. Clamping of the tracheal lumen resulted in an increase in peak inspiratory pressure, and breath sounds were present only anteriorly over the right chest. When the clamp was applied to the bronchial lumen, no breath sounds could be heard. Routine fiberoptic bronchoscopy *via* the tracheal lumen of the DLT showed the proximal blue bronchial cuff herniating over the carina, partially obstructing the origin of left mainstem bronchus.

After cuff deflation, and under fiberoptic control, the DLT was slightly advanced until the proximal blue cuff was seen in the right mainstem bronchus, immediately distal to the carina. Mild resistance to further passage was encountered. Both cuffs were reinflated. At that time, ventilation was very difficult. The fiberoptic bronchoscope was then introduced down the bronchial lumen but could not be advanced beyond the first bronchial cuff. It was impossible to visualize either the right upper lobe bronchial orifice or the right bronchial carina. To visualize the exact position of the tube, fluoroscopy was performed, revealing that the tip of the tube was in the right upper lobe bronchus (fig. 1).

Despite numerous attempts, the tube could not be correctly placed into the right mainstem bronchus, and the tube was removed. The right mainstem bronchus was easily reintubated with a 41-French right-sided DLT (Mallinckrodt Laboratories, Athlone, Ireland). The remainder of the anesthetic course was uneventful.

Although the exact mechanism of this problem is unclear, the obstructing tumor could have caused a distortion of the tracheobronchial tree, narrowing the right airway. The bronchial tip of the DLT could therefore have met some resistance, with further advancement provoking a 90° angle into the right upper lobe bronchus. Although the

Sheridan right-sided DLT has been said to permit adequate single-lung ventilation in a larger proportion of cases than other tubes,^{1,2} the design of its side ventilation slot makes it less rigid, allowing a kinking at the level. It has two bronchial cuffs and a side slot larger and longer than that of the Mallinckrodt tubes or Rusch tubes. It thus is easy for the bronchial lumen to become completely plicated between the two cuffs. In our case, it was impossible to advance the fiberoptic bronchoscope beyond the first bronchial cuff.

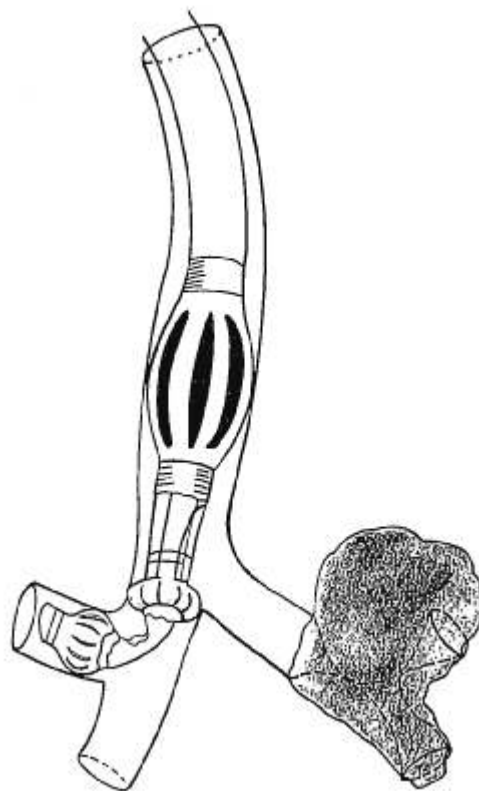


Fig. 1. A right-sided double-lumen endobronchial tube with two endobronchial cuffs was accidentally introduced in the right upper lobe bronchus. The longer right upper lobe ventilation slot could have resulted in kinking of the bronchial lumen, as shown. The tumor completely obstructs the left airway.

* Slinger P, Triolet W: A clinical comparison of three different designs of right-sided double-lumen endobronchial tubes (abstract). *Can J Anaesth* 36:S59, 1989.

CORRESPONDENCE

Michel J. Van Dyck, M.D.
Staff Anesthesiologist

Irène Astiz, M.D.
Resident

Department of Anesthesiology
Catholic University of Louvain
Cliniques Universitaires St-Luc
B-1200 Brussels, Belgium

References

1. Benumof JL, Partridge BL, Salvatierra C, Keating J: Margin of safety in positioning modern double-lumen endotracheal tubes. *ANESTHESIOLOGY* 67:729-738, 1987
2. Benumof JL: Improving the design and function of double-lumen tubes (editorial). *J Cardiothorac Anesth* 2:729-733, 1988

(Accepted for publication March 10, 1994.)

Anesthesiology
80:1411-1412, 1994
© 1994 American Society of Anesthesiologists, Inc.
J. B. Lippincott Company, Philadelphia

Are Only Large Doses of Rocuronium an Alternative to Succinylcholine for Rapid-sequence Induction?

To the Editor:—Magorian *et al.*¹ recently investigated onset times and intubating conditions with three doses (0.6, 0.9, and 1.2 mg · kg⁻¹) of rocuronium, 0.1 mg · kg⁻¹ vecuronium, and 1 mg · kg⁻¹ succinylcholine. No significant difference could be demonstrated between succinylcholine and the two larger doses of rocuronium either in onset time or in intubating conditions at 60 s. This led the authors to conclude that rocuronium 0.9 and 1.2 mg · kg⁻¹ might be an alternative to succinylcholine for rapid-sequence induction. This conclusion is based on the assumption that the twitch response of the adductor pollicis muscle is a "quantifiable and reliable endpoint" defining optimal intubating conditions, whereas intubating scores are a qualitative and rather subjective measure of intubating conditions. This conclusion does not adequately account for the observation that all patients who received 0.6 mg · kg⁻¹ rocuronium in this study showed excellent intubating conditions. Findings similar to these have been reported for the same dose of rocuronium in larger numbers of patients, 65-97% of whom had excellent intubating conditions irrespective to the onset time.²⁻⁴

We question the reliability of onset time in predicting optimal intubating conditions, on the following grounds. (1) Onset time is significantly influenced by the stimulation mode⁵ and possibly also by the speed of injection, which seldomly is standardized in clinical studies. (2) Relaxation of the masseter, intrinsic laryngeal muscles, or diaphragm and the depth of anesthesia are more likely to determine intubating conditions than is the block of the adductor pollicis muscle. (3) The predictive value of the onset time appears to be questionable also with other agents. With mivacurium 0.15 and 0.2 mg · kg⁻¹, intubating conditions at 2 min (despite complete peripheral block) have been found to be unacceptable in 100 and 35% of patients, respectively.⁶

We also think that the number of patients in this study was too small to demonstrate the existing differences at significant levels among the various groups. This limitation is illustrated by the similarity in intubating conditions at 60 s even between the vecuronium and succinylcholine groups. That the anesthetic regimen is not de-

scribed entirely clearly makes it difficult to interpret the findings. The use of fentanyl as a premedicant was mentioned in the abstract, but the dose was not specified.

Last but not least, to make recommendations for dosing for rapid-sequence induction based on this study may not be appropriate because 5-10 min elapsed between induction of anesthesia and intubation, which was attempted 60 s after administration of a relaxant. Therefore, "rapid-sequence intubation" would better describe the experimental conditions in this study.

In our opinion, the effect of onset time in relation to intubating conditions should be reconsidered. Studies in a large series of elective patients can give guidance. Only after large numbers of patients have been treated by a variety of anesthesiologists in actual emergency situations will it be possible to define recommended doses for rapid-sequence induction.

H. J. Sparr, M.D.

G. Mitterschiffthaler, M.D.

Clinics for Anesthesia and General Intensive Care Medicine
University of Innsbruck
Anichstrasse 35
A-6020 Innsbruck, Austria

References

1. Magorian T, Flannery KB, Miller RD: Comparison of rocuronium, succinylcholine, and vecuronium for rapid-sequence induction of anesthesia in adult patients. *ANESTHESIOLOGY* 79:913-918, 1993
2. Cooper R, Mirakhor RK, Clarke RSJ, Boules Z: Comparison of intubating conditions after administration of ORG 9426 (rocuronium) and suxamethonium. *Br J Anaesth* 69:269-273, 1992
3. Huizinga ACT, Vandenbrom RHG, Wierda JMKH, Hommes FDM,