

A Model for Fatal Halothane Hepatitis in the Guinea Pig

Richard C. Lind, M.S.,* A. Jay Gandolfi, Ph.D.,† Pauline de la M. Hall, M.B.B.S., F.R.C.P.A.‡

Background: In the guinea pig, depleting hepatic glutathione before inhaling subanesthetic 0.1% halothane increases covalent binding of halothane biotransformation intermediates to hepatic protein and potentiates resultant liver injury. Because inhalation of a higher concentration of halothane is known to produce greater levels of covalent binding than with subanesthetic halothane, this study was undertaken with 0.25–1.0% halothane concentrations to further examine glutathione depletion as an etiology for halothane hepatitis.

Methods: Male Hartley guinea pigs were injected intraperitoneally with either vehicle control solution (Veh) or 1.6 g/kg buthionine sulfoximine (BSO), to decrease hepatic glutathione by >80%, 24 h before a 4-h exposure to 0.25%, 0.5%, or 1.0% (v/v) halothane with 40% O₂. Some BSO-pretreated animals also received 2.0 g/kg glutathione monoethyl ester (GEE), intraperitoneally, 2 h before inhaling halothane to replenish hepatic glutathione.

Results: Glutathione-depleted animals developed significantly worse hepatic injury with each halothane concentration. One-third to one-half of BSO + halothane-treated animals developed fatal submassive to massive hepatic necrosis. Covalent binding of halothane intermediates to hepatic protein increased by 45% in BSO + 1.0% halothane-treated guinea pigs. Administration of GEE to BSO-pretreated animals before 1.0% halothane decreased binding to protein and blunted development of liver necrosis. Following Veh + 1.0% halothane, hepatic glutathione was found to be decreased by 60%.

Conclusions: Glutathione would appear to help protect hepatocytes to some degree from covalent binding by reactive

halothane biotransformation intermediates. These studies present the first animal model to produce fatal halothane-induced hepatic necrosis. (Key words: Anesthetics, volatile: halothane. Animals: guinea pig. Binding: reactive intermediates. Biotransformation: halothane. Glutathione: depletion; hepatic. Liver: submassive necrosis; massive necrosis.)

IN more than 30 yr of use as an inhalation anesthetic, halothane has been implicated as a causative agent for hepatic injuries that range from mild, acute insults in approximately 20% of patients,^{1,2} to a rare, and often fatal, fulminant hepatitis in 1:7,000–30,000 administrations.^{3,4} The mild form of hepatic injury, which has been demonstrated by increases in liver enzymes in the blood, has been speculated as being due to the covalent binding of cytochrome P-450-generated reactive halothane biotransformation intermediates to subcellular macromolecules, causing a direct injury.^{1,2} On the other hand, it is generally considered that fulminant halothane hepatitis is due to an idiosyncratic autoimmune reaction brought about by the formation of neoantigens that have been generated by covalent binding of halothane biotransformation intermediates.⁵

Numerous animal models have been developed in attempts to elucidate the pathogenic mechanisms involved in halothane-associated liver injury.⁶ Although the majority of studies have been carried out in rats, this species has proven less than ideal due to the extensive manipulations required to obtain hepatic injury and the lack of a clear-cut mechanism for injury.⁶ However, the guinea pig appears to be a more sensitive animal model for halothane hepatotoxicity; a 4 h anesthesia with 1% halothane consistently produces acute zone 3 necrosis in 50% or more of naive animals.^{7–11} Several factors have been shown to affect the susceptibility of guinea pigs to the hepatic injury including: strain, gender, age⁸ and heredity.¹² We have recently shown that even inhalation of subanesthetic concentrations (0.25%, 0.10%) of halothane for 4 h produces hepatic injury in these animals.¹¹ The mechanism of injury appears to be due to covalent binding to hepatic

* Senior Research Specialist, Department of Anesthesiology, College of Medicine, University of Arizona, Tucson, Arizona.

† Professor of Anesthesiology, Pharmacology, and Toxicology, Department of Anesthesiology, College of Medicine, University of Arizona, Tucson, Arizona.

‡ Senior Consultant, Pathology Department, Flinders Medical Centre, Bedford Park, South Australia.

Received from the Department of Anesthesiology, College of Medicine, University of Arizona, Tucson, Arizona. Conducted at the University of Arizona. Supported by National Institutes of Health grant GM45678. Presented in part at the 43rd annual meeting of the American Association for the Study of Liver Diseases, Chicago, Illinois, November 1992, and the 32nd annual meeting of the Society of Toxicology, New Orleans, Louisiana, March 1993.

Address reprint requests to Mr. Lind: Department of Anesthesiology, University of Arizona Health Sciences Center, 1501 North Campbell Avenue, Tucson, Arizona 85724.

FATAL HALOTHANE HEPATITIS IN GUINEA PIGS

proteins by the oxidative biotransformation intermediate, trifluoroacetyl acid chloride.¹⁰ Hepatic glutathione (GSH), which normally reacts with and detoxifies acid chloride metabolic intermediates,¹³ may play a role in protecting against damage caused by the reactive intermediates of halothane; depletion of hepatic GSH with buthionine sulfoximine before subanesthetic (0.1%) halothane has been shown to increase the covalent binding of the reactive intermediates to protein and exacerbate resultant hepatotoxicity in guinea pigs.¹⁴ Since inhalation of a higher concentration of halothane is known to produce a greater degree of covalent binding than subanesthetic halothane in naive guinea pigs,¹⁵ this study was undertaken using 0.25–1.0% halothane to further delineate glutathione depletion as an etiology for halothane hepatitis.

Materials and Methods

Animals and Pretreatment

Male, outbred guinea pigs (600–700 g, Sasco, Omaha, NE) were treated in accordance with a protocol approved by the University of Arizona Animal Care Committee. All animals were provided food and water *ad libitum* and treatments were made at the same time of day to avoid possible effects of diurnal variations on hepatic GSH levels. Hepatic GSH was depleted for a prolonged period of time (48–72 h)¹⁶ by intraperitoneal injection of 1.6 g/kg dl-buthionine-S, R-sulfoximine (BSO; Schweizerhall, Piscataway, NJ) dissolved in water ($pH = 8.5$) and administered at volume of 10 ml/kg. Vehicle (Veh) control guinea pigs received an equal volume of water containing sodium hydroxide equivalent to that required for dissolution of BSO, adjusted to $pH = 8.5$ with hydrochloric acid. Injection of either solution was made 24 h before halothane exposure. Hepatic GSH was replenished in BSO-pretreated guinea pigs with 2 g/kg glutathione monoethyl ester- $\frac{1}{2}$ H₂O (GEE) dissolved in water ($pH = 6.5$) and administered intraperitoneally at a volume of 6 ml/kg 2 h before halothane exposure. GEE was synthesized by the sulfuric acid method of Anderson and Meister, desalted with Dowex-1-bicarbonate, and checked for purity by thin layer chromatography.¹⁷

Exposure Conditions

All inhalation exposures to halothane (Halocarbon Laboratories, Worth Augusta, SC) or enflurane (Ethrane; Anaquest, Murray Hill, NJ) were for 4 h and were car-

ried out in a 180-l exposure chamber using a flow rate of 6 l/min.¹¹ Oxygen concentrations were 40% (balance N₂). Body temperatures were monitored by rectal probes during 1.0% exposures and maintained at near normothermia by external heating, as previously described.⁹ This was not done with other halothane concentrations since they did not provide sufficient anesthesia. Multiple blood samples were collected from each guinea pig by toenail bleeding.¹⁰ Animals were killed by lethal pentobarbital injection whereupon cardiac blood was drawn and livers removed. Transverse slices of hepatic tissue were fixed in neutral buffered formalin, and remaining liver frozen immediately on dry ice. Plasma samples were analyzed for plasma isocitrate dehydrogenase (ICDH) activity (Procedure 153-UV; Sigma Chemical, St. Louis, MO) and for concentrations of the halothane metabolites, trifluoroacetic acid¹⁸ and inorganic fluoride ion.⁷ Hepatic tissue slices were processed and embedded in paraffin. Five micron sections were cut and stained by hematoxylin and eosin (H&E) and Gordon and Sweet's method for reticulin.¹⁹ Separate portions of tissue were post-fixed in osmium tetroxide to allow visualization of fatty vacuolization.²⁰ All slides were coded before being assessed by a hepatopathologist (PH). Liver injury was graded in severity as: normal-within normal limits with 0 to 3 foci of hepatocyte necrosis; mild-occasional (>3) to multiple foci of hepatocyte necrosis; moderate-areas of necrosis involving some but not all of the zone 3 (perivenular) region; marked-confluent necrosis of zone 3; submassive-confluent zone 3 necrosis with variable necrosis of zones 2 and 1 (periportal region) but less extensive than massive; massive-necrosis of virtually all hepatocytes. Livers were stored at -80°C before analysis of hepatic reduced and oxidized glutathione (GSH and GSSG, respectively) by an enzymatic method²¹ and assessment of covalent binding by reactive halothane biotransformation intermediates to hepatic protein and lipid using an assay for bound organic fluorine.¹⁰

Experimental Protocol

Experimental conditions for all treatment groups are listed in table 1. For evaluation of the hepatotoxic potential of halothane on GSH depleted guinea pigs, a series of experiments were performed with groups containing both Veh and BSO pretreated animals inhaling 0.25%, 0.5%, or 1.0% halothane, 40% O₂ for 4 h. (treatment groups 1–8). Blood samples were collected immediately after exposure (0 h) and every 24

Table 1. Experimental Treatment Groups

Group	Pretreatment*	Halothane Concentration† (%)	Endpoint‡ (h)	n§	Experiments¶ (n)
1	Veh	0.25	96	4	1
2	BSO	0.25	96	5	1
3	Veh	0.5	96	4	2
4	BSO	0.5	96	4, 6	2
5	Veh	1.0	96	4	3
6	BSO	1.0	96	4	3
7	Veh	1.0	192	4	1
8	BSO	1.0	192	7	1
9	Veh	1.0	10	4	1
10	BSO	1.0	10	4	1
11	BSO + saline	1.0	96	4	2
12	BSO + GEE	1.0	96	4	2
13	BSO + saline	1.0	10	4	1
14	BSO + GEE	1.0	10	4	1
15	None	—	-4, 10	8	1
16	BSO	—	-4, 8	4	1
17	BSO + GEE	—	-4 to 6	12	1
18	BSO	(2.5% enflurane)	96	4	1

* Veh = 10 ml/kg vehicle control solution, intraperitoneally, 24 h before start of halothane exposure; BSO = 1.6 g/kg buthionine sulfoximine, intraperitoneally, 24 h before start of halothane exposure; saline = 6 ml/kg saline, intraperitoneally, 2 h before start of halothane exposure; GEE = 2.0 g/kg glutathione ethyl ester, intraperitoneally, 2 h before start of halothane exposure.

† Exposures were for 4 h at 40% O₂.

‡ Time relative to the end of the 4-halothane exposure, when animals were killed.

§ Number of animals in each experiment.

¶ Number of separate experiments carried out under treatment conditions.

h thereafter until the animals were killed which was either 96 h after (groups 1–6) or 192 h after (groups 7 and 8), at which time liver tissue samples were also taken. To measure the effect of GSH depletion on the biotransformation and covalent binding of halothane, Veh and BSO pretreated guinea pigs inhaled 1.0% halothane, 40% O₂, for 4 h and were killed 10 h after (groups 9 and 10), when the majority of halothane biotransformation had occurred.¹⁵

Hepatic GSH was replenished in depleted (BSO-pretreated) guinea pigs by administration of GEE 2 h before inhalation of 1.0% halothane, 40% O₂ for 4 h (groups 12 and 14) while others received saline in lieu of GEE before halothane (groups 11 and 13). After one exposure, BSO + saline and BSO + GEE pretreated animals were bled at 0 h and every 24 h thereafter until they were killed 96 h after to allow evaluation of the hepatotoxic response (groups 11 and 12). Halothane biotransformation and covalent binding were measured in similarly pretreated animals that were killed 10 h after 1.0% halothane, 40% O₂ for 4 h (groups 13 and 14).

Control groups included untreated guinea pigs (group 15) that were killed at the time of halothane exposure (N = 4) and 10 h after the end of exposure (N = 4). They provided normal liver tissue, control values for both plasma ICDH activity and hepatic GSH content, and background values for both plasma metabolite concentrations and bound organic fluorine in the liver. The GSH depleting potential of BSO was measured in animals that received BSO-only and were killed 24 (N = 2) and 36 h (N = 2) after BSO injection which was equivalent to -4 h and 8 h relative to the end of halothane exposure (group 16). The ability of GEE to replenish hepatic GSH was observed in BSO-treated guinea pigs that were administered GEE at the same time as groups 12 and 14 and then were killed 2, 4, 6, 8, 10 and 12 h after GEE injection, -4, -2, 0, 2, 4, and 6 h relative to the end of halothane exposure (N = 2 at each time point, group 17). The effect of a 4 h anesthesia with 2.5% enflurane, 40% O₂, was evaluated in GSH depleted guinea pigs (N = 4) that were bled 0, 24, 48, and 72 h after exposure and killed 96 h after (group 18).

FATAL HALOTHANE HEPATITIS IN GUINEA PIGS

Statistical Analysis

All values are reported as mean \pm SEM. Statistical analysis was performed by analysis of variance (ANOVA) with a Newman-Keuls multiple comparison test or by a Student's *t*-test. A $P < 0.05$ was considered significant.

Results

Of the BSO-pretreated guinea pigs that inhaled either 0.25, 0.5 or 1.0% halothane (groups 1–8), $\frac{1}{3}$ to $\frac{1}{2}$ of the animals died or became moribund and were killed following exposure (table 2), most within 48–72 h. The livers of all these animals revealed the presence of submassive to massive hepatic necrosis with no differences between halothane concentrations in the incidence of this injury. Comparisons of peak plasma ICDH activity, which occurred 24–48 h after exposure, demonstrated greater ICDH activity in those that developed fatal hepatic injury than in those that did not (fig. 1). Overall, the BSO + halothane-treated animals (groups 2, 4, and 6) had a significantly greater degree of hepatic injury than that observed in Veh + halothane animals (groups 1, 3, and 5) for each concentration of halothane (table 3). Again, there were no differences in the incidence of necrosis between halothane concentrations within pretreatment groups.

Livers from guinea pigs that received Veh + halothane (groups 1, 3, and 5) ranged from normal in appearance to having marked injury with confluent zone 3 (cen-

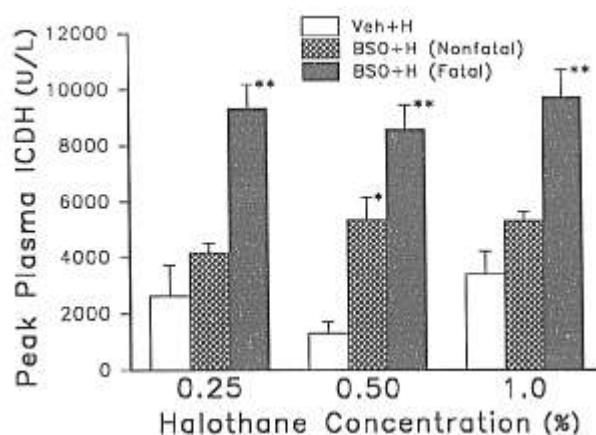


Fig. 1. Peak plasma ICDH activity following halothane exposure. Guinea pigs were pretreated with either vehicle control solution (groups 1, 3, 5, 7) or 1.6 g/kg BSO (groups 2, 4, 6, 8), intraperitoneally, 24 h before halothane exposure for 4 h at 40% O₂. BSO-pretreated animals are divided into groups that either developed fatal liver injury (Fatal) or did not (Nonfatal). Values are mean \pm SEM, N = 2–8. All groups $P < 0.05$ versus combined untreated control (group 15) and BSO control values (group 16) (37 ± 2 U/L, N = 12). * $P < 0.01$ versus the vehicle + halothane group at the same halothane concentration. ** $P < 0.01$ versus other groups at the same halothane concentration.

trilobular) necrosis (table 3). The much more severe submassive to massive necrosis observed in many of the BSO + halothane animals (groups 2, 4, 6, and 8) extended through zone 2 with only variable survival of zone 1 (periportal) hepatocytes (fig. 2). Fatty vacuolization of the surviving hepatocytes was evident as confirmed by staining with osmium tetroxide (data not shown). A reticulin stain of liver from a BSO-pretreated guinea pig found moribund 96 h after 1.0% halothane exposure highlights the extensive loss of hepatocytes resulting from submassive necrosis and collapse of the reticulin framework with formation of passive septa linking terminal hepatic venules to adjacent venules and to portal tracts (fig. 3). Of the guinea pigs that developed submassive necrosis, $\frac{3}{5}$ with 1.0% halothane and $\frac{1}{5}$ with 0.5% halothane appeared healthy when killed 96 h after exposure.

In the experiment carried out to 192 h after 1.0% halothane, fatal hepatic injury developed in $\frac{4}{7}$ of the BSO-pretreated animals (group 8); three had submassive necrosis, one had massive necrosis. The guinea pig with massive injury died somewhere between 120–144 h after halothane and displayed widespread hemorrhagic necrosis, a considerable amount of collapse resulting in approximation of the terminal hepatic ve-

Table 2. Incidence of Fatal Halothane Hepatitis in Glutathione-depleted Guinea Pigs

Halothane Concentration* (%)	Group†	Experiments‡ (n)	Incidence of Fatal Hepatitis§
0.25	2	1	2/5
0.5	4	2	5/10
1.0	6	3	3/12
1.0	8	1	4/7

* Exposures were for 4 h at 40% O₂.

† Treatment group numbers; see table 1.

‡ Number of separate experiments carried out under treatment conditions.

§ Number of animals found moribund or dead and displaying submassive to massive hepatic necrosis/total number of GSH-depleted guinea pigs exposed to halothane.

There is no significant difference in the incidence of fatal hepatitis between halothane concentrations. Fatal submassive to massive necrosis was not observed in animals that received Veh + halothane (groups 1, 3, 5, 7, total n = 28), BSO-only (group 16, n = 4), or BSO + 2.5% enflurane (group 18, n = 4).

Table 3. Histopathologic Evaluation of Hepatic Tissue After Halothane Exposure

Pretreatment*	Halothane Concentration† (%)	Group‡	Histopathologic Evaluation§					
			Normal	Mild	Moderate	Marked	Submassive	Massive
Veh	0.25	1	1	1	—	2	—	—
	0.5	3	5	2	1	—	—	—
	1.0¶	5	—	5	2	5	—	—
BSO**	0.25	2	—	—	1	2	2	—
	0.5	4	—	—	—	4	5	1
	1.0¶	6	—	—	—	6	6	—

* Vehicle control solution or 1.6 g/kg BSO, intraperitoneally, 24 h before halothane exposure.

† Exposures were for 4 h at 40% O₂.

‡ Treatment group numbers; see table 1.

§ Liver injury was graded as: normal = no damage; mild = occasional to multiple foci of necrosis; moderate-limited zone 3 necrosis; marked-confluent zone 3 necrosis; submassive-zone 3 necrosis extending into zones 2 and 1; massive-necrosis of virtually all hepatocytes.

¶ Data for 1.0% halothane does not include the experiment carried out to 192 h after exposure (groups 7 and 8) in which 4/7 BSO + halothane animals became moribund or died; (3 had submassive necrosis, 1 was massive) because of healing of injury in the remaining animals. All groups $P < 0.05$ versus untreated (group 15, 8/8 = normal) and BSO = only, (group 16, 3/4 = normal, 1/4 = mild) control groups except the Veh + 0.5% halothane group.

** $P < 0.05$ for all BSO pretreated groups versus vehicle pretreated at each halothane concentration. There is no significant difference between halothane concentrations within pretreatment groups.

nules to the portal tracts, and prominent ductular proliferation in the periportal regions. The BSO + halothane animals (group 8) that survived until 192 h after exposure, still showed evidence of zone 3 inflammation and collapse while the Veh + halothane animals (group 7) had virtually recovered by 192 h and showed only a minor mononuclear infiltrate and focal hepatocyte dropout as evidence of the recent injury. Since these animals were allowed to survive past the 96 h endpoint

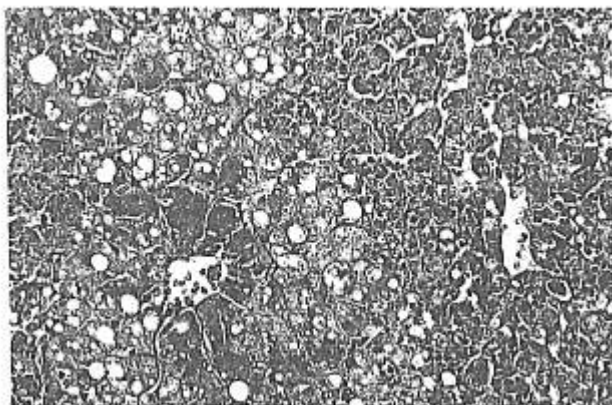


Fig. 2. Photomicrograph of liver from a guinea pig that received BSO 24 h before 0.25% halothane (group 2). Exposure was at 40% O₂ for 4 h. Tissue was obtained 72 h after exposure when the animal was found moribund. The liver shows submassive necrosis with variable sparing of zone 1 and 2 hepatocytes which also show fatty change (hematoxylin and eosin, magnification $\times 180$).

used in the other experiments, data on degree of injury is not included in table 3.

Measurement of hepatic GSH concentrations in group 16 demonstrated that BSO-pretreatment caused a persistent depletion of $>80\%$, both at the time of halothane exposure and in the hours following (fig. 4). The lack of GSH was accompanied by an increase of 45% in co-

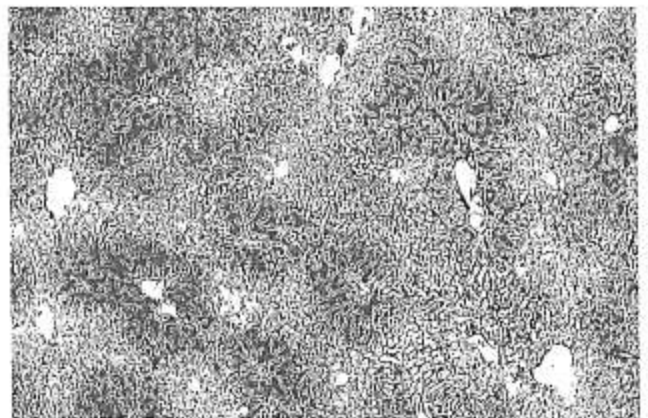


Fig. 3. Photomicrograph of liver from a guinea pig that received BSO 24 h before 1.0% halothane (group 6). Exposure was at 40% O₂ for 4 h. Tissue was obtained 96 h after exposure. The liver shows confluent areas of collapse around terminal hepatic venules due to submassive necrosis. Formation of passive septa extending through the liver acini has occurred. Surviving zone 1 hepatocytes (darker staining areas) are seen in the periportal regions (Gordon and Sweets' reticulin stain, magnification $\times 40$).

FATAL HALOTHANE HEPATITIS IN GUINEA PIGS

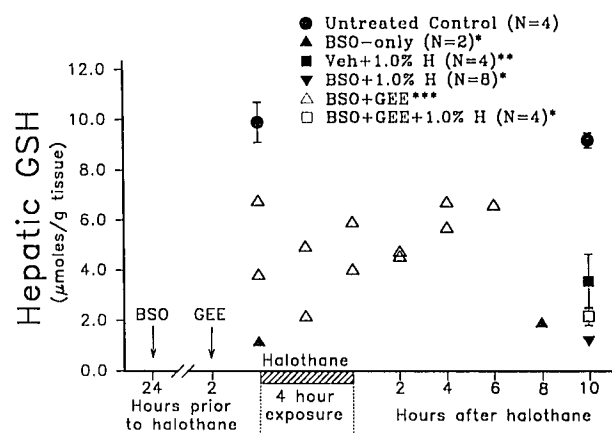


Fig. 4. Hepatic GSH concentrations in guinea pigs. Time of BSO (1.6 g/kg, intraperitoneally) and GEE (2.0 g/kg, intraperitoneally) injections indicated by arrows. Exposures were to 1.0% halothane (H), 40% O₂. Untreated control (group 15); BSO-only (group 16); Veh + 1.0% H (group 9); BSO + 1.0% H (groups 10 and 13); BSO + GEE (group 17); BSO + GEE + 1.0% H (group 14). All values are mean \pm SEM. * P < 0.01 versus untreated control groups. ** P < 0.05 versus untreated control and BSO + 1.0% H values. *** P < 0.05 for combined values (5.0 ± 0.4 μ moles GSH/g tissue, $N = 11$) versus all other groups.

valent binding of reactive halothane biotransformation intermediates (bound organic fluorine) to hepatic protein in BSO + 1.0% halothane-treated animals (groups 10 and 13) (fig. 5). However, binding to lipid was not significantly affected (fig. 5). Injection of GSH-depleted guinea pigs with GEE (group 17) produced a prolonged restoration of hepatic GSH to a mean value that was approximately 50% of untreated control values (fig. 4). The animals that received BSO + GEE + 1.0% halothane (group 14) demonstrated covalent binding to hepatic protein following halothane that was equivalent to the values obtained from the Veh + 1.0% halothane animals (group 9) and thus significantly less than the values from those that received BSO + 1.0% halothane (groups 10 and 13) (fig. 5). The changes in covalent binding brought about by depleting and restoring hepatic GSH were not due to changes in halothane biotransformation as indicated by plasma metabolite concentrations. Plasma TFA was $1,850 \pm 50$ ($N = 4$), $1,850 \pm 81$ ($N = 8$) and $1,750 \pm 210$ ($N = 4$) μ M 10 h after halothane exposure in Veh + 1.0% halothane (group 9), BSO + 1.0% halothane (groups 10 and 13) and BSO + GEE + 1.0% halothane (group 14)-treated animals, respectively, while plasma fluoride ion was 6.5 ± 0.4 , 4.9 ± 0.5 and 5.4 ± 2.0 μ M, respectively.

Replenishment of GSH with GEE also produced a significant reduction in the severity of hepatic injury re-

sulting from 1.0% halothane exposure as demonstrated by plasma ICDH activity and the incidence of hepatic necrosis (table 4). In the BSO + saline + 1.0% halothane animals (group 11), 1/8 animals developed fatal submassive hepatitis while 0/5 of those that received BSO + GEE + 1.0% halothane (group 12) did. Unfortunately, problems arose with the use of GEE in this particular experiment. One guinea pig suffered a fatal pulmonary hemorrhage shortly after injection of GEE. Two others became sickly and were killed a few days after exposure, but showed no evidence of hepatic necrosis beyond small scattered foci (mild injury). Values from these animals were not utilized in the study and thus there are only five animals in this group. These problems were not observed in the animals used for evaluating covalent binding. Of those used to measure the ability of GEE to replenish hepatic GSH after depletion with BSO (group 17), 1/12 died a few hours after injection of GEE and thus there is only a single value at the last time point for the BSO + GEE group in figure 4.

Inhalation of 1.0% halothane decreased hepatic GSH concentrations. At 10 h after exposure, Veh + 1.0% halothane-treated guinea pigs (group 9) exhibited a 60% reduction in GSH (fig. 4). Those receiving BSO + GEE + 1.0% halothane (group 14) also displayed a decrease in GSH of nearly 60% from concentrations found in BSO + GEE-treated animals (group 17) (fig. 4). The BSO + 1.0% halothane-treated guinea pigs

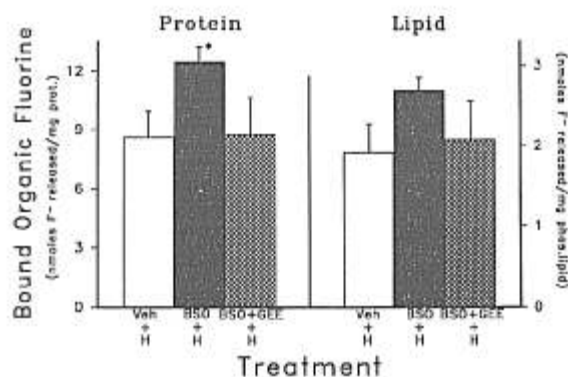


Fig. 5. Covalent binding of reactive halothane biotransformation intermediates to hepatic protein and lipid. Values are 10 h after exposure to 1.0% halothane, 40% O₂ for 4 h. Veh + H-vehicle control solution, intraperitoneally, 24 h before halothane (group 9). BSO + H-1.6 g/kg BSO, intraperitoneally, 24 h before halothane (groups 10 and 13). BSO + GEE + H-2.0 g/kg GEE, intraperitoneally, 22 h after BSO injection followed by halothane exposure 2 h later (group 14). Values are mean \pm SEM. $N = 4-8$. * P < 0.05 versus other treatment groups.

Table 4. Effect of Glutathione Monoethyl Ester on Halothane-induced Hepatic Injury in Glutathione-depleted Guinea Pigs

Pretreatment	Peak Plasma ICDH (U/L)	Histopathologic Evaluation				
		Normal	Mild	Moderate	Marked	Submassive
BSO*	5,560 ± 465	—	—	—	7	1†
BSO + GEE‡	1,140 ± 761	4	—	1	—	—

BSO = 1.6 g/kg BSO, intraperitoneally, 24 h before 1.0% halothane, 40% O₂, for 4 h (group 11); GEE = 2.0 g/kg GEE, intraperitoneally, 2 h before halothane (group 12).

† Evaluation 96 h after halothane exposure; Normal = no damage; Mild = occasional to multiple foci of necrosis; Moderate = limited zone 3 necrosis; Marked = confluent zone 3 necrosis; Submassive = zone 3 necrosis extending into zones 2 and 1.

‡ Fatal hepatitis. Values are mean ± SEM.

* $P < 0.01$ versus untreated control (group 15) and BSO = only animals (group 16) for both plasma ICDH (combined values = 37 ± 2 U/L, $n = 12$) and incidence of necrosis (untreated control = 8/8 = normal, BSO only = 3/4 = normal, 1/4 = mild).

‡ $P < 0.01$ versus BSO + halothane group for both peak plasma ICDH and incidence of necrosis.

(groups 10 and 13) did not develop a further decrease in GSH from those that received BSO-only (group 16). Values obtained for oxidized glutathione (GSSG) were only $1.8 \pm 0.2\%$ ($N = 35$) of the amount of GSH in all of the groups measured except for the Veh + 1.0% animals that were killed 10 h after exposure (group 9). This group demonstrated GSSG values that were $6.0 \pm 1.6\%$ ($N = 4$) of GSH.

Neither treatment with BSO-only (group 16), BSO + GEE (group 17) nor BSO + enflurane (group 18) caused significant hepatic injury. Of the control group treated with BSO-only and killed 24 and 36 h after injection (group 16), 1/4 displayed some scattered foci of necrosis in the liver ("mild" injury). Of those that received GEE 22 h after BSO and were killed 2 to 12 h thereafter (group 17), only 1/11 exhibited some foci of necrosis. The remainder of the livers were normal in appearance. All of the BSO + enflurane guinea pigs (group 18) presented normal appearing livers 96 h after anesthesia. None of these groups differed from the untreated controls (group 15; 8/8 "normal") in incidence of hepatic injury. In addition, plasma ICDH activity in the BSO-only-treated animals (group 16; 42 ± 4 U/L, $N = 4$) was not different from untreated control values (group 15; 34 ± 2 U/L, $N = 8$). The groups that received either the combination of BSO + GEE (group 17) or BSO + enflurane (group 18) developed slight increases in plasma ICDH but values did not exceed 80 and 60 U/L, respectively.

Discussion

Although a number of animal models of halothane-associated hepatotoxicity have been developed with

differing proposed mechanisms of injury,⁶ none have ever generated a fatal hepatitis such as described in this study. The development of fatal hepatic injury occurred at an incidence of 37–50% in GSH-depleted guinea pigs that inhaled halothane concentrations ranging from 0.25% to 1.0%. Several animals killed at 96 h after exposure displayed submassive necrosis but appeared healthy at the time. Their condition may well have progressed to a fatal hepatitis since one animal in the protracted (192 h) experiment did not die until more than 120 h after halothane. Consistent with our previously proposed mechanism of covalent binding by reactive biotransformation intermediates to protein for halothane-associated hepatotoxicity in the guinea pig,^{10,14} it was found that binding to hepatic protein was increased by 45% in the GSH-depleted animals following 1.0% halothane even though the extent of biotransformation was unaltered. Replenishment of GSH with GEE before halothane reduced both the degree of covalent binding and the extent of subsequent hepatic injury. As previously observed,^{10,14} covalent binding to lipid by free radical intermediates would not appear to be a significant factor in the evolution of the injury. Nor would anesthesia, per se, as no hepatic injury developed in GSH-depleted guinea pigs exposed to 2.5% enflurane. Since anesthesia with 0.95% halothane has been shown to greatly decrease the hepatic blood flow and oxygenation in guinea pigs, the possibility exists for hepatic oxygen deprivation being a mechanism of injury.²² This is unlikely because it has been demonstrated that inhalation by naive guinea pigs of 1.0% halothane with 10% O₂, conditions that should further reduce hepatic oxygenation, leads to an amelioration of the centrilobular necrosis that is normally observed

FATAL HALOTHANE HEPATITIS IN GUINEA PIGS

in 50% of the animals.¹⁰ In addition, it has been shown in dogs that halothane-induced changes in liver blood flow are dose dependent.²³ In this study, no differences in the incidence or severity of liver injury were seen between wide ranging concentrations of halothane. However, it is likely that other adverse effects resulting from decreased hepatic GSH could have contributed to the potentiation of hepatotoxicity, including increased susceptibility to activated oxygen and peroxides released by stimulated Kupffer and inflammatory cells²⁴ as well as intracellular enzyme dysfunction caused by increased disulfide bond formation.²⁵

The results of this study, as well as previous findings,¹⁴ are indicative of a role for hepatic GSH in affecting the degree of binding to protein by the trifluoroacetyl acid chloride intermediate. GSH is known to react with the acid chloride biotransformation intermediates of other organohalogens.¹³ Exposure of guinea pigs to 1.0% halothane was found, in this study, to decrease hepatic GSH by 60%. This occurred in both the Veh + 1.0% halothane and BSO + GEE + 1.0% halothane animals (groups 9 and 14). The loss of GSH was not due to "oxidative stress" as GSSG concentrations were only 5–10% and less than 3% of GSH concentrations in the two groups, respectively. We have previously reported that exposure to a subanesthetic concentration (0.1%) of halothane did not decrease hepatic GSH in the guinea pig.¹⁴ This is most likely due to the lesser total amount of halothane biotransformation that occurs with 0.1% halothane than with 1.0%.¹⁵ In addition, use in this study of a glutathione-specific enzymatic assay that employs glutathione reductase²¹ produced values for hepatic GSH that were both more consistent and more in agreement with literature¹⁶ than those obtained previously with a fluorometric assay.¹⁴ Analysis of hepatic tissue with Ellman's assay for nonprotein sulfhydryl also produce findings similar to those reported here (unpublished results).

While these findings, as well as others involving *in vitro* microsomal incubations,²⁶ indicate a reaction between the trifluoroacetyl acid chloride intermediate and GSH, the role of GSH in acute halothane hepatotoxicity is contentious, at best. Other hepatotoxins whose biotransformation intermediates are detoxified by GSH, such as acetaminophen and bromobenzene, must first extensively (>80%) deplete GSH before covalent binding and toxicity occur.^{27,28} However, in the guinea pig, both binding of halothane intermediates and hepatic injury occur without GSH being as extensively depleted. This would explain why attempts to protect

the liver by augmentation of hepatic GSH with GEE and N-acetylcysteine have not proven to be protective in the guinea pig model (unpublished results). As seen in this study, GSH does prevent a portion of the covalent binding of trifluoroacetyl acid chloride to protein; when GSH was severely depleted by BSO (>80%), binding to protein increased by 45%. While products formed by the reaction of GSH with the metabolic intermediates of either acetaminophen or bromobenzene are stable and have been observed,^{29,30} this has not been the case with halothane as the putative trifluoroacetyl-glutathione ester would be extremely reactive. In fact, trifluorothioesters are commonly used to trifluoroacetylate proteins.³¹ Thus a trifluoroacetyl-glutathione ester may react to some extent with subcellular protein and be responsible for some covalent binding, but react to a lesser degree than free trifluoroacetyl acid chloride does. The fate of the GSH lost by 10 h after halothane exposure is unknown but does not appear to be due to oxidation as a concomitant increase in GSSG did not occur. In this study, the BSO-pretreated animals that had very low GSH at the time of 1.0% halothane exposure, did not display a further decrease in GSH. This would indicate that the GSH remaining in the livers of these animals was sequestered in a pool, most likely the mitochondria,³² and was thus unavailable to react with biotransformation intermediates.

With the addition of the submassive to massive necrosis observed in the BSO + halothane-treated animals, the spectrum of pathology that develops in the guinea pig now closely resembles the hepatic injury that has been described by Benjamin *et al.*³³ and Peters *et al.*³⁴ in human halothane hepatitis, i.e. hepatic injury ranging from panacinar and multifocal spotty necrosis, through submassive confluent zonal necrosis to massive necrosis. Severe cases of human halothane hepatitis are very rare, occurring in only 1:7,000–30,000 administrations³⁴ and are generally believed to be an idiosyncratic autoimmune disease brought about by trifluoroacetylation of hepatic proteins,⁵ while hepatotoxicity in the guinea pig appears to be due to the direct toxic consequences of binding by the trifluoroacetyl intermediate.^{10,14} However, there is a lack of definitive evidence for an immune-mediated mechanism being responsible for all cases of halothane hepatitis. Previous anesthesia with halothane and the presence of circulating antibodies to trifluoroacetylated hepatic proteins are often used to help diagnose the condition. But, 18–27% of cases have had no prior halothane anesthesia^{34,35} and up to 30–50% of patients suspected

to have halothane hepatitis lack the circulating antibodies.^{5,6} It must be remembered that induction of an antibody response alone is not a pathologic process³⁷ and that the mechanism by which the trifluoroacetyl antibodies cause halothane hepatitis also remains to be elucidated. The possibility thus exists for a mechanism of injury, other than one based on a hypersensitivity reaction, being responsible for some cases of severe halothane hepatitis.

A mild hepatic dysfunction, that has been speculated as being due to direct injury by reactive biotransformation intermediates, occurs in 20% or more of patients following halothane anesthesia.^{1,2} Alcohol consumption and pre-existing liver disease have not been shown to be predisposing factors for halothane hepatitis^{38,39} but, patients taking phenobarbital, which increases the degree of halothane biotransformation, have developed a greater incidence of hepatic injury following halothane anesthesia.⁴⁰ If the mechanism of the milder, acute halothane injury in humans is indeed the same as observed in the guinea pig, then individuals with compromised hepatic GSH levels, whether from a medication such as acetaminophen,⁴¹ or from exposure to chemicals in the workplace or the environment,⁴² could be vulnerable to a more severe injury, especially if the agent responsible for GSH depletion is also a potentially hepatotoxic substance. Only awareness of this possibility and careful observation for these conditions will demonstrate incidence in the patient population. Even if there is a lack of clinically discernable hepatic injury, any situation that enhances binding by the trifluoroacetyl moiety to liver proteins increases the amount of potentially antigenic material presented to the immune system, priming the mechanism believed to be responsible for classic halothane hepatitis.^{5,6}

The GSH-depleted guinea pig represents the first animal model to demonstrate fatal submassive to massive hepatic necrosis following halothane exposure. It may provide insights into mechanisms that could enhance halothane-induced liver injury following anesthesia as well as be of aid in the evaluation of hepatoprotective agents to help rescue the liver, in not only cases of halothane hepatitis, but also other types of acute fulminant hepatic injury.

The authors thank Rodney Glazener, B.S., for his technical assistance, and Patricia Kime and Sallie Cochren, for assistance with preparation of the manuscript.

References

1. Davis M, Eddleston ALWF, Neuberger JM, Vergani D, Mieli-Vergani G, Williams R: Halothane hepatitis (letter). *N Engl J Med* 303: 1123-1124, 1980
2. Hussey AJ, Aldridge LM, Paul D, Ray DC, Beckett GJ, Allan LG: Plasma glutathione S-transferase concentration as a measure of hepatocellular integrity following a single general anaesthetic with halothane, enflurane, or isoflurane. *Br J Anaesth* 60:130-135, 1988
3. Inman WHW, Mushin WW: Jaundice after repeated exposure to halothane: An analysis of reports to the Committee on Safety of Medicines. *Br Med J* 1:5-10, 1974
4. Bottinger LE, Dalen E, Hallen B: Halothane-induced liver damage: An analysis of material reported to the Swedish Adverse Drug Reaction Committee 1966-1973. *Acta Anaesthesiol Scand* 20:40-46, 1976
5. Kenna JG, Satoh H, Christ DD, Pohl LR: Metabolic basis for a drug hypersensitivity: Antibodies in sera from patients with halothane hepatitis recognize liver neoantigens that contain the trifluoroacetyl group derived from halothane. *J Pharmacol Exp Ther* 245:1103-1109, 1988
6. Clarke JB, Lind RC, Gandolfi AJ: Mechanisms of anesthetic hepatotoxicity, *Advances in Anesthesia*. Volume 10. Edited by Stoelting RK, Barash PG, Gallagher TJ. St. Louis, Mosby Year Book, 1993, pp 219-246
7. Lind RC, Gandolfi AJ, Brown BR, Hall PM: Halothane hepatotoxicity in guinea pigs. *Anesth Analg* 66:222-228, 1987
8. Lind RC, Gandolfi AJ, Hall PM: Age and gender influence halothane-associated hepatotoxicity in strain 13 guinea pigs. *ANESTHESIOLOGY* 71:878-884, 1989
9. Lind RC, Gandolfi AJ, Hall PM: The role of oxidative biotransformation of halothane in the guinea pig model of halothane-associated hepatotoxicity. *ANESTHESIOLOGY* 70:649-653, 1989
10. Lind RC, Gandolfi AJ, Hall PM: Covalent binding of oxidative biotransformation intermediates is associated with halothane hepatotoxicity in guinea pigs. *ANESTHESIOLOGY* 73:1208-1213, 1990
11. Lind RC, Gandolfi AJ, Hall PM: Subanesthetic halothane is hepatotoxic in the guinea pig. *Anesth Analg* 74:559-563, 1992
12. Lunam CA, Cousins MJ, Hall P de la M: Genetic predisposition to liver damage after halothane anesthesia in guinea pigs. *Anesth Analg* 65:1143-1148, 1986
13. Anders MW, Pohl LR: Halogenated alkanes, Bioactivation of Foreign Compounds. Edited by Anders MW. Orlando, Academic Press, 1985, pp 283-315
14. Lind RC, Gandolfi AJ, Hall P de la M: Glutathione depletion enhances subanesthetic halothane hepatotoxicity in guinea pigs. *ANESTHESIOLOGY* 77:721-727, 1992
15. Lind RC, Gandolfi AJ: Concentration dependent inhibition of halothane biotransformation. *Drug Metab Disp* 21:386-389, 1993
16. Lazenby CM, Lee SJ, Harpur ES, Gescher A: Glutathione depletion in the guinea pig and its effect on the acute cochlear toxicity of ethacrynic acid. *Biochem Pharmacol* 37:3743-3747, 1988
17. Anderson ME, Meister A: Glutathione monoesters. *Analyt Biochem* 183:16-20, 1989
18. Maiorino RM, Gandolfi AJ, Sipes IG: Gas chromatographic method for the halothane metabolites, trifluoroacetic acid and bromide in biological fluids. *J Anal Toxicol* 4:250-254, 1980
19. Drury RAB: *Carlton's Histological Technique*. 4th edition. New York, McGraw-Hill, 1967, pp 170-171

FATAL HALOTHANE HEPATITIS IN GUINEA PIGS

20. Hall P, Smith RD, Gormley BM: "Routine" stains on osmicated resin embedded hepatic tissue. *Pathology* 14:73-74, 1982
21. Tietze F: Enzymatic method for quantitative determination of nanogram amounts of total and oxidized glutathione: Applications to mammalian blood and other tissues. *Analyt Biochem* 27:502-522, 1969
22. Hursh D, Gelman S, Bradley EL: Hepatic oxygen supply during halothane or isoflurane anesthesia in guinea pigs. *ANESTHESIOLOGY* 67:701-706, 1987
23. Gelman S, Fowler KC, Smith LR: Liver circulation and function during isoflurane and halothane anesthesia. *ANESTHESIOLOGY* 61:726-730, 1984
24. Laskin DL, Pilaro AM: Potential role of activated macrophages in acetaminophen hepatotoxicity: Isolation and characterization of activated macrophages from rat liver. *Tox Appl Pharm* 86:204-215, 1986
25. Deleve LD, Kaplowitz N: Importance and regulation of hepatic glutathione. *Sem Liver Dis* 10:251-266, 1990
26. Huwyler J, Aeschlimann D, Christen U, Gut J: The kidney as a novel target tissue for protein adduct formation associated with metabolism of halothane and the candidate chlorofluorocarbon replacement 2,2-dichloro-1,1,1-trifluoroethane. *Eur J Biochem* 207:229-238, 1992
27. Mitchell JR, Jollow DJ, Potter WZ, Gillette JR, Brodie BB: Acetaminophen-induced hepatic necrosis: IV. Protective role of glutathione. *J Pharmacol Exp Ther* 187:211-217, 1973
28. Casini AF, Pompella A, Comporti M: Liver glutathione depletion induced by bromobenzene, iodobenzene, and diethylmaleate poisoning and its relation to lipid peroxidation and necrosis. *Am J Pathol* 118:225-237, 1985
29. Gregus Z, Madhu C, Klaassen CD: Species variation in toxication and detoxication of acetaminophen in vivo: A comparative study of biliary and urinary excretion of acetaminophen metabolites. *J Pharmacol Exp Ther* 244:91-99, 1987
30. Jollow DJ, Mitchell JR, Zampaglione W, Gillette JR: Bromobenzene-induced hepatic necrosis: Protective role of glutathione and evidence for 3,4-bromobenzene oxide as the hepatic metabolite. *Pharmacology* 11:151-169, 1974
31. Callis AH, Brooks SD, Roth TP, Gandolfi AJ, Brown BR: Characterization of a halothane-induced humoral immune response in rabbits. *Clin Exp Immunol* 67:343-351, 1987
32. Meister A: Glutathione deficiency produced by inhibition of its synthesis, and its reversal: Applications in research and therapy. *Pharmacol Ther* 51:155-194, 1991
33. Benjamin SB, Goodman ZD, Ishak KG, Zimmerman HJ, Irey NS: The morphological spectrum of halothane-induced hepatic injury: Analysis of 77 cases. *Hepatology* 5:1163-1171, 1985
34. Peters RL, Edmondson HA, Reynolds TB, Meister JC, Curphey TJ: Hepatic necrosis associated with halothane anesthesia. *Am J Med* 47:748-764, 1969
35. Ray DC, Drummond GB: Halothane hepatitis. *Br J Anaesth* 67:84-99, 1991
36. Kenna JG, Neuberger J, Williams R: Specific antibodies to halothane-induced liver antigens in halothane-associated hepatitis. *Br J Anaesth* 59:1286-1290, 1987
37. Park BK, Pirmohamed M, Kitteringham NR: Idiosyncratic drug reactions: A mechanistic evaluation of risk factors. *Br J Clin Pharmacol* 34:377-395, 1992
38. Fee JPH, Black GW, Dundee JW, McIlroy PDA, Johnston HML, Johnston SB, Black IHC, McNeill HG, Neill DW, Daggart JR, Merrett JD, McDonald JR, Bradley DSG, Haire M, McMillan SA: A prospective study of liver enzyme and other changes following repeat administration of halothane and enflurane. *Br J Anaesth* 51:1133-1141, 1979
39. Wark H, Earl J, Cooper M, Overton J: Halothane in children with chronic liver disease. *Anaesth Intensive Care* 19:9-16, 1991
40. Nomura F, Hatano H, Ohnishi K, Akikusa B, Okuda K: Effects of anticonvulsant agents on halothane-induced liver injury in human subjects and experimental animals. *Hepatology* 6:952-956, 1986
41. Insel PA: Analgesic-antipyretics and antiinflammatory agents: Drugs employed in the treatment of rheumatoid arthritis and gout, Goodman and Gilman's *The Pharmacological Basis of Therapeutics*. 8th edition. Edited by Gilman AG, Rall TW, Niew AS, Taylor P. New York, Pergamon Press, 1990, pp 638-681
42. Andrews LS, Snyder R: The toxic effects of solvents and vapors, Casarett and Doull's *Toxicology, The Basic Science of Poisons*. 4th edition. Edited by Amdur MO, Doull J, Klaassen CD. New York, Pergamon Press, 1991, pp 681-722