

## CORRESPONDENCE

Anesthesiology  
81:781, 1994  
© 1994 American Society of Anesthesiologists, Inc.  
J. B. Lippincott Company, Philadelphia

## Incorrectly Adjusted Vaporizer Exclusion System

*To the Editor:*—We recently had an equipment problem that fortunately resulted in no patient injury.

The patient was a healthy 5-month-old infant undergoing bilateral club foot repair. After a 3.5-h combined halothane/caudal anesthetic without incident, the patient was switched to desflurane to facilitate awakening. The desflurane vaporizer had been retrofitted onto a Dräger machine. The desflurane vaporizer was turned on without the halothane first being turned off because of an incorrectly adjusted exclusion system. This was quickly discovered because of the alarms on a Rascal gas monitor showing two gases present. When the other machines in the department were checked, one other Dräger was found to have this capability.

We never had this problem until retrofitting our machines with desflurane vaporizers and bring it to the attention of others as they may prevent the same problem.

**James P. Viney, M.D.**  
**Alan D. Gartrell, M.D.**  
Department of Anesthesiology  
Primary Children's Medical Center  
100 North Medical Drive  
Salt Lake City, Utah 84113

(Accepted for publication May 24, 1994.)

Anesthesiology  
81:781–782, 1994  
© 1994 American Society of Anesthesiologists, Inc.  
J. B. Lippincott Company, Philadelphia

## Improvement of the Left Broncho-Cath Double-lumen Tube

*To the Editor:*—It is sometimes difficult to properly position a conventional left-sided double-lumen tube (cDLT, Mallinckrodt Broncho-Cath).<sup>1</sup>

We think the reasons for this difficulty are the following: First, the angles of the tracheal axis with the proximal left main bronchus (angle a in fig. 1) and with the peripheral left main bronchus (angle b in fig. 1)

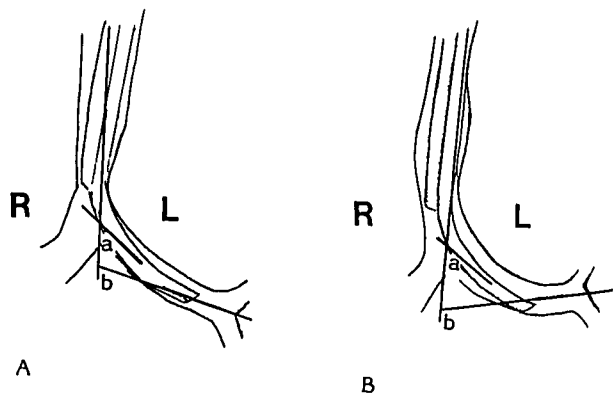
in fig. 1) increase greatly when the patient is moved from supine to left lateral position. When the angle changes, the bevel of the bronchial tip of the cDLT occasionally becomes obstructed by the medial wall of the left mainstem bronchus. In one study, angle a in our patients (9 men and 2 women, aged 22 to 73 yr, between 158 and 182 cm in height) changed from  $43.9^\circ \pm 5.5^\circ$  in supine position to  $50.6^\circ \pm 7.1^\circ$  in left lateral position. Angle b changed from  $69.1^\circ \pm 9.5^\circ$  in supine position to  $87.9^\circ \pm 14.6^\circ$  in left lateral position.

Second, the elongated or enlarged aortic arch, seen in patients undergoing thoracotomy, can compress the trachea from the left side. In such cases, the tracheal outlet of the cDLT should be positioned properly at the orifice of the right main bronchus.

Finally, the distance from the left endobronchial tip to the distal margin of the tracheal lumen tip of the cDLT (55 mm) is greater than the average left mainstem bronchial length (men,  $49 \pm 8$  mm; women,  $44 \pm 7$  mm).<sup>2</sup>

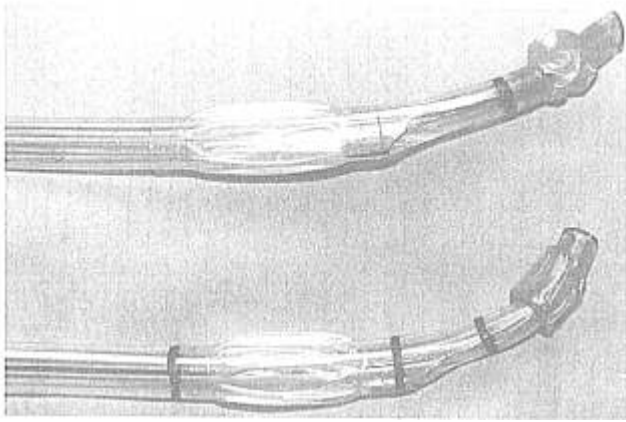
Therefore, we recommend four modifications to the cDLT (mDLT):

1. the bevel of the bronchial tip is modified (fig. 2),
2. the angle between the tracheal axis and the bronchial tube axis is increased from  $30^\circ$  to  $45^\circ$  (fig. 2),
3. the length of the bronchial tube is shortened to 40 mm to reduce risk of obstruction of the left upper lobe by the tip of the bronchial tube when an mDLT is positioned with its tracheal outlet fitting properly to the orifice of the right main bronchus, and
4. the endobronchial cuff is shortened 3 mm and moved 3 mm dis-



**Fig. 1.** The changes of the angles between the trachea and the proximal (a) and distal (b) of left mainstem bronchus in the supine (A) and in the left lateral (B) position.

## CORRESPONDENCE



**Fig. 2. Tips of a conventional (top) and an improved (bottom) left-sided Broncho-Cath.**

tally to prevent obstructing the carina and right mainstem bronchus (fig. 2).

In a study of 16 patients, we found that these modifications allowed easier fiberoptic visualization of the left upper lobe bronchus and increased the margin of safety for obstruction of the same bronchus.

Theoretically, insertion of an mDLT could be slightly more difficult or cause bronchial wall trauma from the leading edge of the endobronchial tube. We had no difficulty in positioning the mDLT in this study.

We think a carinal hook<sup>3</sup> is unnecessary because the tracheal lumen tip can function as a carinal hook. Dislodgement intraoperatively should, theoretically, be easier to treat. Because the tracheal lumen tip prevents excess caudal movement, if the tube becomes dislodged, it should merely be advanced until gentle resistance to movement is felt. It then should be pulled back about 1 cm. When right lung ventilation is restored, the tracheal lumen tip has been resealed.

Anesthesiology  
81:782, 1994  
© 1994 American Society of Anesthesiologists, Inc.  
J. B. Lippincott Company, Philadelphia

*In Reply:*—We are pleased to hear of Yahagi *et al.*'s successful study using Broncho-Cath left endobronchial tubes with modified tip. His findings agree with other preference studies of this design conducted by investigators around the world. Similar preferences were expressed in earlier work by Benumof<sup>1</sup> and again by Klippe<sup>2</sup> *et al.* and also by Desai and Rocke<sup>3</sup> and Alfery.<sup>4</sup> These minor modifications reduce the variability typical in past forms of the time-tested Robertshaw design and are intended to facilitate the practice of fiberoptic bronchoscopy to guide the placement of double-lumen tubes. We are grateful for the contributions of Yahagi *et al.* and other investigators in this work.

**Robert A. Virag**  
Director, Research and Development  
Mallinckrodt Medical, Inc.  
675 McDonnell Boulevard

**Naoki Yahagi, M.D.**  
Staff  
Surgical Intensive Care Unit  
National Cardiovascular Center

**Hitoshi Furuya, M.D.**  
Associate Professor  
Department of Anesthesiology  
Nara Medical University

**Junki Matsui, M.D.**  
Staff Anesthesiologist  
Department of Anesthesiology  
Shiga University of Medical Science

**Yoshikazu Sai, M.D.**  
Assistant Professor  
Department of Anesthesiology and Intensive Care Unit  
Shiga University of Medical Science

**Yoshikuni Amakata, M.D.**  
Professor and Chairman  
Department of Anesthesiology and Intensive Care Unit  
Shiga University of Medical Science

**Keiji Kumon, M.D.**  
Chief  
Surgical Intensive Care Unit  
National Cardiovascular Center  
Suita, Osaka 565, Japan

## References

1. Desai FM, Rocke DA: Double-lumen tube design fault. *ANESTHESIOLOGY* 73:575-576, 1990
2. Benumof JL, Partridge BL, Salvatierra C, Keating J: Margin of safety in positioning modern double-lumen endotracheal tubes. *ANESTHESIOLOGY* 67:729-738, 1987
3. Alfery DD: Increasing the margin of safety in positioning left-sided double-lumen endotracheal tubes. *ANESTHESIOLOGY* 69:149-150, 1988

(Accepted for publication May 25, 1994.)

P.O. Box 5840  
St. Louis, Missouri 63134

## References

1. Benumof JL: Improving the design and function of double-lumen tubes. *J Cardiothorac Anesth* 6:563-564, 1987
2. Klippe HJ, Schottke-Hennings H, Schmieding B: Fibre bronchoscopy as a supporting method for the positioning and monitoring of double lumen tubes in thoracic anaesthesia. *Anasth Intensivther Notfallmed* 24:327-333, 1989
3. Desai FM, Rocke DA: Double-lumen tube design fault. *ANESTHESIOLOGY* 73:575-576, 1990
4. Alfery DD: Increasing the margin of safety in positioning left-sided double-lumen endotracheal tubes. *ANESTHESIOLOGY* 69:149-150, 1988

(Accepted for publication May 25, 1994.)