

Anesthesiology
81:1371-1375, 1994
© 1994 American Society of Anesthesiologists, Inc.
J. B. Lippincott Company, Philadelphia

An Intrathecal Fentanyl Dose-Response Study in Lower Extremity Revascularization Procedures

Scott S. Reuben, M.D.,* Steven M. Dunn, M.D.,† Karen Marie Duprat, R.N.,‡ Patricia O'Sullivan, Ed.D.§

Background: Intrathecal opioids routinely are administered to surgical patients to provide prolonged postoperative analgesia. This study evaluated the dose-response effects of intrathecal fentanyl in an elderly patient population undergoing lower extremity revascularization procedures.

Methods: Surgical anesthesia was induced using a continuous spinal technique. No patient received perioperative antiemetics or opioids. Postoperatively, after complete regression of spinal anesthesia, patients received *via* the spinal catheter either 0, 5, 10, 20, 40, or 50 μg fentanyl. Blood pressure, heart rate, respiratory rate, oxyhemoglobin saturation, and visual analog pain scores were recorded approximately every minute for 15 min after study drug administration. After this initial observation period, blood pressure, heart rate, respiratory rate, oxyhemoglobin saturation were recorded every 15 min for the next 2 h, then every 30 min thereafter. A verbal analog pain score, with 0 equivalent to no pain and 10 the worst pain imaginable, was obtained with each set of vital signs. The study was concluded when the verbal analog pain score was ≥ 3 , the patient was medicated, and the time was recorded. Any side effects, such as respiratory depression, nausea, vomiting, and pruritus, were recorded.

Results: Minimal analgesia was derived from the 0-, 5-, and 10- μg doses. Beginning at 20 μg , patients experienced the onset of satisfactory analgesia (visual analog pain scores < 3) within 4 min. All patients in the 40- and 50- μg groups had excellent analgesia (visual analog pain scores < 1) within 10 min. No patient experienced respiratory depression (respiratory rate < 9 breaths/min), hypoxemia (oxyhemoglobin saturation $< 90\%$), or any hemodynamic alterations (20% change greater

or less than baseline heart rate or blood pressure). In the 50- μg group, five of ten patients complained of pruritus.

Conclusions: Results indicate that 40 μg intrathecal fentanyl provides satisfactory analgesia for approximately 5 h in an elderly patient population, with a low incidence of side effects. (Key words: Analgesics, intrathecal: fentanyl. Anesthetic technique, continuous spinal: lidocaine. Anesthetics, local. Surgery: vascular.)

INTRATHECAL opioids frequently are used in the management of postoperative pain. Although intrathecal morphine provides prolonged pain relief of up to 24 h,¹⁻³ its routine use has been limited because of the risk of delayed respiratory depression.

Fentanyl is much more lipid-soluble than morphine and hence does not tend to migrate intrathecally to the fourth ventricle in sufficient concentrations to cause delayed respiratory depression.⁴ For this reason, it may be a safer alternative than morphine for the management of postoperative pain in geriatric patients who are at a higher risk for this complication⁴ or in patients in whom sufficient monitoring is not possible. Little work has been done to establish the pharmacodynamics of intrathecal fentanyl. Major publications recommend dose ranges for intrathecal fentanyl that have been determined by clinical consensus rather than by objective data.^{5-7,||}

Previous studies attempted to evaluate intrathecal fentanyl administered in combination with local anesthetic.^{8,9} This precludes accurate assessment of the onset or duration of action of the drug when given alone. In addition, many of these previous studies were conducted in the obstetric population,^{8,9} making it difficult to extrapolate the results to the population at large or to the geriatric population. This current study evaluates the clinical effects of intrathecal fentanyl, independent of local anesthetic action, in an elderly patient population.

Methods and Materials

After approval from the Institutional Review Board, informed written consent was obtained from 60 pa-

*Assistant Professor of Anesthesiology; Director, Acute Pain Service, Baystate Medical Center and the Tufts University School of Medicine.

†Assistant Professor of Anesthesiology, Director of Education, Baystate Medical Center and the Tufts University School of Medicine.

‡Clinical Coordinator, Acute Pain Service, Baystate Medical Center.

§Clinical Associate Professor, University of Arkansas for Medical Sciences.

Received from the Baystate Medical Center and the Tufts University School of Medicine, Springfield, Massachusetts. Accepted for publication August 6, 1994. Presented in part at the annual meeting of the American Society of Anesthesiologists, Washington, D.C., October 11, 1993.

Address reprint requests to Dr. Reuben: Department of Anesthesia, Baystate Medical Center, Springfield, Massachusetts 01199.

|| Ready LB: Personal communication. 1994.

tients scheduled for elective lower extremity revascularization. A subarachnoid puncture was performed with an 18-G needle at the L2–L3 or L3–L4 interspace. A 20-G Teflon catheter was inserted 3 cm into the subarachnoid space after free-flowing cerebrospinal fluid was obtained.

Lidocaine, either 2% isobaric or 5% hyperbaric, was administered at the discretion of the attending anesthesiologist throughout the case to maintain adequate surgical anesthesia. No patients received perioperative opioids or antiemetics. Patients were given intravenous midazolam and propofol for sedation as deemed necessary by the attending anesthesiologist.

At the conclusion of surgery, the patients were transported to the postanesthesia care unit, where baseline heart rate (HR), blood pressure (BP), respiratory rate (RR), and oxyhemoglobin saturation (Sp_{O_2}) were recorded. All patients were awake and alert on admission to postanesthesia care unit. All patients received supplemental oxygen *via* nasal cannula (2 l/min). Patients were discharged from the postanesthesia care unit breathing room air ($Sp_{O_2} \geq 90\%$). The regression of surgical anesthesia was determined using the Bromage scale¹⁰ and a sensory examination. Once normal motor (Bromage IV) and cutaneous sensation to pinprick were established, patients were administered the intrathecal study drug on request for analgesia. Patients were randomly assigned to one of the six study groups. Either 0, 5, 10, 20, 40, or 50 μ g fentanyl diluted to a final volume of 1 ml with normal saline was administered in a double-blind fashion. This was followed by a 0.5-ml normal saline flush.

A blinded observer then measured and recorded BP, HR, RR, Sp_{O_2} , and visual analog pain scores (VAPS) at approximately 1-min intervals for the first 15 min. Pain was evaluated using a standard 10-cm linear visual analog scale with 0 corresponding to no pain and 10 the worst pain imaginable. Patients were instructed to verbalize any change in their physical condition. Any side effects observed, including pruritus, nausea, vomiting, respiratory depression ($RR < 9$), and hypoxemia ($Sp_{O_2} < 90\%$), were recorded. Any changes in hemodynamic parameters by more than 20% from baseline values were noted. After this initial observation period, measurements of BP, HR, RR, and Sp_{O_2} were made every 15 min for the next 2 h and every 30 min thereafter. A verbal analog pain score with 0 equal to no pain and 10 the worst pain imaginable was obtained with each set of vital signs. When the verbal analog pain score was 3 or more, the patient was medicated for pain and

the time was recorded. The duration of analgesia equaled the time from administration of the intrathecal study drug until this first administration of additional opioid. Once supplemental opioids were given, the RR, BP, and pulse were recorded every 2 h until 24 h had elapsed since the study drug administration.

Duration-of-analgesia data were evaluated for statistical significance using a one-way analysis of variance with Scheffé's *post hoc* procedures. Side-effects data were assessed using Fisher's exact test. A *P* value of less than 0.05 was considered significant.

Results

There were no demographic differences noted among the six groups in age, weight, or height (table 1).

Duration of Analgesia

Analgesic duration increased in a dose-dependent manner from 0 to 40 μ g ($P < 0.0001$; fig. 1). The duration for the 0-, 5-, 10-, 20-, 40-, and 50- μ g doses were (mean \pm SEM): 16 \pm 1, 32 \pm 1, 66 \pm 15, 119 \pm 23, 321 \pm 45, and 300 \pm 39 min. *Post hoc* analysis indicated there were two homogeneous sets. Groups receiving 0, 5, 10, and 20 μ g formed one homogeneous set, and groups receiving 40 and 50 μ g formed the other set. Two of the patients in the 50- μ g group received 2 mg nalbuphine intravenously for the treatment of refractory pruritus. This resulted in a significantly shorter duration of analgesia of 114 and 133 min, respectively, for these patients. When these patients were eliminated from the data analysis, the average duration of analgesia in the 50- μ g group was 344 min.

Onset of Analgesia

All patients in 40- and 50- μ g groups experienced excellent analgesia (VAPS < 1) within 10 min (fig. 3). A

Table 1. Demographics (n = 10)

Fentanyl Dose (μ g)	Age (yr)	Weight (kg)	Height (in)
0	71 \pm 9	64 \pm 8	65 \pm 3.2
5	69 \pm 13	72 \pm 11	66 \pm 3.9
10	70 \pm 8	71 \pm 11	67 \pm 3.4
20	69 \pm 9	72 \pm 16	65 \pm 4
40	63 \pm 12	74 \pm 16	69 \pm 3.7
50	68 \pm 7	76 \pm 10	65 \pm 4

Values are mean \pm SD.

DOSE RESPONSE OF INTRATHECAL FENTANYL

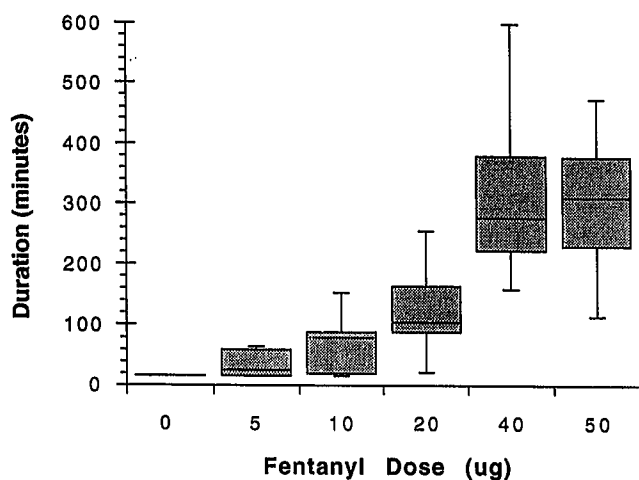


Fig. 1. Duration of action of intrathecal fentanyl estimated by the time from dosage until further medication was administered. The shaded boxes represent the 25th to the 75th percentiles. The solid line is the median, and the bars show the range.

significantly greater number of these patients reported satisfactory analgesia within 3 min compared to those patients in the 20- μ g group (Fisher's exact test, $P < 0.023$). The majority of patients receiving 20 μ g experienced the onset of satisfactory analgesia (VAPS < 3) within 4 min (fig. 2). Minimal and inconsistent analgesia was derived from the 0-, 5-, and 10- μ g doses (fig. 2).

Side Effects

The incidence of pruritus was statistically significant when comparing those receiving 50 μ g to the other groups (Fisher's exact test, $P = 0.006$). Only one patient in each of the 10- and 40- μ g groups complained of pruritus. Five of ten patients in the 50- μ g group complained of pruritus. The symptoms were self-limiting in two of these cases, but three required treatment with 25 mg intravenous diphenhydramine. Two of these three required additional treatment with 2 mg intravenous nalbuphine for refractory pruritus. One patient in the 50- μ g group experienced nausea and vomiting, which resolved after one dose of 0.625 mg intravenous droperidol. Nausea or vomiting was not noted among any of the other groups. No patients experienced respiratory depression (RR < 9 breaths/min), hypoxemia ($Sp_{O_2} < 90\%$), or hemodynamic alterations (20% change greater or less than baseline HR or BP).

Discussion

The clinical effects of administering morphine *via* the subarachnoid route have been studied extensively.¹⁻³ Its use in routine postoperative pain management has been limited because of the greater incidence of side effects, particularly respiratory depression, when compared to the more lipophilic opioids. Fentanyl is more lipid-soluble than morphine, making late respiratory depression less likely. However, few studies are available on the pharmacokinetic and pharmacodynamic properties of intrathecal fentanyl. Of the few that have been published, most evaluate fentanyl when administered concomitantly with either lidocaine or bupivacaine in the obstetric population.^{8,9}

The onset and duration of action of intrathecal opioids as well as hemodynamic effects are difficult to determine when administered simultaneously with local an-

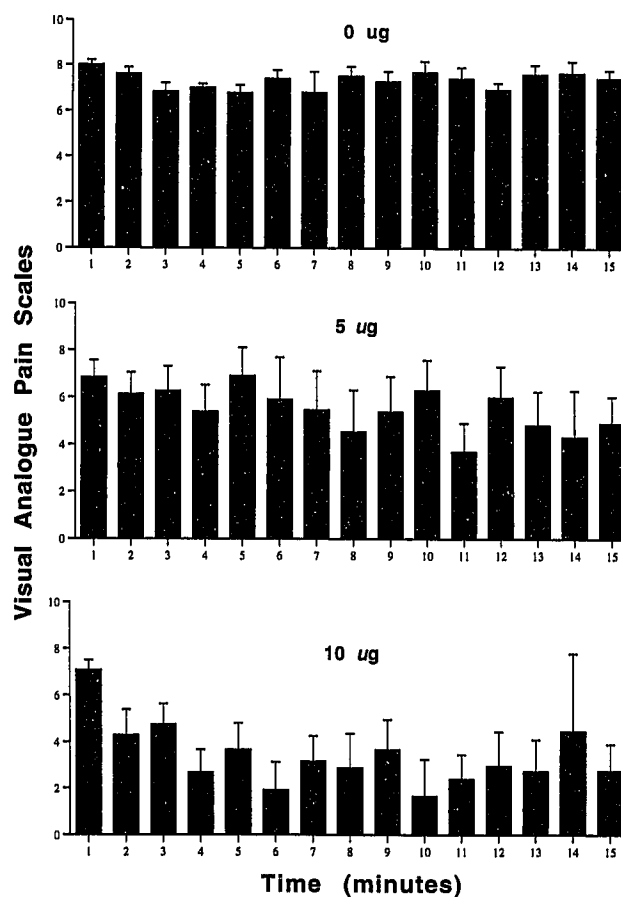


Fig. 2. Visual analogue pain score versus time after intrathecal injection of fentanyl. The total dose of intrathecal fentanyl is indicated for each graph. The error bars indicate SEM.

esthetics in the subarachnoid space. Previous studies showed a synergistic effect when opioids are combined with local anesthetics.^{11,12} In addition, intrathecal fentanyl has been shown to prolong the duration of local anesthetic spinal blockade in a dose-dependent manner.⁹ The current study specifically examines the clinical effects of fentanyl alone after the patients demonstrated complete regression of their spinal anesthetic.

One advantage of using intrathecal fentanyl is its extremely rapid onset of action. Analgesia has been reported to occur within 5–10 min.^{5–7} Our data reveal that the onset of action is very rapid and dose-dependent. Patients receiving 20 μg experienced satisfactory analgesia (VAPS < 3) within 4 min. In the 40- and 50- μg groups, satisfactory analgesia occurred within 3 min. All patients in these two groups had excellent analgesia (VAPS < 1) within 10 min (fig. 3).

The severity of postoperative pain depends on many factors, including the nature and site of the surgical procedure. Upper abdominal and thoracic incisions are associated with more severe pain than those following lower extremity surgery.¹³ Previous studies evaluating dose-response curves for epidural morphine reflect these increases in opioid requirements for satisfactory analgesia.¹⁴ Dose-response curves evaluating epidural morphine after lower extremity surgery revealed effective postoperative pain relief can be achieved with doses as low as 2 mg morphine.¹⁵ Larger doses of morphine did not increase the duration or improve the quality of analgesia. This is consistent with the lower nociceptive input when compared to thoracic procedures. Similarly, our results also demonstrated that 40 μg intrathecal fentanyl provided optimal analgesia, and therefore, increasing the dose to 50 μg provided no further benefit. The duration of analgesia demonstrated a dose-dependent increase up to 40 μg fentanyl. Increasing the dose from 40 to 50 μg resulted in no significant increase in the duration of analgesia but did increase the incidence of pruritus. It is surprising that our patients required such large doses of fentanyl until optimal analgesia was achieved. In comparison, Hunt *et al.* showed that the optimal dose of fentanyl was 6.25 μg for abdominal procedures.⁸ In their study, however, the intrathecal fentanyl was used in combination with bupivacaine for cesarean section procedures. This smaller requirement of fentanyl most likely reflects the synergistic action of bupivacaine and fentanyl as reported by Wang.¹² Our data reveal that 10 μg intrathecal fentanyl alone provided inadequate

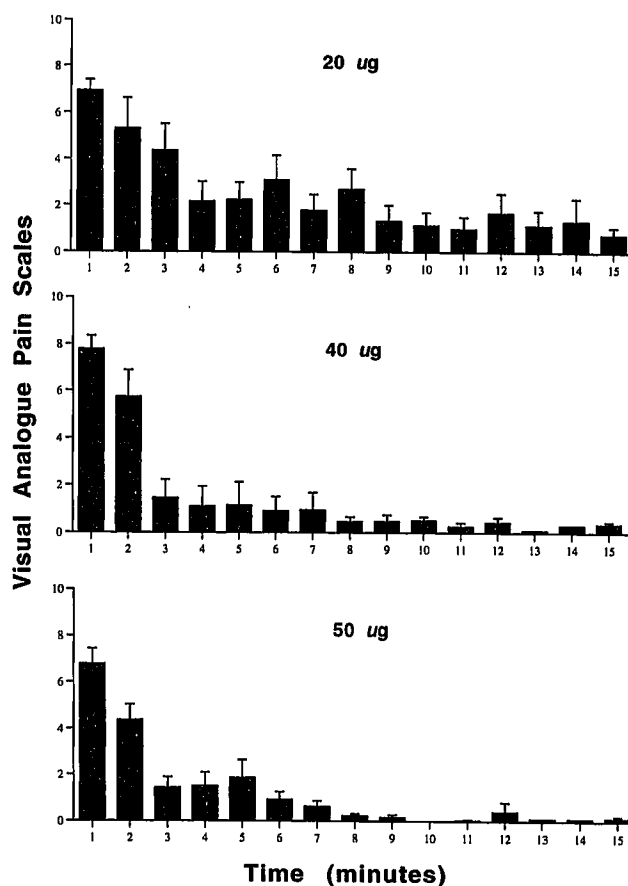


Fig. 3. Visual analogue pain score *versus* time after intrathecal injection of fentanyl. The total dose of intrathecal fentanyl is indicated for each graph. The error bars indicate SEM.

postoperative analgesia. The patients in this group reported inconsistent reductions in their pain score (fig. 2) and requested additional pain medication within 60 min.

The incidence of pruritus was significant at the 50- μg dose compared to all other participants in the study. Five of ten patients in this group reported pruritus. In comparison, the reported incidence of pruritus using an equivalent dose in the obstetric population is 63–90%.^{8,9} HR and BP remained unaltered by any dose of intrathecal fentanyl studied.

None of our patients experienced respiratory depression or hypoxemia after any of the fentanyl doses we evaluated. The lowest RR was 12 breaths/min in two patients in the 50- μg group. This finding is clinically important considering our patient population had an average age of 68 yr and many had coexisting cardiac

DOSE RESPONSE OF INTRATHECAL FENTANYL

and pulmonary disease predisposing them to an increased risk of respiratory depression from neuraxial opioids.⁴

In conclusion, our results demonstrate that 40 µg intrathecal fentanyl provides a rapid onset of analgesia with a duration of greater than 5 h and minimal undesirable side effects in an elderly patient population undergoing lower extremity revascularization.

References

1. Wang JK, Nauss LE, Thomas JE: Pain relief by intrathecally applied morphine in man. *ANESTHESIOLOGY* 50:149-151, 1979
2. Gjessing J, Tomlin PJ: Postoperative pain control with intrathecal morphine. *Anaesthesia* 36:268-276, 1981
3. Samii K, Viars P: Postoperative spinal analgesia with morphine. *Br J Anaesth* 53:817-820, 1981
4. Etches RC, Sandler AN, Daley MD: Respiratory depression and spinal opioids. *Can J Anaesth* 36:165-185, 1989
5. Bonica J: *The Management of Pain*. 2nd edition. Malvern, Lea & Febiger, 1990, p 1974
6. Ready LB, Edwards WT: *Management of Acute Pain: A Practical Guide*. Seattle, IASP Publications, 1992, p 17
7. Sevarino FB, Preble LM: *A Manual for Acute Postoperative Pain Management*. New York, Raven Press, 1992, pp 142-144
8. Hunt CO, Naulty JS, Bader AM, Hauch MA, Vartikar JV, Datta S, Hertwig LM, Ostheimer GW: Perioperative analgesia with subarachnoid fentanyl-bupivacaine for cesarean delivery. *ANESTHESIOLOGY* 71:535-540, 1989
9. Belzarena SD: Clinical effects of intrathecally administered fentanyl in patients undergoing cesarean section. *Anesth Analg* 74:653-657, 1992
10. Bromage PR: A comparison of the hydrochloride and carbon dioxide salts of lidocaine and prilocaine in epidural analgesia. *Acta Anaesthesiol Scand* 16(suppl):55-69, 1965
11. Bengt A, Arwestrom E, Post C: Local anesthetics potentiate spinal morphine antinociception. *Anesth Analg* 67:943-948, 1988
12. Wang C, Chakrabarti MK, Whitman JG: Specific enhancement by fentanyl of the effects of intrathecal bupivacaine on nociceptive afferent but not on sympathetic efferent pathways in dogs. *ANESTHESIOLOGY* 79:766-773, 1993
13. Loan WB, Morrison JD: The incidence and severity of postoperative pain. *Br J Anaesth* 39:695-698, 1967
14. Chambers WA, Sinclair CJ, Scott DB: Extradural morphine for pain after surgery. *Br J Anaesth* 53:921-924, 1981
15. Martin R, Salbaing J, Blaise G, Tetrault JP, Tetrault L: Epidural morphine for postoperative pain relief: A dose response curve. *ANESTHESIOLOGY* 56:423-426, 1982