

■ CASE REPORTS

Anesthesiology
81:1535-1537, 1994
© 1994 American Society of Anesthesiologists, Inc.
J. B. Lippincott Company, Philadelphia

Electrical Seizures during Sevoflurane Anesthesia in Two Pediatric Patients with Epilepsy

Hisao Komatsu, M.D.,* Satoshi Taie, M.D.,† Syoiti Endo, M.D.,‡ Kuniaki Fukuda, M.D.,‡ Masaaki Ueki, M.D.,§
Junko Nogaya, M.D.,§ Kenji Ogli, M.D.‡

SEVOFLURANE is a potent inhalation anesthetic used in Japan in pediatric anesthesia. Although no electroencephalographic (EEG) evidence of seizure activity has been seen, sevoflurane has been associated with clonic and tonic seizurelike movements of the extremities.¹ In addition, a greater incidence of opisthotonus in mice has been seen with sevoflurane than with isoflurane, enflurane, methoxyflurane, or halothane. Thus, sevoflurane may possess a property causing central nervous system stimulation. In the current report, we describe two cases wherein electrically generalized but clinically silent seizure activity occurred during induction of anesthesia with sevoflurane in epileptic children. We obtained institutional and parental consent for 12-channel EEG monitoring.

Case Reports

Case 1

An 8-yr-old boy was scheduled for an operation for left strabismus repair. Medical history included epilepsy (complex partial seizure)

* Head, Department of Anesthesiology, National Kagawa Children's Hospital.

† Department of Anesthesiology, National Kagawa Children's Hospital.

‡ Department of Pediatric Neurology, National Kagawa Children's Hospital.

§ Department of Anesthesiology and Emergency Medicine, Kagawa Medical School.

Received from the Departments of Anesthesiology and Pediatric Neurology, National Kagawa Children's Hospital, and the Department of Anesthesiology and Emergency Medicine, Kagawa Medical School, Kagawa, Japan. Accepted for publication August 2, 1994.

Address reprint requests to Dr. Komatsu: Department of Anesthesiology, National Kagawa Children's Hospital, 2603, Zentuji-cho, Zentuji, Kagawa, 765, Japan.

Key words: Anesthetics, volatile: sevoflurane. Brain, electroencephalography: electrical seizure. Complications: epilepsy.

|| Komatsu H, Ohara T, Nogaya J, Tsukamoto I, Yokono S, Ogli K: The effects of age and anesthetic solubility on anesthetic-induced opisthotonus in mice. *J Anesth* 5:228-232, 1991.

from the age of 1 yr, and sodium valproate (400 mg/day) had been administered for the previous 4 yr. There had been no seizures for 2 yr. Results of a complete neurologic examination of the patient were within normal limits. Immediately before induction of anesthesia, the EEG showed moderately high-voltage alpha activity, at 8 per second, and some random diffuse theta activity (fig. 1A). EEGs were recorded using a 14-channel EEG instrument (Nihonkoden EEG 5214, Tokyo, Japan).

The EEG remained unchanged while the child breathed 100% O₂, after which 1.0% sevoflurane was added to the inspired gas and increased 1.0% every 1-2 min. During the first 90 s of 2% sevoflurane administration, there was a light increase in alpha frequency. At 120 s after the beginning of administration of 2.0% sevoflurane, polyspike-and-wave complexes were observed predominantly in the central area. With increasing sevoflurane concentration, spike-and-wave complexes became slower. High-voltage (500-600 μ V) spike-and-wave bursts occurred diffusely at 7% sevoflurane and continued for 30 s (fig. 1B), followed by slowing and 1-Hz spike-and-wave complexes. After tracheal intubation, sevoflurane concentration was reduced to 3%, and high-voltage slow waves in the frontal, central, and parietal area followed (fig. 1C). Addition of 67% N₂O slightly increased the amplitude in each area. No spike activity was observed. Electrocardiogram were maintained within normal limits. Oxyhemoglobin saturation measured by pulse oximetry (SpO₂) was continuously monitored with a pulse oximeter and was never less than 99%, and no clinical seizure appeared. The patient awoke uneventfully after the 105-min anesthesia. The following day, the child's neurologic examination results were within normal limits.

Case 2

A 3-yr-old boy with mental retardation was scheduled for an exotropia operation. Medical history included epilepsy (West syndrome) from 7 months old, and sodium valproate (400 mg/day) had been given for 2 yr. There had been no epileptic episodes in the past 12 months. Anesthesia was induced with oxygen and sevoflurane 60 min after premedication including 1.0 g oral trichlorethyl phosphate monosodium. Immediately before induction of anesthesia, the sleep tracing EEG showed theta and alpha activities of high voltage (100-200 μ V; fig. 2A). In this case, end-tidal sevoflurane concentration was continuously measured using an infrared gas analyzer. Sevoflurane (0.5%) was added to oxygen, with increases in the concentration by 0.5% every 1 min. At an end-tidal sevoflurane concentration of 1.3%, there was an increase in alpha frequency and in voltage (200-300 μ V). Poly spikes and poly spike-and-wave complexes appeared bilaterally in the central, parietal, occipital, and frontal areas at 2.8%. At 4.0% of sevoflurane, diffuse poly spike-and-wave complexes and spike-and-wave complexes appeared. With an increase of sevoflurane concentration to 5.3%, (poly) spike-and-wave

CASE REPORTS

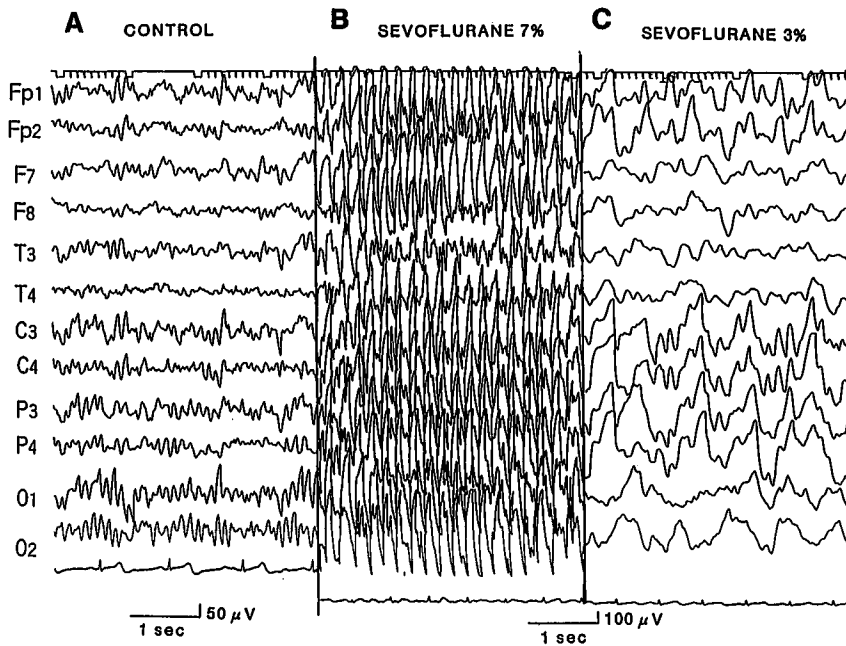


Fig. 1. (A) Immediately before anesthesia, the control electroencephalogram showed alpha activity of moderate voltage, at 8 per second, and some random diffuse theta activity. (B) High-voltage (500–600 μ V) spike-and-wave bursts occurred diffusely at 7% sevoflurane and continued for 30 s, followed by slowing and 1-Hz spike-and-wave complexes. (C) After the tracheal intubation, sevoflurane concentration was reduced to 3%, and high-voltage slow waves in the frontal, central, and parietal area followed.

complexes became more rhythmic, followed by an abrupt suppression. When the sevoflurane concentration was 5.0%, EEG showing a suppression and burst (diffuse spike-and-wave complexes), intubation of the trachea was attempted, but failed, and this was followed by progressively increasing EEG activity, resulting in diffuse fast spike-

and-wave bursts (fig. 2B). This continued for 60 s, followed by suppression. The second trial of intubation was successful at a concentration of 7.0% with maintained suppression. Then the concentration was decreased to 3.0% and again gradually increased. At 5.0%, 80 s of diffuse fast spike-and-wave bursts again appeared, followed

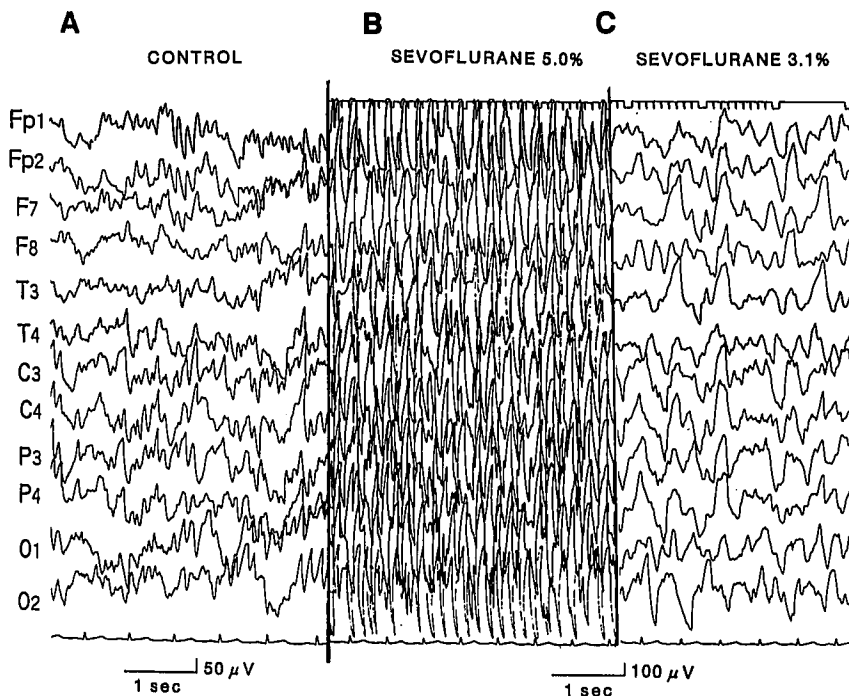


Fig. 2. (A) Immediately before induction of anesthesia, the sleep tracing electroencephalogram (EEG) showed theta and alpha activities. (B) When sevoflurane concentration was 5.0%, EEG showing a suppression and burst (diffuse spike-and-wave complexes), intubation of the trachea was attempted, but failed, and this was followed by progressively increasing EEG activity. This stimulus at last resulted in diffuse fast spike-and-wave bursts. (C) Subsequent concentration of 3.1% brought about stable high-voltage slow waves.

CASE REPORTS

by suppression at 5.9%. Subsequent concentration of 3.1% induced stable high-voltage slow waves (fig. 2C). Throughout the observation, arterial blood pressure and heart rate were kept within the normal ranges, and Sp_{O_2} and end-tidal carbon dioxide were maintained at more than 98% and between 39 and 46 mmHg, respectively. During anesthesia, no clinical seizure appeared. The patient awoke uneventfully after conclusion of the 2-h anesthesia. The following day the child's neurologic examination results were normal.

Discussion

Anesthetics used for pediatric patients with epilepsy should produce smooth and rapid induction without inducing seizure activity. Although Ogasawara *et al.* reported that sevoflurane (up to 5%) and 50% N_2O in oxygen did not induce clinical seizure activity in a 20-yr-old male patient with cerebral palsy and a history of seizures, the EEG was not monitored.² In our cases, EEG monitoring during induction of anesthesia with sevoflurane revealed severe but transient electrical seizure activities (diffuse synchronous high-voltage spike-and-wave complexes and spike-and-wave bursts) without clinical seizures. The EEG seizure activity possibly was related to sevoflurane anesthesia, because Sp_{O_2} , end-tidal carbon dioxide (Case 2), arterial blood pressure, and heart rate were maintained within normal limits. We did not measure blood sugar levels, but hypoglycemia was unlikely in these cases, because patients had taken 10 ml/kg of sugar-containing water 2–3 h before anesthesia, and 4.3% glucose-containing fluid (approximately $5 \text{ ml} \cdot \text{kg}^{-1} \cdot \text{h}^{-1}$) was infused during anesthesia. Trichlorethyl phosphate monosodium was administered to the second patient, but it is unlikely that this caused the electrical seizures, because the sleeping EEG was almost normal immediately before administration of sevoflurane. Thus, these cases, to our knowledge, represent the first clinical report of electrical seizures during sevoflurane anesthesia.

The effects of two methods of induction of sevoflurane anesthesia on the EEG pattern were compared in the same individual. When 4% sevoflurane was administered, a sudden appearance of rhythmic high-voltage slow waves of 2–3 Hz at 1–3 min occurred, which was

followed by a pattern of faster activities of 10–14 Hz mixed with 5–8-Hz slow waves. In contrast, the administration of incremental doses of sevoflurane induced an increase in frequency and amplitude of EEG activities in the light plane, followed by their decreases in deeper planes. Neither spike-and-wave complexes nor spike bursts were observed in this study. Our observation, therefore, may be unique to patients with epilepsy. Electrical seizures were of short duration (30–80 s) and transient. It is unclear whether this phenomenon is sevoflurane-specific or anesthesia-specific, because we have not performed a systematic comparative study using other inhaled anesthetics and because many anesthetics, including nitrous oxide,³ halothane,⁴ enflurane,^{5,6} and isoflurane,⁷ have been reported to cause seizure activity clinically. However, in epileptic patients, isoflurane and halothane have been used to treat patients with intractable status epilepticus.^{8,9}

In summary, we describe two pediatric patients with epilepsy who developed electroencephalographic evidence of seizure activity during uncomplicated sevoflurane anesthesia.

References

1. Adachi M, Ikemoto Y, Kubo K, Takuma C: Seizure-like movements during induction of anesthesia with sevoflurane. *Br J Anaesth* 68:214–215, 1992
2. Ogasawara E, Shimodate Y, Isozaki K, Matsuki A: Sevoflurane anesthesia for a patient with cerebral palsy [in Japanese; abstract in English]. *Masui [Jpn J Anesthesiol]* 39:500–502, 1990
3. Krenn J, Porges P, Steinbereithner K: Case of anaesthesia convulsions under nitrous oxide-halothane anaesthesia. *Anaesthetist* 16: 83–85, 1967
4. Burchiel KJ, Stockard JJ, Calverley RK, Smith NT, Scholl ML, Mazze RI: Electroencephalographic abnormalities following halothane anesthesia. *Anesth Analg* 57:244–251, 1978
5. Niejadlik K, Galindo A: Electroencephalographic seizure activity during enflurane anesthesia. *Anesth Analg* 54:722–724, 1975
6. Flemming DC, Fitzpatrick J, Fariello RG, Duff T, Hellman D, Hoff BH: Diagnostic activation of epileptogenic foci by enflurane. *ANESTHESIOLOGY* 52:431–433, 1980
7. Poulton TJ, Ellingson MD: Seizure associated with induction of anesthesia with isoflurane. *ANESTHESIOLOGY* 61:471–476, 1984
8. Delgado-Escueta AV, Wasterlain C, Treiman DM, Porter RJ: Management of status epilepticus. *N Engl J Med* 306:1337–1340, 1982
9. Kofke WA, Snider MT, Young RSK, Ramer JC: Prolonged low flow isoflurane anesthesia for status epilepticus. *ANESTHESIOLOGY* 62: 653–656, 1985

Avramov MN, Shingu K, Omatsu Y, Osawa M, Mori K: Effects of different speed of induction with sevoflurane on the EEG in man. *J Anesth* 1:1–7, 1987.