

CORRESPONDENCE

Table 1. Labeled ("Approved") Indications of Drugs Frequently Used in Pediatric Anesthesia*

Drug	Older Children (13-18 yr)	Younger Children (2-12 yr)	Infants (1-23 months)	Neonates (1-30 days)
Alfentanil	Yes	No	No	No
Sufentanil	Yes	Yes	Yes	No
Fentanyl	Yes	Yes	No	No
Morphine	Yes	Yes	Yes	No
Propofol	Yes	†	No	No
Midazolam	No	No	No	No
Etomidate	Yes	‡	No	No
Dopamine	No	No	No	No
Dobutamine	No	No	No	No
Amrinone	No	No	No	No
Albuterol (inhaler)	Yes	No	No	No
Labetalol	No	No	No	No
Bupivacaine	Yes	No	No	No

* Physicians' Desk Reference. 49th edition. 1995.

† Not approved for children younger than 3 yr of age.

‡ Not approved for children younger than 10 yr of age.

the same proof of drug safety and efficacy as that required for adults. It is ironic that most major laws supporting the FDA's role in regulating drugs through changes in the Food, Drug, and Cosmetic Act were a direct result of adverse drug events in pediatric patients. As child health advocates, we wonder why the FDA does not mandate appropriate pediatric testing as a routine part of the drug approval process. Although the lawyers and insurance carriers have a significant influence on how medicine is practiced, it is imperative that physicians caring for children do what clinical experience and common sense tell us is the right thing.

Peter J. Davis, M.D.

Associate Professor of Anesthesiology, Critical Care Medicine, and Pediatrics

Julie A. Tome, M.D.

Assistant Professor of Anesthesiology
University of Pittsburgh School of Medicine

Children's Hospital of Pittsburgh
3705 Fifth Avenue at DeSoto Street
Pittsburgh, Pennsylvania 15213-2583

Francis X. McGowan, Jr., M.D.

Assistant Professor of Anesthesiology and Pediatrics
Department of Anesthesiology
Children's Hospital
300 Longwood Avenue
Boston, Massachusetts 02115-5747

Ira Todd Cohen, M.D.

Assistant Professor of Anesthesiology
Department of Anesthesiology
Children's Hospital National Medical Center
111 Michigan Avenue, NW
Washington, D.C. 20010-2970

(Accepted for publication March 9, 1995.)

Anesthesiology
82:1536-1537, 1995
© 1995 American Society of Anesthesiologists, Inc.
J. B. Lippincott Company, Philadelphia

Intraoperative Transcranial Doppler Monitoring

To the Editor:—Transcranial Doppler ultrasonography allows continuous noninvasive monitoring of cerebral blood flow velocity and represents an important advance in our ability to monitor intra-

cranial hemodynamics.¹ There are practical limitations to its routine intraoperative application, one of which is the constancy of the angle of insonation, *i.e.*, the angle between the direction of the probe and

CORRESPONDENCE

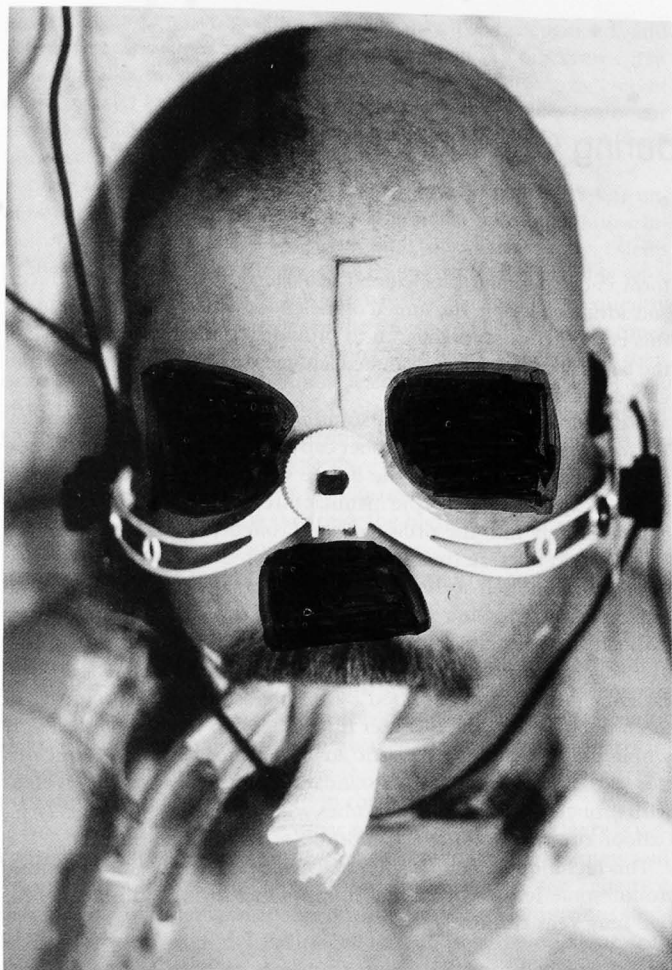


Fig. 1. The fixation frame viewed from above. The ear inserts and the foam-padded nose rest are used to anchor the frame without interfering with the potential surgical field. The adjustable Doppler transducers are mounted on the side-arms.

the direction of the artery segment being insonated. Many commercial fixation devices are available, all of which are based on a head-band or head-strap design. Although these devices are functional, they preclude use of the monitor in neurosurgical procedures, which is arguably the area where it can be most useful.

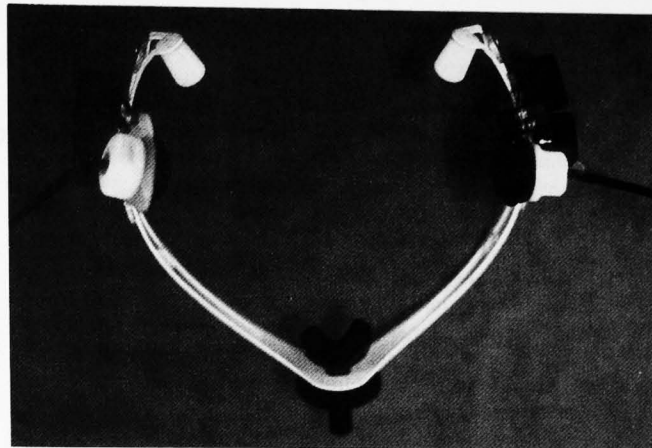


Fig. 2. The frame applied to a patient undergoing craniotomy for resection of a frontal-parietal arteriovenous malformation.

We wish to report our experiences with a custom-designed attachment system (in collaboration with DWL Electronics, Sipplingen, Germany) using ear inserts and a foam-padded nose rest to anchor the system, leaving the head unencumbered (figs. 1 and 2). The side-mounted transducers are equipped with swivel locks to fix the position, and the thumb wheel mounted on the nose rest allows alteration of tension to achieve optimal signals. With the exception of neurosurgical procedures using subtemporal incisions, its deployment causes no interference. We have used this system successfully for intraoperative monitoring in 12 cases with good results.

Arthur M. Lam, M.D.

Professor of Anesthesiology and Neurological Surgery
University of Washington School of Medicine
Department of Anesthesiology
Harborview Medical Center
325 Ninth Avenue, ZA-14
Seattle, Washington 98104

Reference

1. Eng CC, Lam AM, Newell DW, Byrd S: The diagnosis and management of a perianesthetic cerebral aneurysmal rupture with transcranial Doppler ultrasonography. *ANESTHESIOLOGY* 78:191-194, 1993

(Accepted for publication March 13, 1995.)