

Anesthesiology  
1997; 87:710-11  
© 1997 American Society of Anesthesiologists, Inc.  
Lippincott-Raven Publishers

## Intermittent Reduction in Myocardial Perfusion Causing ST Segment Oscillation after Cardiopulmonary Bypass

*To the Editor:*—Perioperative myocardial ischemia leading to episodes of ST segment deviation may be caused by a reduction in myocardial perfusion. Such episodes may not be accompanied by an increase in the heart rate (HR). They are likely to be observed during an infarct in evolution. After coronary artery bypass graft (CABG) surgery, most of the myocardial infarcts (MI) occur within 16 h after the release of aortic occlusion.<sup>1</sup>

ST segment oscillation, *i.e.*, multiple brief episodes of ST segment deviation, has not been reported perioperatively though it has been described during acute MI in ambulatory patients.<sup>2</sup> A case of multiple brief episodes of ST segment elevation after the end of cardioplegic arrest, presumably caused by intermittent reduction in myocardial perfusion is presented.

This 58-yr-old man who underwent CABG surgery had severe stenosis of the left anterior descending coronary artery, moderate stenosis of the dominant right coronary artery, marked hypokinesis of mid anterior wall of the left ventricle, and an ejection fraction of 45%.<sup>3</sup> Perioperatively, a Holter monitor (series 8500, Marquette Electronics, Milwaukee, WI) was used to record the ECG. Bipolar ECG leads modified CM<sub>5</sub> and modified ML were recorded.<sup>3</sup>

The Holter recording was processed using Marquette 8000 scanner. ST segment deviation was measured in sinus beats 60 ms after the J point. The HR and ST segment deviation values in leads CM<sub>5</sub> and ML were updated every 20 s and the trends plotted (fig 1). Aortic occlusion ended at 10:19 h. A total of 300 mg of protamine was administered in divided doses between 11:02 h and 11:10 h.

Immediately after defibrillation at the end of CPB, there was an episode of ST segment elevation. There were multiple episodes of ST segment elevation in lead ML from 12:45 h to 14:45 h. These episodes occurred in the absence of changes in HR, suggesting reduced myocardial perfusion as the etiology. Postoperatively, the highest CK-MB value was 40 IU/l. The EF by MUGA was 55.3%. There was mild hypokinesis of the interventricular septum although the anterior wall of the left ventricle

had normal motion. Although ST segment oscillation was observed in inferior lead ML, motion of the inferior wall was normal postoperatively.

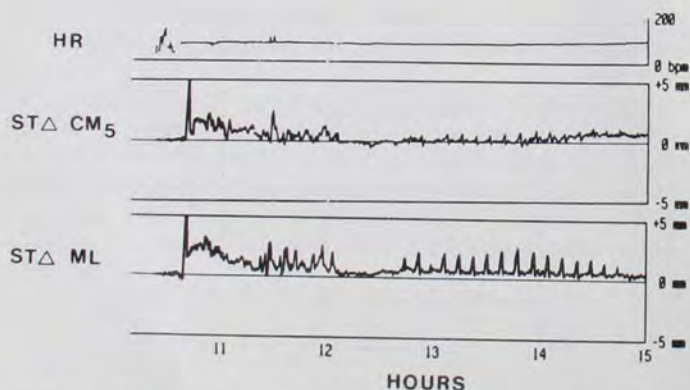
In ambulatory patients, in the initial phase of acute MI, intermittent flow in infarct related artery is common. ST segment deviation correlates with inadequate myocardial perfusion due to coronary occlusion and resolves due to spontaneous reperfusion.<sup>4</sup> Recurrence of ST segment deviation is due to reocclusion caused by increased thrombin generation and a procoagulant effect of spontaneous thrombolysis.<sup>2</sup> Compared to those with persistent ST segment elevation, patients with ST segment oscillation have slower development of and smaller area of myocardial necrosis, and may respond better to coronary vasodilators. Early episodes of coronary occlusion have a preconditioning effect.

In lead CM<sub>5</sub>, ST segment depression occurred briefly after many of the episodes of ST segment elevation. This is consistent with ST segment elevation being associated with greater level of ischemia than ST segment depression. ST segment oscillation of the type shown in figure 1 wherein ST segment deviation is completely resolved between the episodes of deviation is rare. However, changes in the amplitude of ST segment deviation occur routinely during perioperative episodes of ST segment deviation and may correspond to changes in myocardial perfusion. When ST segment deviation changes from beat to beat, it is called *ST segment alternans*.<sup>5</sup> It signifies temporal dispersion of repolarization and may be caused by myocardial ischemia.

This case demonstrates the phenomenon of ST segment oscillation occurring after CPB presumably due to a reduction in myocardial perfusion.

**Uday Jain, Ph.D., M.D.**

Assistant Professor of Anesthesia  
University of California, San Francisco  
4150 Clement St (129)  
San Francisco, California 94121



**Fig. 1.** The trends of heart rate (HR) in beats/min (bpm), and ST segment deviation in lead CM<sub>5</sub> (STΔ CM<sub>5</sub>) and lead ML (STΔ ML) after cardiopulmonary bypass.

### References

- Jain U, Laflamme CJA, Aggarwal A, Ramsay JG, Comunale ME, Ghoshal S, Ngo L, Ziola K, Hollenberg M, Mangano DT, for the McSPI Research Group: Electrocardiographic and hemodynamic changes and their association with myocardial infarction during coronary artery bypass surgery: A multicenter study. *ANESTHESIOLOGY* 1997; 86:576-91
- Haider A, Andreotti F, Hackett D, Tousoulis D, Kluff C, Maseri A, Davies G: Early spontaneous intermittent myocardial reperfusion during acute myocardial infarction is associated with augmented thrombogenic activity and less myocardial damage. *J Am Coll Cardiol* 1995; 26:662-7
- Jain U, Wallis DE, Moran JF: Significance of electrocardiographic ST elevation during coronary artery bypass surgery. *Anesth Analg* 1994; 78:638-43
- Krucoff MW, Croll MA, Pope JE, Granger CB, O'Connor CM, Sigmon KN, Wagner BL, Ryan JA, Lee KL, Kereiakes DJ, Samaha JK,

## CORRESPONDENCE

Worley SJ, Ellis SG, Wall TC, Topol EF, Califf RM, for the TAMI 7 Study Group: Continuous 12-lead ST-segment recovery analysis in the TAMI 7 Study. *Circulation* 1993; 88:437-46

5. Surawicz B, Fisch C: Cardiac alternans: Diverse mechanisms and clinical manifestations. *J Am Coll Cardiol* 1992; 20:483-99

(Accepted for publication June 16, 1997.)

Anesthesiology

1997; 87:711-2

© 1997 American Society of Anesthesiologists, Inc.

Lippincott-Raven Publishers

## A Solution to Monitoring the Electrocardiograph in Patients with Extensive Burn Injury

*To the Editor:*—In patients with extensive burns, it is sometimes a challenge to monitor the ECG, because the lack of natural skin and application of protective ointments prevent the adherence of the ECG discs. We have used the following modification to monitor ECG successfully in these patients.

The ends of a standard 3-lead ECG wires are cut and small alligator clips are attached to them (fig. 1). After the patient is well sedated or asleep, using a sterile stapler (Davis + Heck), three stainless steel




Fig. 1. ECG leads with alligator clips.

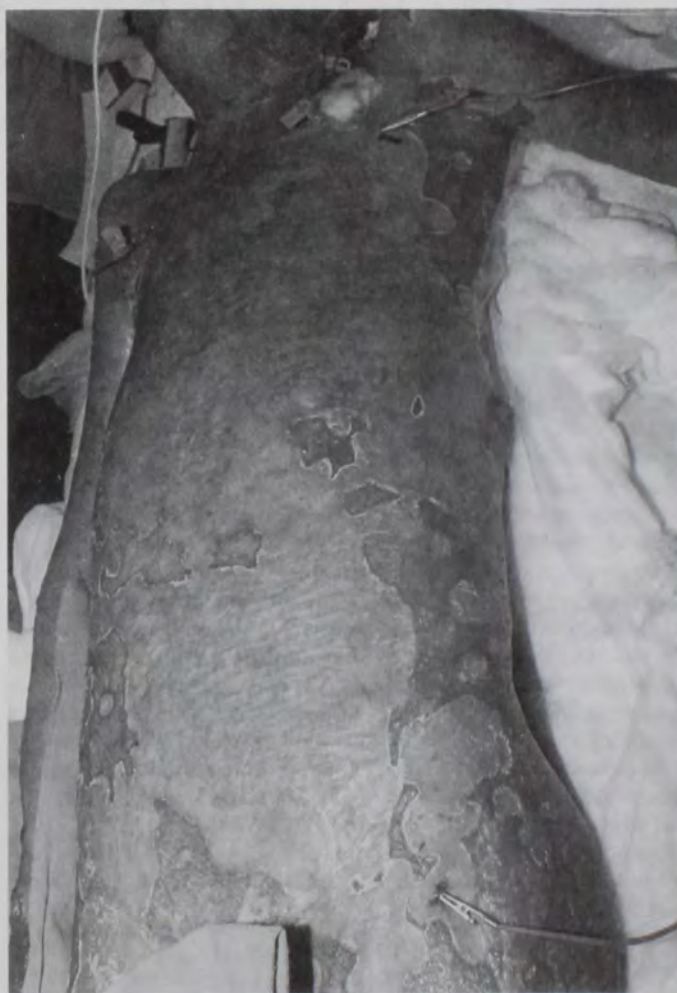

Fig. 2. ECG leads attached to the patient.

staples (35 wide; 6.9 mm × 3.8 mm) (fig. 2) are clipped to the skin near the right and left shoulders and left chest.

Because these staples are painful to place on an awake patient, one has to make sure that the patient is asleep or heavily sedated before the staples are placed. Some of these patients may already have staples in place to hold the homograft skin patches in place. The alligator clips are then attached to these staples. This provides