

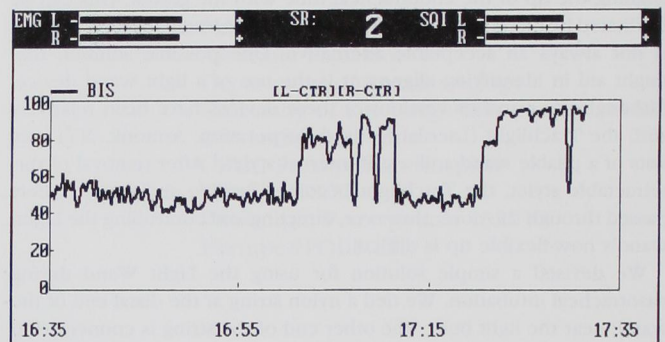
Anesthesiology  
 1999; 90:636  
 © 1999 American Society of Anesthesiologists, Inc.  
 Lippincott Williams & Wilkins, Inc.

## Pacer-induced Artifact in the Bispectral Index during Cardiac Surgery

*To the Editor:*—Bispectral analysis allows quantification of the inter-compartmental relations that characterize nonlinear signals, such as electroencephalography.<sup>1</sup> The bispectral index provides an easy-to-understand extraction of relevant descriptive parameters derived from the signal-processed electroencephalography and has been used clinically to titrate depth of anesthesia.<sup>2</sup> Cardiac surgery is considered a high-risk procedure for intraoperative awareness, and monitoring of the bispectral index might be expected to reduce the incidence of this complication.<sup>3</sup>

An 81-yr-old man with a recent increase in the frequency of his angina presented for triple-vessel aortocoronary bypass. After establishment of monitoring, induction, and maintenance of anesthesia with 10 mg intravenous diazepam, 500 µg intravenous fentanyl, 150 mg intravenous thiopental, 8 mg intravenous pancuronium, and 0.4–1.2% isoflurane, the bispectral index (Model A-1050; Aspect Medical Systems, Framingham, MA) ranged from 30–60 (indicating adequate sedation) throughout the prebypass and bypass periods. Normothermic bypass with intermittent antegrade and retrograde administration of cold-blood cardioplegia allowed performance of an internal mammary artery and two saphenous vein grafts. Weaning from bypass was accomplished without difficulty while the circulation was supported with 3 µg · kg<sup>-1</sup> · min<sup>-1</sup> dopamine. Because isoflurane was discontinued before weaning, 5 mg intravenous diazepam and 250 µg intravenous fentanyl were administered. A junctional rhythm at a rate of 70 beats/min was noted, and atrial pacing at a rate of 90 beats/min was begun. An increase in the bispectral index to 90, suggestive of arousal, was noted shortly thereafter. Isoflurane had been reintroduced, and an additional 5-mg dose of diazepam was given. When the bispectral index failed to decrease, artifact was suspected and the pacing was discontinued. The bispectral index returned to 50 shortly thereafter. Each time pacing was started, the bispectral index increased (fig. 1). Postoperative questioning elicited no evidence of recall.

The time of weaning from cardiopulmonary bypass requires intense concentration on the part of the entire operative team. Discontinuation of volatile agents to avoid myocardial depression is common, and use of the bispectral index should allow anesthetists to avoid patient awareness during this time. Even though the pacer-induced increase in the bispectral index in this patient was quickly recognized as artifactual, additional sedatives had been administered inappropriately. Figure 1 displays an electromyographic intensity of nearly 70% and a signal quality index of 50–60%, values that indicate less than optimal signal quality at the time the screen image was captured. However, 10



**Fig. 1.** Bispectral index trend display showing sudden increases from 50 to 90. These increases occurred during periods of atrial pacing and appear to represent artifact.

and 15 min earlier, electromyographic intensities were 0 and 20%, respectively, with signal quality indexes of 100 and 85%, respectively. These values suggest that poor signal quality was not responsible for the pacer-induced artifact observed. Hopefully, newer versions of the bispectral index will address and eliminate such artifacts, but those using existing devices should be aware of the possibility of pacer-induced artifact.

**John D. Gallagher, M.D.**  
 Professor of Anesthesiology  
 Dartmouth Medical School  
 Hanover, New Hampshire

### References

1. Sigl JC, Chamoun NG: An introduction to bispectral analysis for the electroencephalogram. *J Clin Monit* 1994; 10:392–404
2. Song D, Joshi GP, White PF: Titration of volatile anesthetics using bispectral index facilitates recovery after ambulatory anesthesia. *ANESTHESIOLOGY* 1997; 87:842–8
3. Hilgenberg JC: Intraoperative awareness during high-dose fentanyl-oxygen anesthesia. *ANESTHESIOLOGY* 1981; 54:341–3

(Accepted for publication October 30, 1998.)