

CASE REPORTS

and anesthesia in a neonate, especially those aged less than 2 months, may indicate an infectious problem either related or unrelated to the operative and anesthetic techniques. We report the first documented occurrence of aseptic meningitis in an infant after spinal anesthesia. Because of the infant's underlying status and recent life-threatening illness, it was not possible to definitely prove a causal relationship between the aseptic meningitis and the spinal anesthetic. Although no definitive treatment is necessary, the recognition of aseptic meningitis may avoid the prolonged and indiscriminate use of antibiotics if the fever is attributed to other sources.

References

1. Krane EJ, Haber Kern CM, Jacobson LE: Postoperative apnea, bradycardia, and oxygen desaturation in formerly premature infant: Prospective comparison of spinal and general anesthesia. *Anesth Analg* 1995; 80:7-13
2. Vandam L: Neurologic sequelae of spinal and epidural anesthesia. *Int Anesth Clin* 1986; 24:231-55
3. Black MG: Spinal fluid findings in spinal anesthesia. *ANESTHESIOLOGY* 1947; 8:382-9
4. Bert AA, Laasberg LH: Aseptic meningitis following spinal anesthesia: A complication of the past? *ANESTHESIOLOGY* 1985; 62:674-7
5. Lee JJ, Parry H: Bacterial meningitis following spinal anaesthesia for caesarean section. *Br J Anaesth* 1991; 66:383-6
6. Corbett JJ, Rosenstein BJ: Pseudomonas meningitis related to spinal anesthesia. *Neurology* 1971; 21:946-50
7. Laurila JJ, Kostamovaara PA, Alahuhta S: *Streptococcus salivarius* meningitis after spinal anesthesia. *ANESTHESIOLOGY* 1998; 89:1579-80
8. Neumark J, Feichtinger W, Gassner A: Epidural block in obstetrics followed by aseptic meningoencephalitis. *ANESTHESIOLOGY* 1980; 52:518-9
9. Goldman WW, Sanford JP: An "epidemic" of chemical meningitis. *Am J Med* 1960; 29:94-101
10. Phillips OC: Aseptic meningitis following spinal anesthesia. *Anesth Analg* 1970; 49:867-71
11. Phillips OC, Ebner H, Nelson AT, Black MH: Neurologic complications following spinal anesthesia with lidocaine: A prospective review of 10,440 cases. *ANESTHESIOLOGY* 1969; 30:284-9
12. Baraff LJ, Bass JW, Fleisher GR, Klein JO, McCracken GH, Powell KR, Schriger DL: Practice guidelines for the management of infants and children 0 to 36 months of age with fever without a source. *Pediatrics* 1993; 92:1-12

Anesthesiology
1999; 91:307-10

© 1999 American Society of Anesthesiologists, Inc.
Lippincott Williams & Wilkins, Inc.

Sildenafil Ameliorates Effects of Inhaled Nitric Oxide Withdrawal

Andrew M. Atz, M.D.,* David L. Wessel, M.D.†

INHALED nitric oxide (NO) is a selective pulmonary vasodilator with therapeutic importance in pulmonary hypertension and respiratory failure. NO increases intra-

cellular cyclic guanosine monophosphate (cGMP), which stimulates smooth muscle relaxation. Phosphodiesterase type 5 (PDE5) is found in high concentrations in the lung and contributes substantially to cGMP degradation within vascular smooth muscle.¹ Abrupt discontinuation of NO may be complicated by life-threatening events, and phosphodiesterase activity may play a role in this phenomenon.² Sildenafil (Viagra; Pfizer Laboratories, New York, NY) is a potent and selective inhibitor of cGMP-specific PDE5, the predominant isoenzyme that hydrolyzes cGMP in the corpus cavernosum.³ We hypothesized that sildenafil may potentiate pulmonary vasodilation with NO or ameliorate the deleterious effects of abrupt discontinuation of NO by increasing intracellular and circulating cGMP, preventing rapid depletion of cGMP when the gas is withdrawn.

* Assistant in Cardiology, Children's Hospital; Instructor in Pediatrics, Harvard Medical School.

† Director, Cardiac Intensive Care Unit, Children's Hospital; Associate Professor of Pediatrics (Anaesthesia), Harvard Medical School.

From the Department of Cardiology, Children's Hospital, and the Departments of Pediatrics and Anaesthesia, Harvard Medical School, Boston, Massachusetts. Submitted for publication September 16, 1998. Accepted for publication February 18, 1999. Dr. Atz is supported by an award from the National Institutes of Child Health and Human Development (# P30HD27805) and a grant from the United States Food and Drug Administration. Dr. Wessel is supported by grants from the United States Food and Drug Administration (# FDR-001316-01) and the Research Endowment of Children's Hospital (# 89430-02).

Address reprint requests to Dr. Wessel: Cardiac ICU Office, Children's Hospital, 300 Longwood Avenue, Farley 653, Boston, Massachusetts 02115. Address electronic mail to: wessel@a1.tch.harvard.edu

Key words: Congenital heart disease; cyclic guanosine monophosphate; phosphodiesterase inhibition; pulmonary hypertension; rebound pulmonary hypertension.

Case 1

A 6-week-old 3.1-kg female infant with complex bilateral pulmonary vein obstruction underwent surgical resection of an obstructive mem-

CASE REPORTS

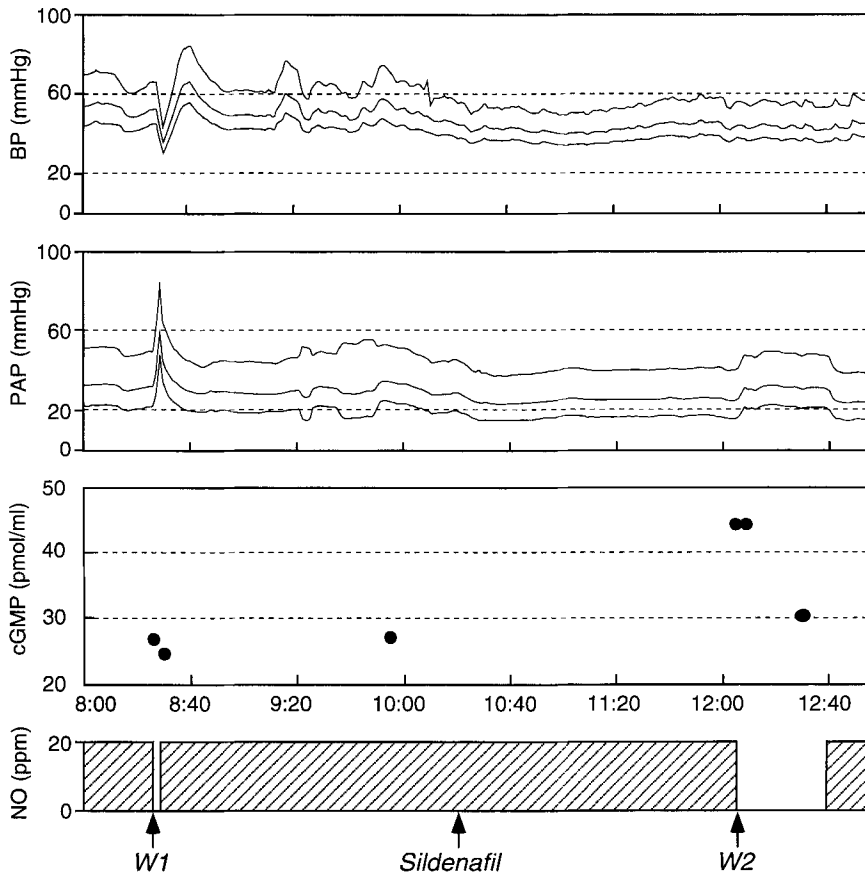


Fig. 1. Continuous trace of systolic, mean, and diastolic systemic blood pressure (BP) and pulmonary artery blood pressure (PAP) recorded every minute. Withdrawal of NO initially (W1) rapidly produces pulmonary hypertension, systemic hypotension, and a 10% decrease in cyclic guanosine monophosphate (cGMP) after 2 min. A 1-mg dose of sildenafil causes mild additional pulmonary vasodilation and dramatically blunts the pulmonary hypertensive effect of NO withdrawal 90 min later (W2). cGMP levels nearly doubled from baseline and remained above baseline levels for 30 min after sildenafil.

brane within the left atrium. The postoperative period was complicated by suprasystemic levels of pulmonary hypertension with systemic hypotension. After obtaining informed written consent from the parents, a trial of inhaled NO was performed according to a protocol approved by the Food and Drug Administration and the Clinical Investigation Committee at Children's Hospital. Mean pulmonary artery pressure was selectively reduced from 57 mmHg to 33 mmHg during NO inhalation at 20 ppm. Radioimmunoassay measurements of cGMP (Amersham RPA 545; Amersham International Ltd., Buckinghamshire, United Kingdom) from a systemic artery increased from 12 pmol/ml at baseline to 28 pmol/ml with NO. Subsequent attempts to withdraw NO were associated with a rapid increase in pulmonary artery pressure, systemic hypotension, and oxygen desaturation. After the third unsuccessful attempt at withdrawal, NO was reinstated, and a 1-mg dose of sildenafil was administered through a nasogastric tube. This dosage was approximately one half of the weight-adjusted dose for an adult (50 mg for a 70-kg man). Ninety minutes later NO again was withdrawn with minimal increase in pulmonary artery pressure, which remained stable over 30 min (fig. 1). cGMP nearly doubled after sildenafil administration (28 pmol/ml to 45 pmol/ml) and remained elevated after NO was withdrawn. NO was restarted to maximize clinical recovery, and the patient was later weaned without incident.

Case 2

A 3.5-kg newborn female infant with infradiaphragmatic total anomalous pulmonary venous connection that was obstructed underwent

surgical correction on the day she was born. Systemic hypotension, low cardiac output, and pulmonary hypertension complicated the initial postoperative period. NO was administered *via* inhalation and immediately reduced mean pulmonary artery pressure from systemic to half-systemic levels; it was continued at 20 ppm. On the third postoperative day after failed withdrawal (mean pulmonary artery pressure increased to 40 mmHg within 3 min), NO was reinstated, and 1 mg of sildenafil was administered *via* a nasogastric tube. NO was withdrawn 70 min later with only a mild (6 mmHg) increase in pulmonary artery pressure (peak mean, 28 mmHg). This pressure remained stable for 1 hr. cGMP levels were 19 pmol/ml on NO before withdrawal. One hour after NO reinstatement at 20 ppm and sildenafil administration, cGMP was 30 pmol/ml. cGMP remained greater than initial baseline levels at 15 (29 pmol/ml), 30 (24 pmol/ml) and 60 (23 pmol/ml) min after NO withdrawal.

Case 3

A 4-month-old 4.1-kg male infant with severe bilateral pulmonary vein stenosis after neonatal repair of supracardiac total anomalous pulmonary venous connection underwent surgical revision. Postoperatively, the patient had moderately elevated mean pulmonary artery pressure, and a trial of NO was administered. Mean pulmonary artery pressure decreased from 27 mmHg to 19 mmHg with NO at 80 ppm, whereas cGMP increased from 27 pmol/ml at baseline to 135 pmol/ml.

CASE REPORTS

Administration of NO was continued at 20 ppm. Three daily attempts to withdraw NO with the immediate appearance of suprasystemic pulmonary artery pressure resulted in failure. After the third failed attempt, a 1.1-mg dose of sildenafil was given *via* a nasogastric tube; NO was withdrawn 70 min later. Again, there was an immediate increase in pulmonary artery pressure with a time course and amplitude that was nearly identical to previous withdrawal attempts. However, cGMP levels showed that sildenafil administration caused only a slight increase in cGMP (from 19 to 22 pmol/ml). Presumably, because gastrointestinal absorption was a known problem in this patient, poor absorption hindered the effect of the drug, and placement of a jejunostomy tube for feeding was subsequently required. NO was again started, slowly weaned over the next week, and ultimately discontinued from 1 ppm after 16 days of therapy.

Discussion

Rebound pulmonary hypertension caused by withdrawal of inhaled NO was markedly attenuated in two patients by increasing cGMP with sildenafil. In a third patient with poor gastrointestinal absorption, cGMP levels did not increase with sildenafil, and rebound pulmonary hypertension was not blunted. Rebound pulmonary hypertension is not unique to inhaled vasodilators, but its causes are unclear. Mechanisms underlying the adverse effects of NO withdrawal may involve reduced production of endogenous NO and reduced capacity to generate quickly cGMP when exogenous NO is discontinued.⁴ Negative feedback inhibition by exogenous NO has been postulated to account for this observation⁵ and has been demonstrated to exist for inducible⁶ and endothelial⁷ NO synthase *in vitro*. Decreased endogenous production of exhaled NO from smokers could also support a negative feedback theory.⁸ PDE5 inhibition augments and prolongs responses to NO in animal models and increases the release of cGMP.⁹ Dipyridamole, the only PDE5 inhibitor thus far described in humans, attenuated increases in pulmonary artery pressure after NO withdrawal following cardiac surgery. This may be related to inhibition of vascular smooth muscle cGMP degradation, although that was not confirmed with cGMP measurements.² However, dipyridamole has non-specific effects and may also block adenosine reuptake in endothelial cells and erythrocytes. Dukarm *et al.*¹⁰ showed that systemic hypotension is a limiting feature of dipyridamole when used in a lamb model of persistent pulmonary hypertension of the newborn.

In cases 1 and 2, we confirmed a near doubling of circulating cGMP using the newly available, more specific PDE5 inhibitor. In case 3, there was not a significant increase in cGMP after sildenafil administration. Because the latter child had generated a fourfold increase in

cGMP from baseline when NO was initially begun, we were inclined to attribute the inability to attenuate the NO withdrawal response to poor drug absorption and failure to effect an increase in cGMP. Although cGMP is an intracellular second messenger, the precise source of plasma cGMP is unknown. However, our preliminary observation demonstrates an association between a successful increase in cGMP level and the blunting of the pulmonary hypertensive response to NO withdrawal. This study may support the important role of the phosphodiesterase system in the genesis and treatment of pulmonary hypertension.

We speculate that exogenous NO produces a negative feedback inhibition of NO synthase activity with a rapid reduction of pulmonary vascular smooth muscle cGMP when inhaled NO is abruptly withdrawn. Preliminary animal studies suggest that there is indeed a reduction in NO synthase enzyme activity but not gene expression,¹¹ consistent with the short duration of rebound pulmonary hypertension that we previously described in this population of patients with total anomalous pulmonary venous connection.¹² Alternative strategies aimed at increasing cGMP may facilitate withdrawal of NO. PDE5 inhibitors may be useful when NO is incompletely effective, when NO delivery must be interrupted for patient transport, or to assist in weaning from prolonged NO therapy. Sildenafil as an oral pulmonary vasodilator alone or in conjunction with NO merits further evaluation. Carefully designed studies of its possible therapeutic use and potential toxicity in the pediatric population may be warranted.

We do not advocate casual "off label" use of sildenafil as an oral pulmonary vasodilator, especially in children. Caution must be taken in patients who might have high circulating levels of cGMP, such as those with sepsis in whom small concentrations of a PDE5 inhibitor may precipitate significant hypotension. Sildenafil is contraindicated in patients receiving oral or intravenous nitrates, in whom refractory hypotension may ensue. Sildenafil is eliminated primarily by a hepatic route and is converted to an active metabolite. Both forms have terminal half-lives of approximately 4 hr in human adults. Patients with hepatic dysfunction and those taking drugs that interact with the cytochrome system may have reduced clearance of the sildenafil. Other limitations and unknown side effects must be carefully considered before using this drug.

References

1. Sanchez LS, de la Monte SM, Filippov G, Jones RC, Zapol WM, Bloch KD: Cyclic-GMP-binding, cyclic-GMP-specific phosphodiesterase

CASE REPORTS

(PDE5) gene expression is regulated during rat pulmonary development. *Pediatr Res* 1998; 43:163-8

2. Ivy DD, Kinsella JP, Ziegler JW, Abman SH: Dipyridamole attenuates rebound pulmonary hypertension after inhaled nitric oxide withdrawal in postoperative congenital heart disease. *J Thorac Cardiovasc Surg* 1998; 115:875-82

3. Boolell M, Gepi-Attee S, Gingell JC, Allen MJ: Sildenafil, a novel effective oral therapy for male erectile dysfunction. *Br J Urol* 1996; 78:257-61

4. Goldman AP, Haworth SG, Macrae DJ: Does inhaled nitric oxide suppress endogenous nitric oxide production? *J Thorac Cardiovasc Surg* 1996; 112:541-2

5. Buga GM, Griscavage JM, Rogers NE, Ignarro LJ: Negative feedback regulation of endothelial cell function by nitric oxide. *Circ Res* 1993; 73:808-12

6. Assreuy J, Cunha FQ, Liew FY, Moncada S: Feedback inhibition of nitric oxide synthase activity by nitric oxide. *Eur J Pharmacol* 1993; 108:833-7

7. Ravichandran LV, Johns RA, Rengasamy A: Direct and reversible inhibition of endothelial nitric oxide synthase by nitric oxide. *Am J Physiol* 1995; 268:H2216-23

8. Gerlach H, Rossaint R, Pappert D, Knorr M, Falke KJ: Autoinhalation of nitric oxide after endogenous synthesis in nasopharynx. *Lancet* 1994; 343:518-9

9. Ichinose F, Adrie C, Hurford W, Zapol W: Prolonged pulmonary vasodilator action of inhaled nitric oxide by zaprinast in awake lambs. *J Appl Physiol* 1995; 78:1288-95

10. Dukarm RC, Morin FC, Russell JA, Steinhorn RH: Pulmonary and systemic effects of the phosphodiesterase inhibitor dipyridamole in newborn lambs with persistent pulmonary hypertension. *Pediatr Res* 1998; 44:831-7

11. Black SM, Heidersbach RS, McMullan DM, Fineman JR: Inhaled nitric oxide inhibits NOS activity in lambs: A potential mechanism for rebound pulmonary hypertension (abstract). *Crit Care Med* 1999; 27:A39

12. Atz AM, Adatia I, Wessel DL: Rebound pulmonary hypertension after inhalation of nitric oxide. *Ann Thorac Surg* 1996; 62:1759-64

Anesthesiology

1999; 91:310-2

© 1999 American Society of Anesthesiologists, Inc.

Lippincott Williams & Wilkins, Inc.

Rhabdomyolysis after Abdominal Surgery in the Hyperlordotic Position Enforced by Pneumatic Support

Yuko Uratsuji, M.D., Ph.D.,* Kazuko Ijichi, M.D.,† Jun Irie, M.D.,† Kenichiro Sagata, M.D.,†
Kuniyuki Nijima, M.D.,† Sanji Kitamura, M.D.‡

ENFORCED patient positioning in surgery may lead to serious complications such as rhabdomyolysis, peripheral nerve palsy, or other tissue damage.¹⁻⁵ We report a patient who developed rhabdomyolysis and renal insufficiency after 11 h in the hyperlordotic supine position.

Case Report

A 61-yr-old, 164-cm, 65-kg male was scheduled for a pancreatoduodenostomy for pancreatic carcinoma. He had been healthy and had no

history of muscle disease, renal disease, or hypertension. He was taking no medications.

Upon admission, physical examination was unremarkable, but high levels of serum glutamic-oxaloacetic transaminase (150 U/l), serum glutamic-pyruvic transaminase (364 U/l), serum γ -glutamyl transpeptidase (249 U/l), and alkaline phosphatase (485 U/l) were noted. Creatine kinase level was 168 U/l.

The patient received 10 mg of diazepam for sedation. After general anesthesia was induced with thiopental, fentanyl, and vecuronium, maintenance was conducted with sevoflurane, nitrous oxide, and vecuronium. An epidural catheter was inserted at the level of Th12/L1. Bupivacaine 0.125% was intermittently administered throughout surgery.

After the induction of anesthesia, the inflatable bladder of a blood pressure cuff was placed under the patient's back at the level of the lower thoracolumbar spine. The cuff was inflated to obtain the desired hyperlordotic position for surgical access. Surgery was performed with the patient in the supine position with the cuff inflated continuously for 11 h. Throughout the procedure, systolic blood pressure was maintained at approximately 100-120 mmHg. The blood loss of 1,300 ml was replaced with albumin and crystalloid solutions. The procedure was complicated by an accidental right renal artery disruption, which was successfully reconstructed in 45 min. After this accident, to maintain blood pressure and urine output, in addition to hydration, dopamine 2-8 $\mu\text{g} \cdot \text{kg}^{-1} \cdot \text{min}^{-1}$ was started until the end of surgery. The

* Chief Anesthesiologist, Kobe Rosai Hospital.

† Staff Anesthesiologist, Kobe Rosai Hospital.

‡ Chief Anesthesiologist, National Kobe Hospital.

Received from the Departments of Anesthesia, Kobe Rosai Hospital and National Kobe Hospital, Kobe, Japan. Submitted for publication November 10, 1998. Accepted for publication March 15, 1999. Support was provided solely from institutional and departmental sources.

Address reprint requests to Dr. Uratsuji: Department of Anesthesia, Kobe Rosai Hospital, Kagoike-dori, 4-1-23, Chuo-ku, Kobe 651-0053, Japan.

Key words: Positioning; postoperative complications; renal failure.