

CASE REPORTS

crease the amount of sodium nitroprusside needed to control blood pressure in this patient. These two case reports document the successful use of fenoldopam in patients with renal impairment during pheochromocytoma resection.

References

1. Ohlstein E, Zabko-Potpovich B, Berkowitz B: Studies on vascular dopamine receptors with the dopamine receptor agonist: SKF 82526. *J Pharmacol Exp Ther* 1984; 229:433-9
2. Kohli J, Glock D, Goldberg L: Relative DA1 dopamine receptor agonist and alpha-adrenoceptor antagonist activity of fenoldopam in the anesthetized dog. *J Cardiovasc Pharmacol* 1988; 11:123-6
3. Elliott W, Webster R, Nelson K: Renal and hemodynamic effects of intravenous fenoldopam versus nitroprusside in severe hypertension. *Circulation* 1990; 81:970-7
4. White W, Radford M, Bonzalez F: Selective dopamine 1 agonist

therapy in severe hypertension: Effects of intravenous fenoldopam. *J Am Coll Cardiol* 1988; 11:1118-23

5. Bodmann K, Troster S, Clemens R: Hemodynamic profile of intravenous fenoldopam in patients with hypertensive crisis. *Clin Invest* 1993; 72:60-4
6. Fenolopam—A new drug for parenteral treatment of severe hypertension. *The Medical Letter* 1998; 40:57-8
7. Brunjes S, Johns V, Crane M: Pheochromocytoma: Postoperative shock and blood volume. *N Engl J Med* 1960; 262:393-6
8. Singer I, Epstein M: Potential of dopamine A-1 agonists in the management of acute renal failure. *Am J Kidney Dis* 1998; 31:743-55
9. Shusterman N, Elliott W, White W: Fenolopam, but not nitroprusside, improves renal function in severely hypertensive patients with impaired renal function. *Am J Med* 1993; 95:161-8
10. Mihm F: Pheochromocytoma: Decreased perioperative mortality. *Anesth Clin North Am* 1998; 16:645-62
11. Mihm FG: Pulmonary artery pressure monitoring in patients with pheochromocytoma. *Anesth Analg* 1983; 62:1129-33

Anesthesiology

1999; 91:560-2

© 1999 American Society of Anesthesiologists, Inc.

Lippincott Williams & Wilkins, Inc.

The Case of the Missing Fragment: Detection and Retrieval of a Portion of Broken Valve as It Was Ejected from the Heart

Luis G. Michelsen, M.D.,* Jack S. Shanewise, M.D.*

EMBOLISM of air and small particles during cardiac valve surgery is seen often, but the embolism of large valve fragments is uncommon. We report a case in which a prosthetic valve fractured during its removal, and a large portion of it could not be found. After cardiopulmonary bypass, transesophageal echocardiography (TEE) re-

vealed a broken fragment as it was ejected from the heart, and it was retrieved immediately.

Case Report

A 61-yr-old woman with a prosthetic mitral valve who was taking warfarin for anticoagulation therapy was admitted to the hospital after episodes of visual disturbances and slurred speech. Her mitral valve had been replaced twice: first in 1983 for mitral stenosis, and then 10 yr later for deterioration of the bioprosthetic valve. A 29-mm bileaflet mechanical valve (St. Jude Medical Heart Valve, St. Paul, MN) was implanted at that time and she had received warfarin since then, maintaining an international normalized ratio of ≥ 2.5 . She also had atrial fibrillation-flutter, and 2 yr before the current admission had undergone an atrioventricular node ablation and placement of a permanent pacemaker. A TEE was done to evaluate a possible source of embolus as the cause of her current symptoms. The TEE revealed spontaneous echo contrast in the left atrium, a prosthetic mitral valve with normal movement of its leaflets, and a mobile small mass attached to the prosthetic mitral valve, suggestive of a clot.

Two days later, the patient underwent a mitral valve replacement. She was anesthetized with fentanyl, midazolam, and thiopental, and her trachea was intubated without complication. Arterial and pulmonary artery catheters were placed for hemodynamic monitoring, and TEE (Multiplane TEE probe, Hewlett Packard, Andover, MA) was used during the surgery to evaluate contractility and valve function and to

Additional material related to this article can be found on the ANESTHESIOLOGY Web Site. Go to the following address, and then scroll down to find the title link for this article. <http://www.anesthesiology.org/tocs/v91n2-TOC.cfm>

* Assistant Professor.

Received from the Department of Anesthesiology, Emory University School of Medicine, Atlanta, Georgia. Submitted for publication December 23, 1998. Accepted for publication April 1, 1999. Support was provided solely from institutional and/or departmental sources.

Address reprint requests to Dr. Michelsen: Department of Anesthesiology, Emory University School of Medicine, Atlanta, Georgia 30322. Address electronic mail to: Luis_Michelsen@emory.org

Key Words: Embolism; mitral valve; prosthetic valve dysfunction; transesophageal echocardiography.

CASE REPORTS

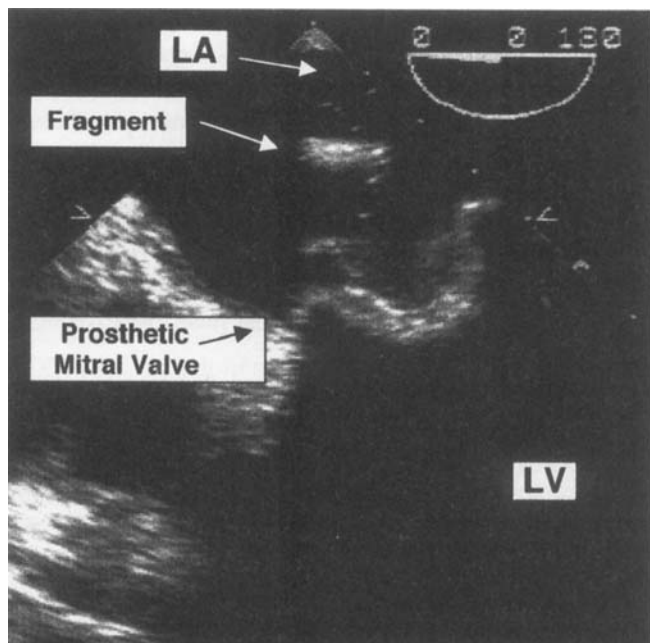


Fig. 1. A transesophageal echocardiographic image of the left atrium obtained after cardiopulmonary bypass was discontinued shows an echodense object (fragment) in the left atrium (LA), above the bioprosthetic mitral valve. LV = left ventricle.

detect air. During operation, the TEE confirmed the previous findings, identifying a 4- to 5-mm mobile mass attached to the ventricular surface of the prosthetic mitral valve. Cardiopulmonary bypass was instituted and the heart arrested with cardioplegia after the aorta was cross-clamped. The left atrium was small and both the left and right atrium and the interatrial septum were opened to facilitate exposure. During explantation of the prosthetic mitral valve, traction on one of the metallic leaflets resulted in abrupt dislodgment of the disk. When the dislodged disk was removed, a large portion was missing. The valve was removed and a small organized clot was found attached to the ventricular side of the prosthetic ring. The left ventricle and atrium were explored, without evidence of the missing fragment. Despite extensive use of irrigation and suctioning, the fragment could not be found in the left atrium, the pulmonary veins, the left ventricle cavity, or other areas of the surgical wound or the operative field. The aorta was opened to determine if the fragment had traveled beyond the aortic valve, but the fragment was not there either. A thoracoscope was used to better visualize the left ventricle, left atrium, and pulmonary veins, but without success. Because the disk fragment could not be located, the surgery proceeded and the mitral valve was replaced by a #29 bioprosthetic mitral valve. After the aortic clamp was removed, the patient rewarmed, and the heart de-aired, the patient was weaned from cardiopulmonary bypass with inotropic support. A few minutes after weaning, TEE briefly revealed a dense object in the left atrium (fig. 1), and it was seen again in the aortic valve (fig. 2). The surgeons were informed immediately. An aortic cross-clamp was applied rapidly and cardiopulmonary bypass was restored. After administration of cardioplegia, the aorta was opened. A metallic fragment was found inside the noncoronary cusp of the aortic valve. When this fragment was placed next to the major portion of the damaged leaflet, it was

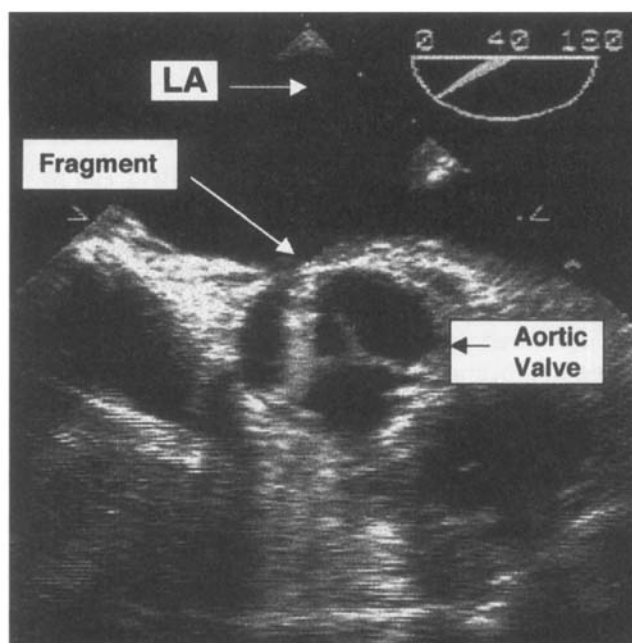


Fig. 2. A transesophageal echocardiographic image of the aortic valve with an echodense object (fragment) on the noncoronary cusp. LA = left atrium.

evident that the broken edges did not match and that a small segment was still missing (fig. 3). Detailed inspection of the aorta and the left ventricle through the aortic valve did not yield any additional pieces. The aorta was closed and the patient was again weaned from cardiopulmonary bypass without difficulty. No further fragments were seen with TEE and the rest of the surgery proceeded without complication. The patient's trachea was extubated 6 h after the end of the surgery and no new neurologic deficits were noted. Postoperative chest and abdominal radiographs did not reveal the missing fragment, and the patient continued to recuperate. She was discharged home 9 days after




Fig. 3. The explanted St. Jude valve, with the fractured disk to the right. The smaller fragment was recovered from the aortic valve. Note the missing portion of the leaflet.

her operation. In a follow-up visit at 6 weeks, the patient was doing well.

Discussion

This dramatic case illustrates how useful TEE can be in patients undergoing valve replacement. It allowed us to detect a broken valve fragment as it went through the left heart and to act in time to prevent its systemic embolization. Without TEE, we would not have discovered the large fragment and probably it would have lodged in a major vessel.

Fracture of an implanted prosthetic heart valve with embolization of fragments has been reported, particularly with the Björk-Shiley convexo-concave cardiac prosthesis,^{1,2} but is uncommon with the St. Jude Medical valve.³⁻⁵ Burkhardt *et al.*³ reported an incidence of 0.05% of this type of mechanical failure in 828 patients with implanted St. Jude Medical valves, and given the paucity of reports in the last 10 yr, the incidence may be even less today. More recently, Akiyama *et al.*⁶ reported fracture of a leaflet of a St. Jude Medical valve during implantation, which was attributed to excessive indirect pressure to the ring. They retrieved the fragments without problems. In the current case, fracture of the prosthetic leaflet resulted from the application of direct traction to it with a hemostat. The physician's manual for the St. Jude Medical valve specifically advises not to apply any metallic instruments to the leaflets as this "... may exceed the fracture strength of the valve components."⁷ Although cardiac surgeons are typically careful when they implant the valve, this case shows that even if the valve is being removed, fracture of a leaflet is not without risk for the patient.

Most likely, the recovered fragment had sunk deep into a pulmonary vein and was not seen despite suctioning and use of a telescopic camera. Once the patient was weaned from cardiopulmonary bypass, blood flow through the pulmonary circulation carried the fragment downstream into the left atrium and left ventricle, from where it was ejected to the aorta. If the fragment had not been detected by TEE and the aorta was promptly clamped, the fragment probably would have embolized distally, and, because of its large size (9.3 × 8.1 mm), obstructed a major vessel.

It is not clear what happened to the portion of the broken leaflet that was not recovered. It was not seen on the postoperative chest and abdominal radiographs, despite the fact that the graphite substrate of the leaflets is impregnated with radiopaque material (tungsten) to facilitate radiographic detection.⁷ Magnetic resonance imaging can detect microscopic embolic metal fragments because of the ferromagnetic artifact they produce.⁸ A magnetic resonance image scan was not done because the patient did not have any unusual postoperative signs or symptoms.

In conclusion, we described a case in which a large fragment of a fractured St. Jude Medical valve was detected by TEE as it was being ejected from the heart, allowing the surgeons to remove it immediately and prevent its systemic embolization. This case is yet another example of the utility of TEE in cardiac valve surgery.

References

1. van der Graaf Y, de Waard F, van Herwerden LA, Defauw J: Risk of strut fracture of Björk-Shiley valves. *Lancet* 1992; 339:257-61
2. Aris A, Ramio J, Montiel J, Ruyra X, Padro JM: Retrograde strut embolization in a fractured Björk-Shiley mitral prosthesis. *J Heart Valve Dis* 1994; 3:117-19
3. Burkhardt D, Striebel D, Vogt S, Hoffmann A, Roth J, Weiss P, Kiowski W, Pfisterer M, Burkart F, Althaus U, Goy JJ, Sadeghi H, Grädel E: Heart valve replacement with St. Jude Medical valve prosthesis. Long-term experience in 743 patients in Switzerland. *Circulation* 1988; 78(suppl 1):118-24
4. Debétaz L-F, Ruchat P, Hurni M, Fischer A, Stumpe F, Sadeghi H, van Melle G, Goy JJ: St. Jude Medical valve prosthesis: An analysis of long-term outcome and prognostic factors. *J Thorac Cardiovasc Surg* 1997; 113:134-48
5. Hjelms E: Escape of a leaflet from a St. Jude Medical prosthesis in the mitral position. *Thorac Cardiovasc Surgeon* 1983; 31:310-12
6. Akiyama K, Hirota J, Takiguchi M, Ohsawa S, Hashimoto A, Nagumo T, Sasaki S: The leaflet fracture of a 19 mm SJM (HP) valve during valve insertion to the calcified small aortic annulus. *Kyobu Geka (Japanese Journal of Thoracic Surgery)* 1997; 50:562-4
7. Physician's Manual, St. Jude Medical® Pyrolytic Carbon Heart Valve. St. Paul, MN, St. Jude Medical, 1988
8. Wingerchuk DM, Krecke KN, Fulgham JR: Multifocal brain MRI artifacts secondary to embolic metal fragments. *Neurology* 1997; 49:1451-3