

CASE REPORTS

Anesthesiology
1999, 91:563-5
© 1999 American Society of Anesthesiologists, Inc.
Lippincott Williams & Wilkins, Inc.

Major Ambulatory Surgery with Continuous Regional Anesthesia and a Disposable Infusion Pump

Stephen M. Klein, M.D.,* Roy A. Greengrass, M.D., F.R.C.P.,† David H. Gleason, C.R.N.A.,‡ James A. Nunley, M.D.,§
Susan M. Steele, M.D.*

CONTINUOUS peripheral nerve blockade can provide prolonged postoperative analgesia. By infusing local anesthetic through a catheter, neural blockade can be achieved that lasts longer than a single-injection block.^{1,2} Traditionally, this method of pain relief has required a cumbersome infusion pump and a hospital stay. Reconstructive surgery of the foot or ankle can result in severe postoperative pain that is difficult to treat. Frequently, patients having such procedures require large doses of intravenous narcotics, which make early hospital discharge difficult. By using an anesthetic method that can provide improved analgesia and obviate a prolonged hospital stay, ambulatory surgery may be facilitated. We describe two patients undergoing major ankle surgery. Both patients were discharged to their homes with a continuous sciatic nerve block and a disposable infusion pump.

Case Reports

Case 1

A 31-yr-old man in good health (weight, 81 kg; height, 176 cm), classified as American Society of Anesthesiologists (ASA) physical status I, was scheduled for left ankle subtalar fusion to repair damage from a previous calcaneus fracture.

The patient was brought to the preoperative holding area and plans

* Assistant Professor, Department of Anesthesiology.

† Associate Professor, Department of Anesthesiology.

‡ Coordinator, Division of Ambulatory Anesthesia.

§ Professor, Department of Surgery.

Received from Duke University Medical Center, Durham, North Carolina. Submitted for publication October 21, 1998. Accepted for publication March 15, 1999. Support was provided solely from institutional and/or departmental resources.

Address reprint requests to Dr. Klein: Department of Anesthesiology, Box 3094, Duke University Medical Center, Durham, North Carolina 27710. Address electronic mail to: klein006@mc.duke.edu

Key words: Catheter; lower extremity; sciatic nerve block.

for a continuous popliteal fossa sciatic nerve block and a psoas compartment lumbar plexus block were presented. The potential for prolonged analgesia and the potential risks for an indwelling catheter infusing local anesthetic were discussed. Because a same-day discharge was planned, the signs and symptoms of local anesthetic toxicity were reviewed with the patient and his wife, as was care for removal of the catheter. Both the patient and his wife agreed to the plan.

After application of routine monitors and administration of supplemental oxygen, the patient was sedated intravenously using 3 mg midazolam and 150 µg fentanyl (in divided doses). Using a solution of 30 ml of ropivacaine, 0.5%, with 1:400,000 epinephrine, the anesthesia team performed a lumbar plexus block using the technique initially described by Chayen *et al.*³ This was done to provide tourniquet anesthesia during the surgery and anesthesia in the saphenous nerve distribution. The patient was placed in the prone position for placement of the sciatic catheter using a technique similar to that described by Singelyn *et al.*⁴ The apex of the popliteal fossa was identified and a needle entry site was marked 1 cm lateral to this point.⁵ Using a nerve stimulator connected to an 18-gauge, 100-cm insulated Tuohy needle (B. Braun Medical, Bethlehem, PA) attached *via* extension tubing to a syringe, the needle was advanced anteriorly.⁶ After stimulating plantar flexion with a current less than 0.6 mA and a negative aspiration for blood, 30 ml of ropivacaine, 0.5%, with 1:400,000 fresh epinephrine was injected in divided doses. Maintaining the needle in the same position, a 20-gauge standard epidural catheter was threaded 10 cm into the sciatic nerve sheath secured with medical adhesive, cutaneous adhesive sutures (Ethicon, Somerville, NJ), and occlusive dressing. At the patient's request, a general anesthetic was used for intraoperative management. An additional 100 µg intravenous fentanyl was administered during the operation.

At the conclusion of the procedure, the patient emerged from anesthesia without complication and was transferred to the postanesthesia care unit. He was free of pain and had complete motor blockade below the left knee. Before discharge (4.5 h after block placement), a 270-ml disposable elastometric infusion pump (Homepump; Block Medical, San Diego, CA) was connected to the sciatic catheter (fig. 1). The pump contained ropivacaine, 0.2%, and had a nonadjustable infusion rate of 10 ml/h. The patient was given written discharge instructions for removing the catheter in 27 h and the name of a person to contact if symptoms of local anesthetic toxicity developed.

The patient returned home and remained pain free until approximately 24 h after the initial nerve block had been placed. At that time, he reported discomfort over the medial aspect of the incision in the saphenous nerve distribution, which was relieved with 350 mg oral acetaminophen with 5 mg oxycodone. Motor function had returned during the night, approximately 15 h after his initial block. The pa-

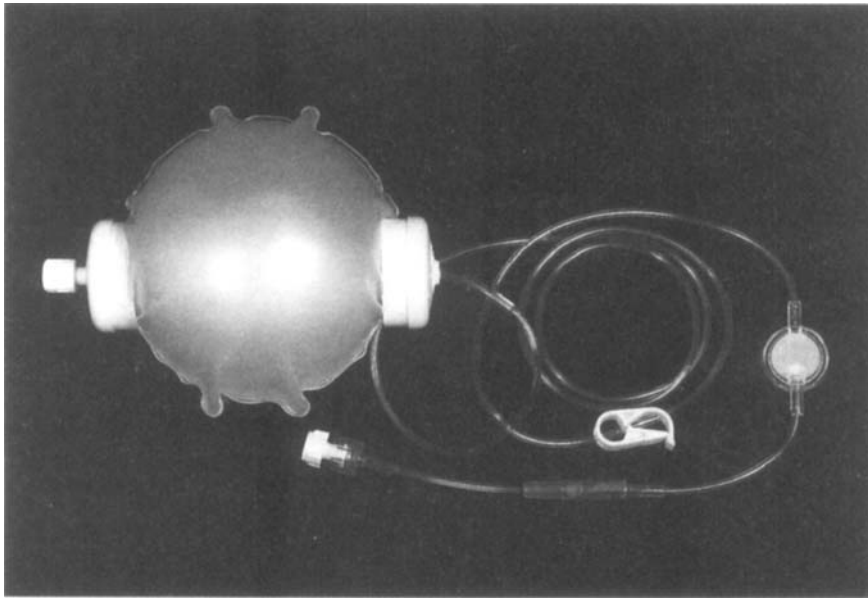


Fig. 1. A 270-ml disposable elastometric infusion pump delivers anesthetic at a fixed rate of 10 ml/h (Homepump; Block Medical, San Diego, CA).

tient's foot continued to remain pain free and "numb" until 28 h after the infusion had been started (32 h after his initial block), when the block gradually regressed. His pain was controlled with oral acetaminophen and oxycodone.

Case 2

A 58-yr-old woman, classified as ASA physical status III, was scheduled for a revision ankle fusion. Her past medical history was significant for hypertension, asthmatic bronchitis, rheumatoid arthritis, and a hiatus hernia with reflux. Her daily oral medications included 7.5 mg methotrexate and 20 mg omeprazole once a day and 200 mg sulindac twice a day. She had no known drug allergies. Physical examination revealed an obese woman in no apparent distress, with weight, 96 kg; height, 165 cm; pulse, 85 beats/min; blood pressure, 160/85 mmHg; respirations, 16 breaths/min. An examination of her extremities revealed multiple rheumatoid nodules. Other results of the examination and laboratory investigations were unremarkable.

The patient was brought to the preoperative holding area, where the anesthetic plan was discussed and agreed to. Routine, noninvasive monitors were applied and oxygen was administered by face mask. Using the same technique and agents described for patient 1, a continuous sciatic nerve block using the popliteal fossa approach was performed. To supplement anesthesia in the saphenous nerve distribution, a trans-sartorius saphenous nerve block was performed using 10 mg ropivacaine, 0.5%, with 1:400,000 epinephrine. To provide sedation for the prolonged surgical case (6 h), a general anesthetic was also performed. In addition to a balanced anesthetic technique, the patient received a total of 350 μ g fentanyl for preoperative and intraoperative narcosis.

At the conclusion of the procedure, the patient emerged from anesthesia without complication. She was pain free in the postanesthesia care unit and was admitted to the ambulatory surgery center recovery unit for a planned overnight observation. She also received a 270-ml disposable elastometric infusion pump (Homepump, Block

Medical) that was connected 7 h after the initial block was established. The pump contained 0.2% ropivacaine and had a nonadjustable infusion rate of 10 ml/h. The patient was pain free throughout the night. Pain first developed in the saphenous nerve distribution 23 h after the initial trans-sartorius saphenous nerve block. She was given 350 mg acetaminophen and 5 mg oxycodone, and the trans-sartorius saphenous nerve block was repeated using the same technique and local anesthetic. At this time, the infusion pump was refilled with local anesthetic and the patient was discharged home with instructions. Her ankle and foot remained analgesic and "numb" for an additional 27 h. Her block regressed during the next day, nearly 50 h after her initial neural blockade. During that time she required only eight narcotic tablets for breakthrough pain.

Discussion

Continuous regional anesthesia with a peripheral nerve catheter can provide excellent postoperative anesthesia. Rawal *et al.*⁷ recently reported on continuous axillary nerve sheath catheters and local wound infiltration with bolus dosing of local anesthetic with similarly encouraging results. However, using a continuous sciatic catheter with a disposable infusion pump in patients having ambulatory surgery has not been reported. By administering local anesthetic directly near the sciatic nerve, prolonged analgesia was achieved for extensive lower extremity orthopedic surgery, which would otherwise have required intravenous narcotics and prolonged hospital admission. The typical intravenous narcotic requirements for other patients who had similar procedures at our institution are more than 330 mg morphine sulfate during 3 days (unpublished data).

CASE REPORTS

The technique provided analgesia that lasted between 27 and 50 h. This duration is nearly two to four times as long as that provided by single-injection blocks. In these cases, analgesic duration was limited to the capacity of the infusion pump (270 ml), which was designed to deliver a fixed rate of 10 ml/h for 27 h. A 500-ml capacity infusion pump is being developed and might be used to increase the length of analgesia.

Ropivacaine, 0.2%, was chosen as the local anesthetic infusion because of our group's previous experience and familiarity with the drug when used with other continuous catheters. In addition, ropivacaine may offer other theoretical advantages compared with other long-acting amide local anesthetics. For example, an improved safety profile and sensory-motor differential blockade may be advantageous in the outpatient setting.

Frequently, labor-intensive anesthetic techniques do not gain acceptance because they require operating room time. At our institution, we try to avoid this by using a monitored preoperative holding area. This environment enables our staff to perform techniques in a safe, well-equipped area. In fact, when nongeneral anesthetic techniques are used, this setup is used to obviate induction and emergence time and to contribute to an efficiently run operating room.

In each case, patients reported pain around the medial aspect of their ankles approximately 24 h after the initial neural blockade. This area was in the distribution of the saphenous nerve and was limited in duration because of the single-injection technique used for lumbar plexus. The need to block both the lumbar plexus and the sacral plexus illustrates one of the limitations of continuous catheters used for lower extremity surgery.

Both patients readily accepted the technique and agreed to remove the catheters themselves. Because patients were discharged with the catheter and disposable pump, patient cooperation, reliability, and participation were essential. In addition to our standard instructions about protecting an anesthetized extremity, the patients and their families were instructed about the signs and symptoms of local anesthetic toxicity. They were specifically told to clamp the pump tubing and contact their physician if they noticed numb lips, a metallic taste, ringing in the ears, or anxiety and tremulousness. Each patient was given access to a physician to contact with any questions or concerns. Given the high degree of success and prolonged analgesia afforded with this technique, a randomized study comparing this continuous outpatient regional anesthesia with conventional choices is suggested.

References

1. Smith B, Fisher H, Scott P: Continuous sciatic nerve block. *Anesthesia* 1984; 39:155-7
2. Selander D: Catheter technique in axillary plexus block. *Acta Anaesth Scand* 1977; 21:324-9
3. Chayen D, Nathan H, Chayen M: The psoas compartment block. *ANESTHESIOLOGY* 1976; 45:95-9
4. Singelyn F, Aye F, Gouverneur J: Continuous popliteal sciatic nerve block: An original technique of postoperative analgesia after foot surgery. *Reg Anesth* 1995; 20:59
5. Brown DL: *Atlas of Regional Anesthesia*. Philadelphia, WB Saunders, 1992
6. Steele S, Klein S, D'Ercole F, Greengrass R, Gleason D: A new continuous catheter delivery system. *Anesth Analg* 1998; 86:228
7. Rawal N, Axelsson K, Hylander J: Postoperative patient-controlled local anesthetic administration at home. *Anesth Analg* 1998; 86:86-9