

CASE REPORTS

Anesthesiology
1999; 91:571-3
© 1999 American Society of Anesthesiologists, Inc.
Lippincott Williams & Wilkins, Inc.

The Use of Side-stream Spirometry To Assess Air Leak during and after Lung Volume Reduction Surgery

Richard J. S. Robinson, M.B., B.Ch., F.R.C.P.C.*

GAS leak from surrounding bullous lung tissue occurs in 46–53% of patients after lung volume reduction surgery.^{1,2} Sudden rupture of the lung occurs in another 13% of patients after operation.¹ Intensive care ventilators and various in-line side-stream spirometers can monitor lung mechanics in patients receiving ventilatory support.³ This report shows how these monitors can be used in the operating room and in the postoperative period to measure the volume of gas leaking from the lungs.

Case 1

A 66-yr-old man with severe emphysema underwent lung volume reduction surgery of the apex of his right lung using left-sided, one-lung ventilation with a left-sided endobronchial, double-lumen tube and a video-assisted thorascopic approach. He was ventilated with a Drager Narcomed ventilator (North American Drager, Telford PA) with an inspiratory fraction of oxygen of 1.0. The procedure lasted 95 min. Fifteen to twenty percent of his right lung was stapled using a linear stapler loaded with bovine pericardial strips. After gradual reinflation of the collapsed lung, the flow volume loop of a side-stream spirometer (Capnomac Ultima TM Datex-Ohmeda, Tewksbury, MA) showed the characteristic pattern of a large gas leak (fig. 1A), with early closure of the expiratory curve of the flow volume loop. The inspired tidal volume ($V_{T\text{insp}}$) was 594 ml and the expired tidal volume ($V_{T\text{exp}}$) was 359 ml; that is, 235 ml or 39% of the $V_{T\text{insp}}$ was lost with each breath. One-lung ventilation was reinstated for a further 55 min. There was a tear in a bulla close to the previous staple line. Further bullous lung was then excised, and talcum powder was instilled into the pleural cavity to cause pleurodesis. With positive-pressure ventilation and gentle reinflation of the right lung, the side-stream spirometer showed nearly complete closing of the flow volume loop, with only a minimal

(36 ml) gas leak recorded (fig. 1B). The patient's postoperative care was complicated by bronchospasm and a persistent leak from the right lung. He was discharged home 21 days after operation.

Case 1

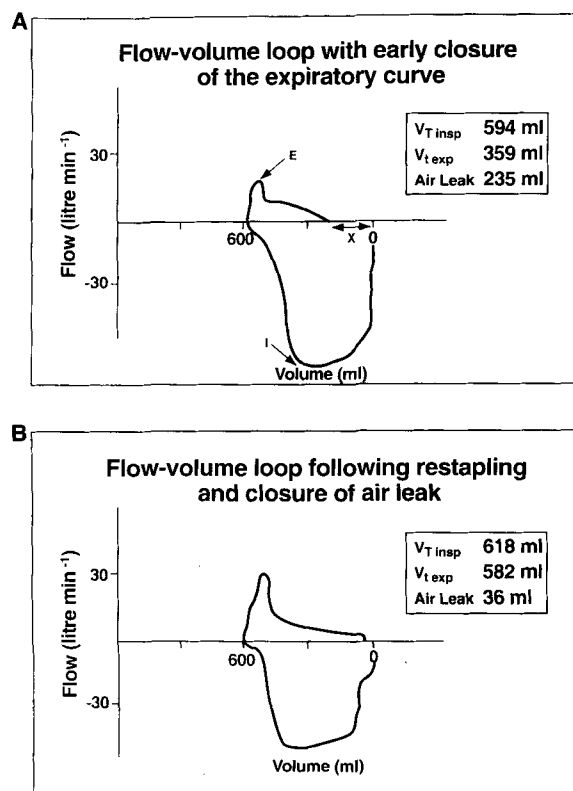


Fig. 1. (A) A flow volume loop shows characteristics of a gas leak immediately after lung reduction surgery. (B) A flow volume loop after subsequent closure of the leak. Characteristics include higher peak inspiratory flow rate (I), lower peak expiratory flow rate (E), and early closure of the expiratory curve. Volume x represents the volume of gas lost through the lung tear with each breath. $V_{T\text{insp}}$ = inspired tidal volume, $V_{T\text{exp}}$ = expired tidal volume.

* Associate Professor.

Received from the Department of Anesthesiology, McGill University and The McGill University Health Centre, Montreal, Canada. Submitted for publication July 27, 1998. Accepted for publication December 29, 1998. Support was provided solely from institutional and/or departmental sources.

Address reprint requests to Dr. Robinson: The Montreal General Hospital, 1650 Cedar Avenue, Montreal, Quebec, Canada H3G 1A4.

Key words: Spirometry; thoracic surgery.

Case 2

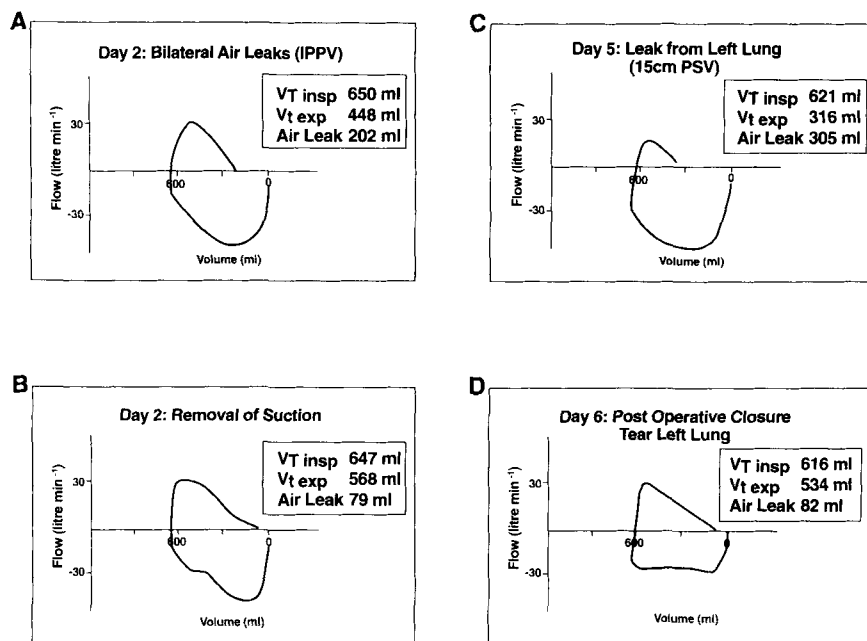


Fig. 2. Flow volume loops show (A) early closure of the expiratory curve in a patient with air leaking from both lungs after surgery; (B) air leak reduced when chest suction was removed, (C) a persistent and increasing leak from the patient's left lung; and (D) a flow volume loop after surgical closure of a tear in the left lung. V_{Tinsp} = inspired tidal volume, V_{Texp} = expired tidal volume.

Case 2

A 72-yr-old man with severe bullous emphysema underwent bilateral apical lung volume reduction surgery. On the first postoperative day, his lungs were ventilated with a Puritan Bennet 7200 series ventilator (Carlsbad, CA). His pulse oximetry was 85–88% (partial pressure of arterial oxygen, 51–62 mmHg) when his lungs were ventilated at a rate of 14 breaths/min with a tidal volume (V_T) of 700 ml (inspiratory fraction of oxygen = 0.6–0.8). He had bilateral air leaks and subcutaneous emphysema. His chest radiograph showed incomplete reexpansion of his right lung, which was treated with increasing chest suction to -20 cm water. For 2 days, using controlled ventilation, the patient continued to maintain a partial pressure of arterial oxygen of 50–60 mmHg. His pulse oximetry was 70–93% (inspiratory fraction of oxygen = 0.6–0.8), and he needed cardiac support with norepinephrine and dopamine to increase his venous oxygen saturation (cardiac output, 3.7–5.2 l/min; venous oxygen saturation, 52–69%). Bilateral gas leaks persisted. The flow volume loop of a side-stream spirometer (fig. 2A) showed early closing of the expiratory flow volume loop. The V_{Tinsp} measured 650 ml and the V_{Texp} was 448 ml (gas leak of 202 ml/ breath or 31% of V_{Tinsp}). When chest suction to the right pleura was removed⁴ (fig. 2B), leak from the lungs was reduced to 79 ml/breath after 8 h. However, the next day there was an increasing gas leak, mainly from the left lung, of 228 ml/breath. On postoperative day 3, the patient's lungs were ventilated with 15 cm pressure support, and 10 cm positive end-expiratory pressure, which was needed for him to trigger the respirator. The patient tolerated pressure support ventilation well, was relatively comfortable, and communicated by writing. His pulse oximetry was 87–92% (inspiratory fraction of oxygen = 0.6). Inotropic support was discontinued. Gas leak from the right chest tube stopped within the next 2 days. However, the left chest tube continued to bubble vigorously and the side-stream spirometer showed an increasing leak from the left lung of 305 ml/breath (fig. 2C). Despite reduction

of pressure support to 12 cm water (positive end-expiratory pressure = 7.5 cm), there was no reduction in the size of the left-sided leak when measured with the spirometer, and 6 days after operation the surgeon closed a large rent of a bulla in the left lung. After operation (pressure support = 18 cm, positive end-expiratory pressure = 10 cm water), gas leak was only 82 ml (fig. 2D). Unfortunately, low pressure pulmonary edema of the left lung developed with marked arterial desaturation, and the patient died 9 days after operation.

Discussion

Continuous side-stream spirometry is used to measure lung mechanics during thoracic surgery. Reduced lung compliance secondary to one-lung ventilation, pulmonary edema,⁵ or malposition of the double-lumen endobronchial tube⁶ is reflected by rightward and downward shifts of the pressure-volume loop. Continuous display of the flow volume loop measures reduction of expired tidal volume with decreases in lung compliance with the onset of one-lung ventilation, and with increased distension of the anesthesia circuit at higher inspiratory airway pressures. Changes in the expiratory flow rate depend on expiratory airway resistance,^{7–9} and the anesthesiologist can monitor the expiratory curve of the flow volume loop to allow a sufficient expiratory time to avoid gas trapping when ventilating lungs of patients with severe obstructive lung disease.¹⁰ The flow volume loop of a patient with severe obstructive lung disease is re-

CASE REPORTS

flected by the illustrated loop (case 1, fig. 1B). The characteristic "scooped out" appearance of the latter part of the expiratory curve is caused by reduced expiratory flow rates secondary to effort-independent airway closure, bronchospasm, or both.

These two case reports illustrate the use of continuous monitoring of flow volume loops to detect and quantify air leaks during and after lung volume reduction surgery. After reinflation of the collapsed lung, detection of a gas leak by side-stream spirometry is a more precise method than flooding the operative field with saline and then inflating (or hyperinflating) the lung to detect air bubbles leaking from the lung. Furthermore, side-stream spirometry detects a gas leak before chest closure. After operation, although gas leaking from the lungs can be detected from inspection of the draining chest tubes, visual inspection does not give a quantitative measurement of the leak per breath. When a gas leak occurs, ventilation through a low-resistance alveolar tear results in a higher peak inspiratory flow rate. Loss of inspired tidal volume through a tear in the lung means that the lungs are not so inflated at end inspiration. At lower volumes, elastic and chest wall recoil are reduced in expiration, and the spirometer will show a lower peak expiratory flow rate. When gas is lost through the ruptured lung, the expired tidal volume is less than the inspired tidal volume, and early closure of the expiratory limb of the flow volume loop occurs. The difference between V_{Tinsp} and V_{Texp} quantifies the volume of gas lost per breath and is reflected on the x axis of the flow volume loop as the volume measured between zero and the point where the expiratory flow volume curve intersects the baseline.

Postoperative gas leak after lung volume reduction

surgery results in prolonged hospital stays and probably causes an increased hospital morbidity rate, although no studies have confirmed this. The routine use of side-stream spirometry to measure the volume of intraoperative or postoperative gas leak may be helpful in determining the best method to manage such a leak.

References

1. Date H, Goto K, Souda R, Nagashima H, Togami I, Endau S, Aoe M, Yamashita M, Andou A, Shinizu N: Bilateral lung volume reduction surgery via median sternotomy for severe pulmonary emphysema. *Ann Thorac Surg* 1998; 65:939-42
2. Bousamra M, Haaster GB, Lipchik RJ, Henry D, Chammes JH, Rokkes CK, Menard-Rothe K, Sobush DC, Olinger GN: Functional and oximetric assessment of patients after lung reduction surgery. *J Thorac Cardiovasc Surg* 1997; 113:675-82
3. Merilainen P, Hanninen H, Tuomaal L: A novel sensor for routine continuous spirometry of intubated patients. *J Clin Monit* 1993; 9:374-80
4. Cooper JD, Patterson GA: Lung volume reduction surgery for severe emphysema. *Semin Thorac Cardiovasc Surg* 1996; 8:52-6
5. Bardoczky GI, Defranguen P, Engelman E, Capello M: Continuous monitoring of pulmonary mechanics with the side stream spirometer during lung transplantation. *J Cardiothorac Vasc Anesth* 1992; 6:731-4
6. Bardoczky GI, Levarlet M, Engelman E, Defrancquen P: Continuous spirometry for detection of double lumen endobronchial tube placement. *Br J Anaesth* 1993; 70:499-502
7. Mead J: Analysis of the configuration of maximum expiratory flow-volume curves. *J Appl Physiol* 1978; 44:156-65
8. Carilli AD, Denson LJ, Rock F, Malabanan S: The flow volume loop in normal subjects and in diffuse lung disease. *Chest* 1974; 66(5) 472-7
9. Hyatt RF, Black LF: The flow-volume curve. A current perspective. *Am Rev Resp Dis* 1973; 107:191-9
10. Bardoczky GI, d'Hollander A: Continuous monitoring of the flow volume loops and compliance during anaesthesia. *J Clin Monit* 1992; 76:862-3