

■ CORRESPONDENCE

Anesthesiology
1999; 91:578-9
© 1999 American Society of Anesthesiologists, Inc.
Lippincott Williams & Wilkins, Inc.

In Situ Pulmonary Thrombolysis Using Recombinant Tissue Plasminogen Activator after Cesarean Delivery

To the Editor:—We read with interest the case report by Nishimura *et al.*¹ with regard to bleeding. We successfully gave lower doses of recombinant tissue plasminogen activator (rt-PA) *via* a pulmonary artery catheter for thrombolysis in a 20-yr-old woman 2 days after a cesarean section. She was referred to us after an urgent cesarean delivery at 34 weeks' gestation because of a suspected pulmonary embolism with concomitant fetal distress. Pulmonary embolism was suspected because of the sudden occurrence of consciousness troubles (confusion and disorientation), dyspnea, cyanosis, hypotension, and tachycardia combined with a swollen left leg with a decreased venous blood flow shown on Doppler echography. She was treated prophylactically with subcutaneous low molecular weight heparin for 1 week. Heparin (5,000 units bolus and 1,000 units/h) was administered, but collapse and hypoxia persisted throughout the cesarean section despite the administration of fluids (2,500 ml) and mechanical ventilation with 100% oxygen. When she was admitted to our intensive care unit, the patient's systolic blood pressure varied from 50-100 mmHg, and hypoxia persisted (blood gas analysis with 100% oxygen; partial pres-

sure of arterial oxygen, 66 mmHg; and arterial oxygen saturation, 89%). The patient had a sinus tachycardia with incomplete right bundle branch block shown on an electrocardiograph, and decreased vascular marks were evident over the right lung on a chest radiograph. Blood tests showed lactic acidosis (pH 7.23, lactic acid, 6 mmol/L), anemia (9 g/dl), and thrombopenia (87,000/mm³). Pulmonary and radial artery catheters were placed for hemodynamic monitoring. Cardiac output, mean blood pressure, and mean pulmonary artery pressure were 3 l · min⁻¹ · m², 48 mmHg, and 33 mmHg, respectively. The pulmonary artery wedge pressure could never be measured. Echocardiography showed a strongly dilated and hypokinetic right ventricle, with bulging of the interventricular septum into the left ventricle. Epinephrine and heparin administration and ventilation with a positive end-expiratory

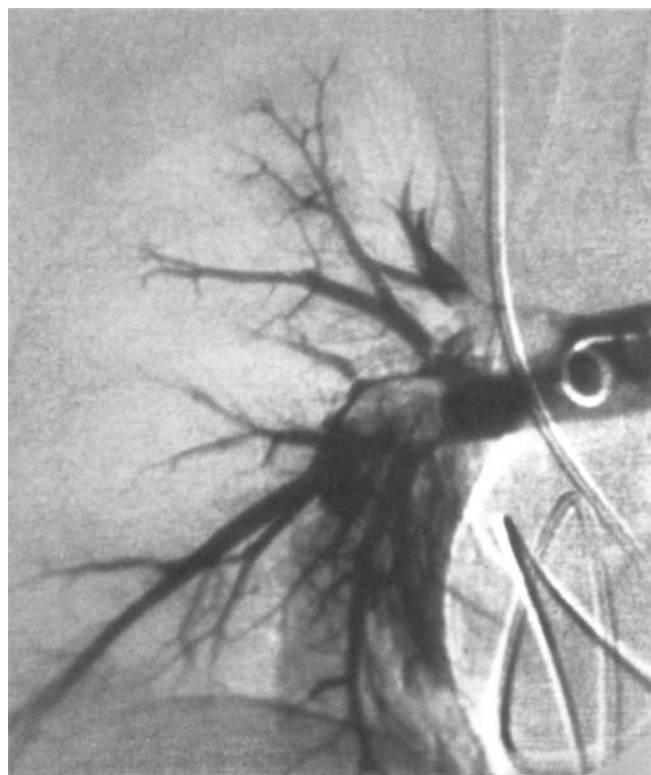


Fig. 1. Angiography of the right pulmonary artery shows intraluminal proximal and distal thrombi suppressing the perfusion of the superior and the median lobes of the right lung.

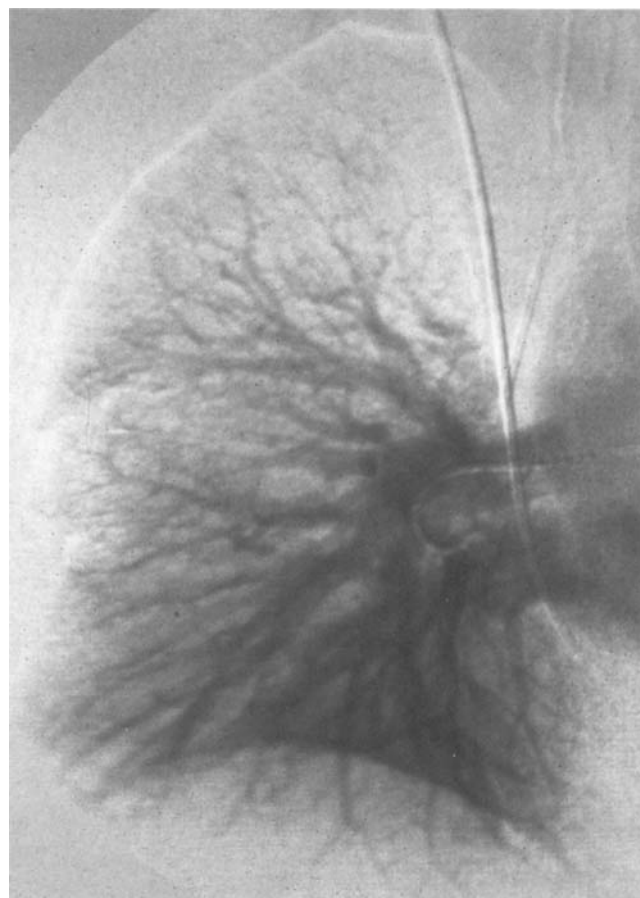


Fig. 2. Angiography of the right pulmonary artery 48 h after thrombolysis. The thrombi disappeared and the superior and median lobes of the right lung are reperfused.

CORRESPONDENCE

pressure (14 cm water) improved the patient's hemodynamic status (blood pressure, 140/90 mmHg; urine output, $>0.5 \text{ ml} \cdot \text{kg}^{-1} \cdot \text{h}^{-1}$; lactic acid, $<2 \text{ mmol/l}$; partial pressure of arterial oxygen, 135 mmHg with 80% oxygen), allowing further investigation. Pulmonary angiography confirmed the pulmonary embolism (fig. 1), and venocavography showed a compression on the left iliac vein (Cockett syndrome). Because of hemodynamic instability during the following 2 days, 60 mg rt-PA was administered over 6 h *in situ via* the pulmonary artery catheter but stopped at a cumulative dose of 57 mg because of bleeding on vascular puncture sites. No bleeding occurred from the wound or the uterus. Nevertheless, we obtained satisfactory hemodynamics and oxygenation and could reduce the epinephrine dosage, the fraction of inspired oxygen, and the positive end-expiratory pressure (partial pressure of arterial oxygen, 130 mmHg; arterial oxygen saturation, 98% with 40% oxygen; and positive end-expiratory pressure, 8 cm water). The cardiac output increased ($7 \text{ l} \cdot \text{min}^{-1} \cdot \text{m}^2$), and the pulmonary arterial pressure decreased (23 mmHg). Two days later, a second angiography confirmed the lung reperfusion (fig. 2). Epinephrine was discontinued 3 days later. The patient left the hospital on day 27 of admission with instructions to take an oral anticoagulant therapy.

Although we used low doses, our case and others^{2,3} illustrate the reduced bleeding complications associated with the perioperative use of rt-PA. However, the intraoperative use and the underlying coagulopathy may have increased the risk of bleeding in the case by Nishimura *et al.*¹

Anesthesiology

1999; 91:579

© 1999 American Society of Anesthesiologists, Inc.

Lippincott Williams & Wilkins, Inc.

In Reply:—We are grateful for the opportunity to respond to the thoughtful comments by Drs. Aya, Saissi, and Eledjam. The case they describe and the one we reported previously¹ may indicate that rt-PA can be used to treat life-threatening pulmonary embolism during and after cesarean section. We administered the dose of rt-PA as reported before in Japan, which was less than the doses reported in the United States or Europe. Because 10 mg rt-PA is equivalent to 5,800,000 units, we believe that the dose we used was not greater than that administered in the case reported by Aya *et al.* However, massive hemorrhage occurred in our case. It is imperative to try to reduce the dose of rt-PA in the future. Because we were resuscitating the patient and had no time to place the pulmonary artery catheter, rt-PA was administered *via* a right internal jugular vein in our case. But as Aya *et al.* demonstrated, when rt-PA was administered *via* the pulmonary artery catheter, the dose of rt-PA could be reduced. In the presence of severe complications, a further survey of the proper dose of rt-PA would be indicated.

Antoine G. M. Aya, M.D., M.Sc.

Gilbert Saissi, M.D.

Staff Anesthesiologists

Jean-Jacques Eledjam, M.D.

Professor and Chairman,

Anesthesiology and Critical Care

Department of Anesthesiology and Intensive Care Medicine

University Hospital

Nîmes, France

References

1. Nishimura K, Kawaguchi M, Shimokawa M, Kitaguchi K, Furuya H: Treatment of pulmonary embolism during cesarean section with recombinant tissue plasminogen activator. *ANESTHESIOLOGY* 1998; 89: 1027-8
2. Baudo F, Caimi TM, Redaelli R, Nosari AM, Mauri M, Leonardi G, de Cataldo F: Emergency treatment with recombinant tissue plasminogen activator of pulmonary embolism in a pregnant woman with antithrombin III deficiency. *Am J Obstet Gynecol* 1990; 163:1274-5
3. Mitchell JP, Trulock EP: Tissue plasminogen activator for pulmonary embolism during shock: Two case reports and discussion of the literature. *Am J Med* 1991; 90:255-60

(Accepted for publication December 31, 1998.)

Kenji Nishimura, M.D.

Visiting Researcher

Masahiko Kawaguchi, M.D.

Staff Anesthesiologist

Hitoshi Furuya, M.D.

Professor and Chairman

Department of Anesthesiology

Nara Medical University

Nara, Japan

Reference

1. Nishimura K, Kawaguchi M, Shimokawa M, Kitaguchi K, Furuya H: Treatment of pulmonary embolism during cesarean section with recombinant tissue plasminogen activator. *ANESTHESIOLOGY* 1998; 89: 1027-8

(Accepted for publication February 5, 1999.)