

■ CASE REPORTS

Anesthesiology
1999; 91:867-9
© 1999 American Society of Anesthesiologists, Inc.
Lippincott Williams & Wilkins, Inc.

Postpartum Subdural Hygroma after Epidural Analgesia

Maria Teresa Verdú, M.D.,* Benjamin Alonso, M.D.,† Sebastian Burguillos, M.D.,‡ Juan F. Martínez-Lage, M.D.§

THE formation of cranial subdural hematomas after lumbar puncture is a well-known complication of spinal anesthesia, although rare in young patients.¹⁻³ Pathogenesis of this condition has been related to rupture of bridging veins joining the cerebral surface and the dura mater. The precipitating event in these cases is the continuous leakage of cerebrospinal fluid through the dural hole. More unusual is the production of subdural hygromas in the intracranial cavity, which has not yet been described. Our aim is to describe the occurrence of a subdural hygromas complicating inadvertent lumbar puncture and to discuss the problems encountered in their diagnosis and management.

Case Report

A 26-yr-old nulliparous woman presented in active labor. She had a history of migraine, but was otherwise healthy. She requested epidural analgesia. The anesthesiologist identified the L2-L3 interspace and attempted to place a catheter using an 18-gauge Tuohy needle. During placement, an accidental dural puncture was noted, and the needle was withdrawn. A subsequent puncture was performed at the L3-L4 and the epidural catheter was successfully inserted. The labor elapsed uneventfully.

Six hours after delivery, the patient began to complain of an intense, throbbing, occipital headache that worsened when she was in the upright position. There was neither neck stiffness nor fever. A tentative diagnosis of postdural puncture headache was made. Treatment consisted of bed rest, hydration, and analgesics.^{4,5} At this time, the patient refused a recommended epidural blood patch and, after a 3-day hospital stay, was discharged home.

* Attending Anesthesiologist.

† Chief of Unit.

‡ Resident in Anesthesiology.

§ Chief of Unit, Regional Service of Neurosurgery.

Received from the Department of Anesthesiology, "Virgen de la Arrixaca" University Hospital, Murcia, Spain. Submitted for publication November 13, 1998. Accepted for publication February 26, 1999. Support was provided solely from institutional and/or departmental sources.

Address reprint requests to Dr. Verdú: c/o San Nicolás 13, 4c, E-30005 Murcia, Spain. Address electronic mail to: javerdu@cajamurcia.es

Key words: Complications; epidural blood patch; magnetic resonance imaging; postdural puncture headache; subdural hygroma.

Fifteen days later, the patient returned to the hospital complaining of continued severe headaches. She did not describe diplopia, tinnitus, or vomiting. Except for mild neck rigidity, her neurologic examination was normal and there was no papilloedema. The patient was again offered an epidural blood patch, which she accepted. During aseptic conditions, an epidural injection of 7 ml autologous blood was performed over 1 min. After an overnight stay at the hospital, the patient became symptom free and was discharged home.

The patient was readmitted 12 days later because her headache had returned to its original intensity after a 4-day period of pain relief. She denied being confused, experiencing vomiting, or having other neurologic symptoms. Cranial computed tomography was performed, which

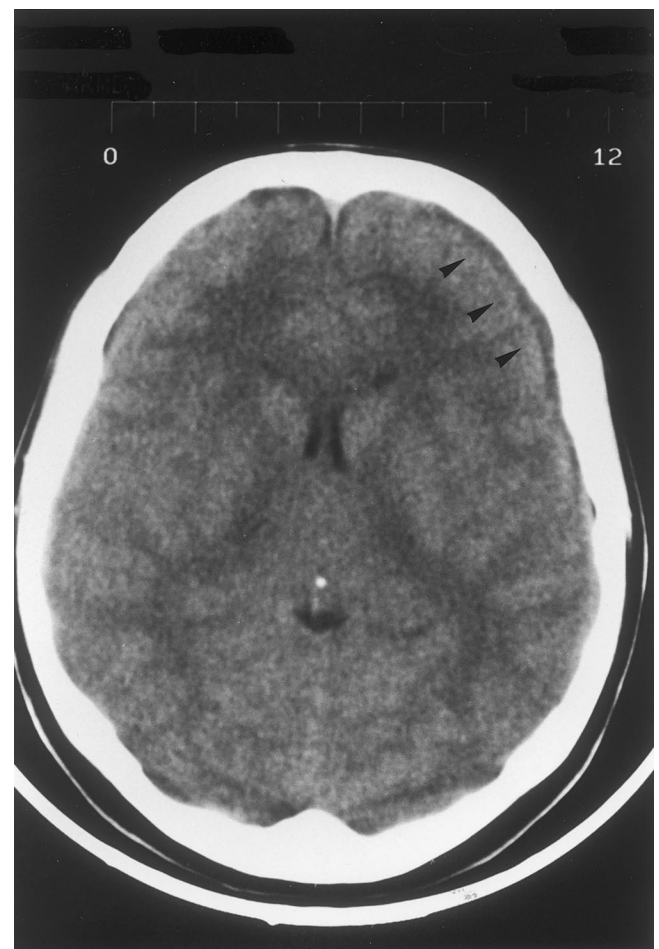


Fig. 1. Cranial computed tomography showing frontoparietal hygroma (black arrowheads).

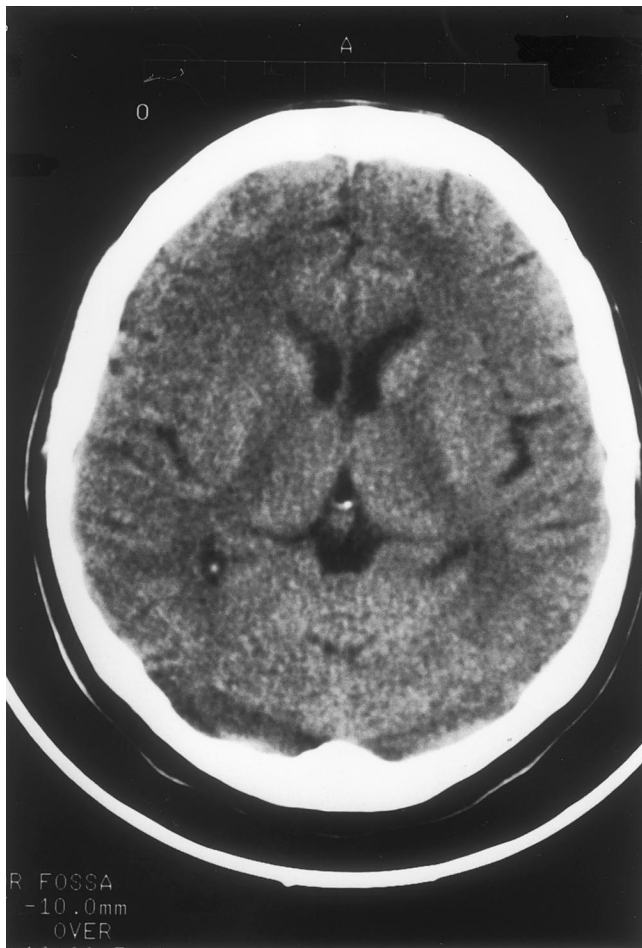


Fig. 2. Cranial computed tomography showing complete resolution of subdural collections.

showed bilateral frontoparietal subdural hygromas, with gyral effacement and small ventricles (fig. 1). The patient was also studied using magnetic resonance imaging venography of the brain that ruled out thrombosis of the cerebral venous sinuses.⁶ Gadolinium-enhanced and -unenhanced magnetic resonance imaging of the lumbosacral spine was also obtained,⁷ which failed to show dural enhancement, subdural collections of fluid, or the site of the cerebrospinal fluid fistula.^{8,9}

A subsequent epidural blood patch was performed using 14 ml autologous blood, and adequate intravenous hydration and analgesia were administered. After this management regime, the patient's headaches decreased in severity and were controlled with the intake of mild oral analgesics. The patient was discharged from the hospital 11 days later (on day 39 postpartum). Two weeks after the second epidural blood patch, the patient was symptom free and subsequent cranial computed tomography showed complete resolution of the subdural collections (fig. 2).

Discussion

The occurrence of subdural hygromas after epidural procedures may be more common than has been recog-

nized previously. Subdural hygromas are most often the result of traumatic events, particularly head trauma. The mechanism involved is probably the continuous leakage of cerebrospinal fluid through the orifice made in the dura mater at the time of the lumbar puncture.^{10,11} If the brain shrinks because of brain atrophy, excessive dehydration, or decreased intracranial pressure, a subdural collection may develop by a passive effusion of fluid. Most subdural hygromas from other causes resolve when the brain is well-expanded. However, some instances of hygromas may evolve to chronic subdural hematomas if the conditions leading to their formation persist over several weeks.¹⁰

The diagnosis of subdural hygroma can be difficult on a clinical basis alone, especially if an obvious cerebrospinal fluid leak is not reported. We performed a review of the literature in regard to subdural hygromas associated with postdural puncture headache and have not found any previous references to this condition. We suggest that the existence of a subdural hygroma should be included in the differential diagnosis of the cause of a persistent headache presenting after a dural puncture, especially if first steps of management have already failed.

References

1. Macon ME, Armstrong L, Brown EM: Subdural hematoma following spinal anesthesia. *ANESTHESIOLOGY* 1990; 72(2):380-1
2. Diemunsch P, Balabaud BP, Petiau C, Marescaux C, Muller A, Valfrey J, Treisser A: Bilateral subdural hematoma following epidural anesthesia. *Can J Anaesth*, 1998; 45(4):328-31
3. Vos PE, de Boer WA, Wurzer JA, van Gijn J: Subdural hematoma after lumbar puncture: Two cases reports and review of the literature. *Clin Neurol Neurosurg* 1991; 93(2):127-32
4. Christopher W, Berger CW, Crosby ET, Wlodzimienz G: North American survey of the management of dural puncture occurring during labour epidural analgesia. *Can J Anaesth* 1998; 4: 110-4
5. Sajjad T, Ryan TDR: Current management of inadvertent dural taps occurring during the setting of epidurals for pain relief in labour. A survey of maternity units in the United Kingdom. *Anaesthesia* 1995; 50:156-61
6. Starley E, Borum, Naul G, Charles H, Mcleskey: Postpartum dural venous sinus thrombosis after postdural puncture headache and epidural blood patch. *ANESTHESIOLOGY* 1997; 86:487-90
7. Shermeen B, Vakharia SB, Thomas PS, Rosenbaum AE, Wasenko JJ, Fellows DG: Magnetic Resonance imaging of cerebrospinal fluid leak and tamponade effect of blood patch in postdural puncture headache. *Anesth Analg* 1997; 84:585-90
8. Moayeri NN, Henson JW, Schaefer PW, Zervas NT: Spinal dural enhancement on magnetic resonance imaging associated

CASE REPORTS

with spontaneous intracranial hypotension. *J Neurosurg* 1998; 88: 912-8

9. Gordon RE, Moser FG, Pressman BD, Young W: Resolution of pachymeningeal enhancement following dural puncture and blood patch. *Neuroradiology* 1995; 37:557-8

10. Lee KS: The pathogenesis and clinical significance of traumatic subdural hygroma. *Brain Inj* 1998; 12:595-603

11. Born JD, Hans P, Flandroy P, Milbouw G, Bonnal J: Incidence and treatment of subdural hygroma in severe head injuries. *Acta Neurol Belg* 1984; 84:174-82

Anesthesiology
1999; 91:869-72
© 1999 American Society of Anesthesiologists, Inc.
Lippincott Williams & Wilkins, Inc.

Preoperative Use of Enoxaparin and Tirofiban: Possible Association with Increased Bleeding Postbypass

Nikolaos J. Skubas, M.D.,* George J. Despotis, M.D.,† Jon J. Vlasnic, Pharm.D.,‡ Marc R. Moon, M.D.§

THE purpose of this case report is to alert anesthesiologists and other medical and surgical staff as to the potential for increased postoperative bleeding in patients undergoing heart surgery after having received the recently introduced low-molecular-weight heparin (LMWH) preparations (e.g., enoxaparin) and new platelet inhibitors (e.g., tirofiban) in the setting of acute coronary syndromes or coronary interventional procedures.

Case Report

Four days after acute anterolateral myocardial infarction, a 75-yr-old, 56-kg man was scheduled for coronary arterial revascularization. His preoperative medications were 60 mg enoxaparin subcutaneously two

times a day, aspirin and metoprolol orally, and intravenous infusion of the platelet glycoprotein (GP) IIb/IIIa receptor inhibitor tirofiban (Ag-grastat, Merck, West Point, PA). The tirofiban infusion was discontinued at midnight before the day of operation.

Normal electrolyte and hematologic panels were obtained preoperatively: prothrombin and activated partial thromboplastin times (aPTT) of 13.9 (1.1 × control, international standardized index [ISI] 2) and 34.9 s (1.1 × control), respectively, a hematocrit of 48.1%, and a platelet count of 152,000/μl. Creatinine and blood urea nitrogen levels were normal as well (1.2 mg/dl and 10 mg/dl, respectively). During 90 min of extracorporeal support, with an ischemic time of 51 min, the surgical procedure involved anastomosis of the left internal thoracic artery to the left anterior descending coronary artery and a free reversed saphenous vein graft to the left circumflex coronary artery. During cardiopulmonary bypass (CPB), the triggers for additional heparin administration were an activated clotting time of less than 480 s and a whole blood heparin concentration less than the patients' pre-CPB reference level (4.2 U/ml) using an automated protamine titration method (Hepcon, Medtronic Blood Management, Parker, CO). After discontinuation of CPB, the total dose (23,000 IU) of heparin was neutralized with a total of 350 mg protamine sulphate, as guided by the automated protamine titration method. Nevertheless, the surgical wound appeared diffusely "wet," and the subjective diagnosis of microvascular bleeding was made by the staff surgeon. Based on immediately available whole blood tests, which revealed a normal activated clotting time (> 120 s); no detectable heparin (automated protamine titration heparin concentration method); a hematocrit of 22%; a platelet count of 55,000/μl; and a whole blood prothrombin/PTT of 17.8 s (1.48 × control, ISI 2)/40.9 s (1.32 × control), respectively; 2 U of packed erythrocytes and one single donor pack (apheresis) of platelets were transfused. The patient remained normothermic (36.9°C) after discontinuation of bypass. While in the cardiothoracic intensive care unit, routine hematologic assays (prothrombin/aPTT, hematocrit, and platelet count) were performed to guide transfusion therapy in the setting of excessive chest tube drainage (CTD; fig. 1) During the first 8 h, one six-pack of random donor platelets was administered for excessive bleeding (CTD: 960 ml) in the presence of a platelet count of 64,000/μl. During the next 8-h period, 4 U fresh frozen plasma were given for ongoing bleeding (CTD: 740 ml) in the setting of prothrom-

* Assistant Professor, Department of Anesthesiology, Washington University School of Medicine.

† Associate Professor, Department of Anesthesiology and Pathology, Washington University School of Medicine.

‡ Clinical Pharmacist, Department of Pharmacy, Barnes-Jewish Hospital.

§ Assistant Professor, Department of Surgery, Washington University School of Medicine.

Received from the Departments of Anesthesiology, Pathology, and Surgery, Washington University School of Medicine, and Barnes-Jewish Hospital, Washington University Medical Center, Saint Louis, Missouri. Submitted for publication December 1, 1998. Accepted for publication April 12, 1999. Support was provided solely from institutional and/or departmental sources.

Address reprint requests to Dr. Skubas: Department of Anesthesiology, 660 South Euclid Avenue, Box 8054, Saint Louis, Missouri 63110. Address electronic mail to: skubasn@notes.wustl.edu

Key words: Complications; low-molecular-weight heparin; platelet GP IIb/IIIa inhibitor.

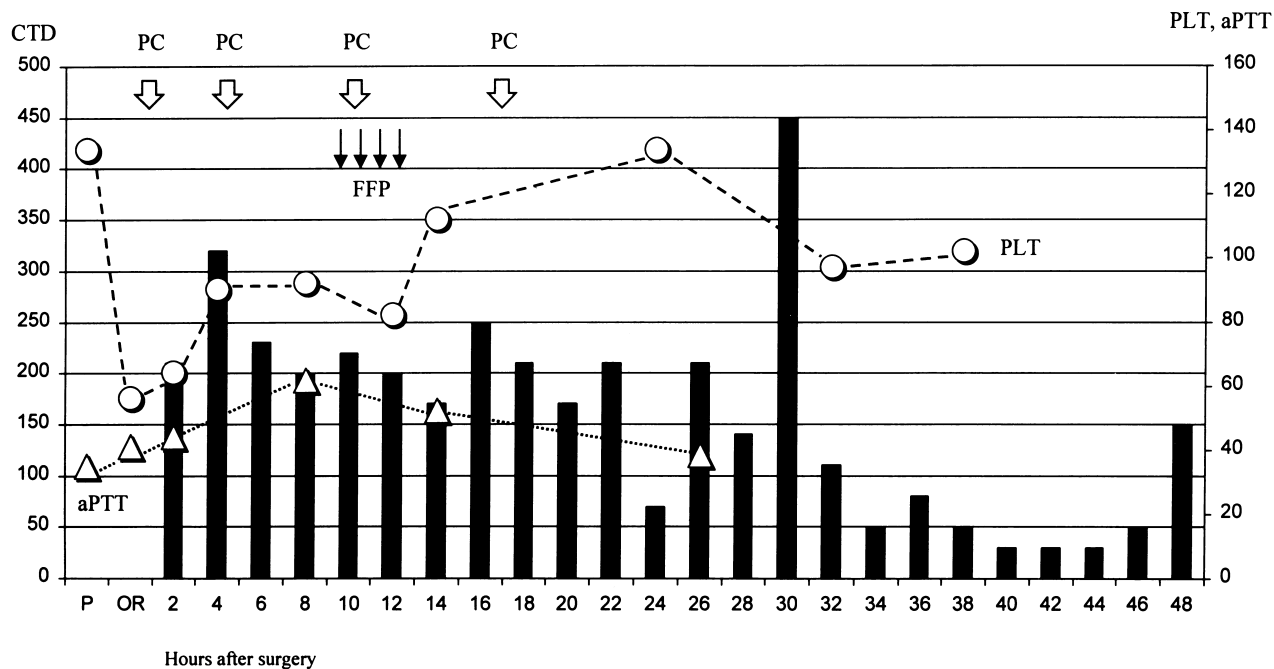


Fig. 1. Graphic description of the relation between chest tube drainage (milliliters), displayed as bars; platelet count ($\times 1,000/\mu\text{l}$), displayed as circles; activated partial thromboplastin time (seconds), displayed as triangles; and administration of hemostatic blood products: platelet concentrates (*white arrows*) and fresh frozen plasma (*thin black arrows*) perioperatively. P = preoperatively; OR = intraoperatively.

bin/aPTT values of 15.2 s ($1.2 \times$ control)/61.7 s ($1.9 \times$ control), as well as a single donor apheresis platelet unit (six-pack equivalent) for a platelet count of $82,000/\mu\text{l}$. Persistent excessive CTD (660 ml) during the third 8-h period necessitated the administration of an additional six-pack of random donor platelets. Despite excessive CTD (3,750 ml over 2 days), necessitating the transfusion of 7 U erythrocytes, the patient was hemodynamically stable, did not require vasopressor therapy, and was extubated the morning after surgery (15 h postoperatively). No additional hematologic assays were performed. Neither thromboelastography nor anti-Xa assay are available in our institution, and a point-of-care platelet function test, although available, was not performed by the managing physicians, who were not aware of the potential for excessive postbypass bleeding in the setting of concurrent use of LMWH and tirofiban. The patient was discharged from the intensive care unit 2 days later and from the hospital after 5 days.

Discussion

Based on results of the ESSENCE trial,¹ the combination of LMWH and aspirin is increasingly being used for patients with acute coronary syndromes. LMWHs, such as enoxaparin, are derived from unfractionated heparin (UFH) and produce their major anticoagulant effect by accelerating the binding of antithrombin III (AT III) to predominantly factor Xa (enoxaparin has an anti-Xa:anti-IIa activity ratio of 3.8:1.0).² LMWHs generally have

enhanced bioavailability, a longer half-life (two to four times as long as that of UFH), a dose-independent renal clearance, and a slightly decreased incidence of heparin-induced thrombocytopenia.³ LMWHs exhibit an anti-thrombotic effect that is assessed most accurately by measuring anti-Xa activity (which is often unavailable). The inability of routine doses of protamine to completely reverse the anti-Xa activity represents a significant limitation.² In an animal study, the dose of protamine sulfate necessary to fully minimize bleeding was 10-fold greater for LMWH than for UFH.⁴ In addition, excessive CTD was observed,^{5,6} when enoxaparin was used as an alternative to UFH in patients with heparin-induced thrombocytopenia undergoing CPB.

Platelet aggregation has been implicated as one of the major causes in the development of unstable angina and acute myocardial infarction. Activation of the platelet IIb/IIIa GP receptor represents a crucial step in platelet aggregation, and 80–100% blockade of this receptor should completely suppress platelet aggregation. Therefore, potent platelet inhibitors, such as the intravenous GP IIb/IIIa inhibitors have been developed, and their clinical effectiveness is supported by several studies.⁷

Recent data showed that substantially increased blood

CASE REPORTS

usage was associated with use of the GP IIb/IIIa inhibitor abciximab, especially if surgery was performed within 24 h after receiving the medication.⁸ However, these findings have not been universal.⁹ Platelet transfusions, which will reduce the drug's receptor occupancy on platelet surfaces to less than the critical 50% threshold associated with prolongation of the bleeding time,¹⁰ is the most appropriate therapy.

Although postbypass bleeding can have a multifactorial cause, several important factors, such as prolonged duration of CPB and type of procedure, are associated with transfusion of hemostatic blood products and increased CTD.¹¹ The postoperative CTD of our patient, 2,360 ml over the first 24 h and 1,380 during the second 24 h, far exceeded the previously reported mean 24-h cumulative chest tube output of 986 ± 581 ml.¹¹ In the case presented, the CPB duration was rather short, bleeding from the two distal anastomoses should have been easily detected, and normothermia was maintained after CPB. The role of tirofiban with respect to excessive bleeding is uncertain based on its short half-life time of about 90 min,¹² and the infusion was discontinued the night before. Use of this agent may be important because the patient also received enoxaparin on the day of the surgery. The peak anti-Xa activity after subcutaneous LMWH administration occurs within 3–4 h, and the anti-Xa levels are approximately 50% of peak levels 12 h later.¹³

When patients who are receiving a LMWH preparation are scheduled to undergo a surgical procedure, such as coronary revascularization, it would be prudent to discontinue the LMWH at least 24 h before surgery or to replace the LMWH with an intravenous infusion of UFH. This approach may be even more important in the setting of concurrent administration of a potent platelet inhibitor, such as tirofiban. In the setting of concurrent use of LMWH and platelet inhibitors, routine coagulation results (prothrombin, aPTT, activated clotting time, platelet count) will most likely not be helpful in guiding appropriate therapy. Further studies are needed to evaluate the relation between concomitant use of these new antithrombotic agents and perioperative bleeding, as well as the use of new monitoring systems and heparin reversal agents. Future advances in coagulation monitoring may help in the evaluation of patients with residual anti-Xa activity, such as the HepTest anti-Xa (Haemachem, St. Louis, MO), a test that directly measures the inhibition of factors Xa and IIa.¹⁴ Point-of-care tests of platelet function, such as platelet activating factor-mediated acceleration of coagulation (hemoSTATUS¹⁵;

Medtronic Blood Management, Parker, CO), thromboelastography (Haemoscope, Skokie, IL),¹⁶ agglutination of fibrinogen-coated beads (Ultegra; Accumetrics, San Diego, CA), and platelet-force development (Hemodyne, Richmond, VA), may facilitate evaluation of the degree of residual platelet inhibition as well as the degree of CPB-related platelet dysfunction. Novel reversal agents, such as the [+18RGD] protamine variant, which reverses conventional UFH and enoxaparin, may be clinically useful in reversing the anticoagulant effects of LMWH.¹⁷

References

1. Cohen M, Demers C, Gurfinkel EP, Turpie AGG, Fromell GJ, Goodman S, Langer A, Califf RM, Fox KAA, Premmereur J, Bigonzi F: A comparison of low-molecular-weight heparin with unfractionated heparin for unstable coronary disease. *N Engl J Med* 1997; 337:447–52
2. Weitz JI: Low-molecular-weight-heparins. *N Engl J Med* 1997; 337:688–98
3. Warkentin TE, Levine MN, Hirsh J, Horsewood P, Roberts RS, Gent M, Kelton JG: Heparin-induced thrombocytopenia in patients treated with low-molecular-weight heparin or unfractionated heparin. *N Engl J Med* 1995; 332:1330–5
4. Van Ryn-McKenna JV, Cai L, Ofusu FA, Hirsh J, Buchanan MR: Neutralization of enoxaparin-induced bleeding by protamine sulfate. *Thromb Haemost* 1990; 63:271–4
5. Ganjoo AK, Harloff MG, Johnson WD: Cardiopulmonary bypass for heparin-induced thrombocytopenia: Management with a heparin-bonded circuit and enoxaparin. *J Thorac Cardiovasc Surg* 1996; 112:1390–2
6. Robitaille D, Leclerc JR, Laberg R, Sahab P, Atkinson S, Cartier R: Cardiopulmonary bypass with a low-molecular-weight heparin fraction (enoxaparin) in a patient with a history of heparin-induced thrombocytopenia. *J Thorac Cardiovasc Surg* 1992; 103:597–8
7. Braunwald E, Maserit A, Armstrong PW, Califf RM, Gibler WB, Hamm CW, Simmons ML, Van de Werf F: Rationale and clinical evidence for the use of GP IIb/IIIa inhibitors in acute coronary syndromes. *Eur Heart J* 1998; 19:(suppl D):D22–30
8. Bracey A, Radovancevic R, Vaughn W, Ferguson J, Livesay J: Blood use in emergency coronary artery bypass after receipt of abciximab during angioplasty (abstract). *Transfusion* 1998; 38:S250
9. Booth JE, Patel VB, Balog C, Miller DP, Juran NB, LeNarz L, Lincoff AM: Is bleeding risk increased in patients undergoing urgent coronary bypass surgery following abciximab? (abstract). *Circulation* 1998; 98:1-845
10. Ferguson JJ, Kereiakes DJ, Adgey AAJ, Fox KAA, Hillegass WB, Pfisterer M, Vassanelli C: Safe use of platelet GP IIb/IIIa inhibitors. *Eur Heart J* 1998; 19:(suppl D):D40–51
11. Despotis GJ, Filos KS, Zoys TN, Hogue CW, Spitznagel E, Lappas DG: Factors associated with excessive postoperative blood loss and hemostatic transfusion requirements: A multivariate analysis in cardiac surgical patients. *Anesth Analg* 1996; 82:13–21
12. Barrett JS, Murphy G, Peerlinck K, De Lapeleire I, Gould RJ, Panebianco D, Hand E, Deckmyn H, Vermynen J: Pharmacokinetics and pharmacodynamics of MK-383, a selective non-peptide platelet glyco-

protein-IIb-IIIa receptor antagonist, in healthy men. *Clin Pharm Ther* 1994; 56:377-88

13. Hirsh J, Levine MN: Low molecular weight heparin: Laboratory properties and clinical evaluation. *Eur J Surg* 1994; 571(suppl):9-22

14. Yin E: Appraisal of clot-based and amidolytic anti-Xa methods for the monitoring of heparin and its derivatives. *Sem Thromb Hemostas* 1985; 11:243-4

15. Despotis GJ, Ikonomakou S, Levine V, Joiner-Maier D, Santoro SA, Joist JH: Effects of platelets and white blood cells and antiplatelet

agent c7E3 (Reopro[®]) on a new test of PAF procoagulant activity of whole blood. *Thromb Res* 1997; 86:205-19

16. Greilich PE, Alving BM, O'Neill KL, Chang AS, Reid TJ: A modified thromboelastographic method for monitoring c7E3 Fab in heparinized patients. *Anesth Analg* 1997; 84:31-8

17. Wakefield TW, Andrews PC, Wroblewski SK, Kadell AM, Tejwani S, Hulin MS, Stanley JC: A [+18RGD] protamine variant for nontoxic and effective reversal of conventional heparin and low-molecular-weight heparin anticoagulation. *J Surg Res* 1996; 63:280-6

Anesthesiology

1999; 91:872-3

© 1999 American Society of Anesthesiologists, Inc.

Lippincott Williams & Wilkins, Inc.

Unanticipated Difficult Intubation as a Result of an Asymptomatic Vallecular Cyst

Vaibhav A. Kamble, M.D.,* Richard B. Lilly, M.D.,† Jeffrey B. Gross, M.D.‡

ALTHOUGH vallecular cysts are often asymptomatic and harmless to the patient, discovery of a large vallecular cyst after induction of anesthesia is a potentially life-threatening problem for the patient and provides for the anesthesiologist a challenge in airway management. This report describes the treatment of a patient with an asymptomatic vallecular cyst that was discovered during rapid-sequence induction of general anesthesia.

Case Report

A 47-year-old woman presented for elective right knee arthroscopy and removal of painful orthopedic hardware of the lower extremity. Her medical problems included obesity and a history suggestive of gastroesophageal reflux disease and hypertension treated with enalapril. She had no known drug allergies. A year previously she received general anesthesia *via* a size 4 laryngeal mask airway for knee arthro-

scopy. She admitted to a 25-pack-year history of smoking but denied symptoms of shortness of breath or cough. Physical examination revealed an obese woman (height 172 cm, weight 110 kg) who appeared older than her stated age. She was edentulous and had normal mouth opening and neck extension; no masses or distortion of the tongue or neck were observed. Chest auscultation revealed a mild expiratory wheeze.

She was premedicated with 10 mg metoclopramide intravenously and 30 ml sodium citrate orally. After application of routine monitoring devices, she was preoxygenated. Anesthesia and paralysis were induced with 200 mg propofol and 120 mg succinylcholine while cricoid pressure was applied. Direct laryngoscopy with a Macintosh 3 blade revealed a 2-cm cyst arising from the right side of the vallecula; it was pedunculated with a 5-mm stalk, making it somewhat mobile. The cyst completely obscured the view of the epiglottis and larynx, preventing intubation despite multiple attempts by two anesthesiologists using Macintosh 3 and Miller 2 blades, and increased neck extension and thyroid pressure. Because of a decrease in oxygen saturation (SaO₂) the patient was ventilated *via* mask as cricoid pressure was maintained. Despite insertion of an oropharyngeal airway, this proved to be difficult; laryngospasm began to develop as muscle relaxation waned. After a second 80-mg dose of succinylcholine, intubation was attempted using a Miller 2 laryngoscope blade and a styletted 7.0-mm endotracheal tube. By using the tube to push the cyst aside, intubation of the trachea was performed after a brief although limited view of the laryngeal inlet.

The remainder of the anesthetic proceeded uneventfully. While the patient remained anesthetized, an otolaryngologist was consulted and the cyst was surgically removed. Dexamethasone 10 mg was given as suggested by the otolaryngologist. Anesthesia was discontinued and 100% oxygen was administered; after the patient awakened, the pharynx was carefully suctioned and the trachea was extubated.

Her postoperative course was also uneventful and she was discharged to home on the same day without any airway-related problems apart from a sore throat. During further questioning in the postan-

* Resident in Anesthesiology.

† Chairman, Department of Anesthesiology.

‡ Professor of Anesthesiology and Pharmacology.

Received from the Department of Anesthesiology, University of Connecticut School of Medicine, Farmington, Connecticut. Submitted for publication December 21, 1998. Accepted for publication April 12, 1999. Support was provided solely from institutional and/or departmental sources.

Address reprint requests to Dr. Lilly: Department of Anesthesiology, University of Connecticut School of Medicine, Farmington, Connecticut 06030-2015. Address electronic mail to: Lilly@up.uchc.edu

Key words: Airway; epiglottis; larynx; unexpected.

CASE REPORTS

thetia care unit she admitted to a several-year history of dysphagia. The pathology report confirmed the findings of a $2.2 \times 2.2 \times 0.5$ cm, 0.3-cm thick membranous wall vallecular cyst.

Discussion

Cysts of the larynx are rare and usually follow a benign course. They can, however, present with acute airway obstruction by nature of their location. Laryngeal cysts have been previously reported in the anesthesia literature.¹⁻⁴ However, this case presented the additional challenge of producing unanticipated upper airway obstruction during rapid-sequence induction general anesthesia with subsequent successful intubation of the trachea by manipulation of the cyst with a styletted endotracheal tube.

Laryngeal cysts have been extensively studied and classified by site, size, contents, and relation to the laryngeal mucosa. Ductal cysts or mucous retention cysts are the most common type of laryngeal cysts, comprising 75% of cases, and are formed by distention of obstructed collective glandular ducts. (Saccular cysts, which comprise the remaining 25%, arise from the saccule, an extension of the ventricle; they may cause respiratory symptoms by enlarging the aryepiglottic fold).^{5,6} Ductal cysts are usually small, approximately 1-5 mm in diameter and as such are often asymptomatic.⁵ They are usually only discovered incidentally at the time of routine otolaryngologic examination or at postmortem examination.^{1,7} As a result, the exact incidence of laryngeal cysts is unknown but is estimated to be quite low.⁸ There is no gender predominance and, although they may occur at any age, a greater prevalence in the fifth and sixth decades has been observed.^{5,6} The most common location of ductal cysts is on the true vocal cords, whereas the second most common site is in the vicinity of the epiglottis—on its lingual surface or in the vallecula itself.⁵⁻⁷ Although they are usually asymptomatic, they may occasionally cause symptoms of stridor and failure to thrive (particularly in the newborn),⁸⁻¹⁰ cough, dysphonia, foreign body sensation and dysphagia.⁶

In our case, a previously undiagnosed vallecular cyst presented as a difficult intubation. We had no reason to suspect any difficulties with intubation because the patient had no symptoms preoperatively—the patient's history of dysphagia was only elicited on specific, symptom-directed questioning postoperatively. In view of her normal airway examination, previous uneventful general

anesthesia and history of gastroesophageal reflux disease, we thought that rapid-sequence induction of anesthesia and tracheal intubation was appropriate for our patient. Had both tracheal intubation and mask ventilation been impossible, aspiration of the cyst *via* a spinal needle might have been an option. In contrast to previous case reports in which intubation was either abandoned or performed blindly with the aid of a gum elastic bougie,¹⁻⁴ we were able to intubate the trachea by displacing the pedunculated vallecular cyst with the endotracheal tube. We elected to obtain an otolaryngology consultation while the patient was still anesthetized so the cyst could be removed before extubation. This avoided the risk of any airway obstruction after extubation caused by the potential "ball-valve" effect of the cyst. This case would certainly have been managed differently had we known that the cyst was present before induction of anesthesia. For example, regional anesthesia or awake fiberoptic intubation would have been reasonable alternatives.

In summary, there are several causes for an unanticipated difficult intubation during rapid-sequence induction of general anesthesia. This case report helps to highlight one such cause—an asymptomatic vallecular cyst—and its subsequent management, resulting in successful tracheal intubation.

References

1. Mason DG, Wark KJ: Unexpected difficult intubation. Asymptomatic epiglottic cysts as a cause of upper airway obstruction during anesthesia. *Anaesthesia* 1987; 42:407-10
2. Millar SW: Unexpected difficult intubation (letter). *Anaesthesia* 1987; 42:1021-2
3. McKiernan EP, Meakin G: Vallecular cysts (letter). *Anaesthesia* 1988; 43:808-9
4. McHugh P: Cyst of epiglottis (letter). *Anaesthesia* 1989; 44:522
5. De Santo L, Devine K, Weiland L: Cysts of the larynx—Classification. *Laryngoscope* 1970; 80:145-76
6. Arens C, Glanz H, Kleinsasser O: Clinical and morphological aspects of laryngeal cysts. *Eur Arch Otorhinolaryng* 1997; 254:430-6
7. Albert DM, Ali Z: Two cases of vallecular cyst presenting with acute stridor. *J Laryngol Otol* 1985; 99:421-5
8. Conway EE, Bye MR, Wirtshafter K, Gereau S, Bassila M: Epiglottic cyst: An unusual cause of stridor in an infant. *Pediatr Emerg Care* 1991; 7:85-6
9. Oluwole M: Congenital vallecular cyst: A cause of failure to thrive. *Br J Clin Prac* 1996; 50:170
10. Myer CM: Vallecular cyst in the newborn. *Ear, Nose, Throat J* 1988; 67:122-4

Anesthesiology
 1999; 91:874-6
 © 1999 American Society of Anesthesiologists, Inc.
 Lippincott Williams & Wilkins, Inc.

Shivering Complicating the Treatment of Neurologically Impaired Surgical and Intensive Care Unit Patients

Mark T. Keegan, M.B., M.R.C.P.I.,* Frank W. Sharbrough, M.D.,† William L. Lanier, M.D.‡

NEW-ONSET rhythmic movement can confound diagnosis and complicate management in patients with central nervous system disease. Rhythmic movement may result from the nonconvulsive effects of drugs (e.g., etomidate), the convulsive effects of drugs (e.g., local and general anesthetics), epileptic seizures, or other causes. Regardless of the source, inadvertent patient motion may complicate awake neurosurgical procedures, especially if the surgery involves real-time assessment of neurologic function or the acquisition of fine electrical recordings.

Because movement disorders may reflect new or evolving brain injury or result from more benign causes, the identification of the source of the movement may lead to widely divergent patient care interventions. We describe two patients who experienced new-onset, nonconvulsive, rhythmic movement that interfered with their treatment. In both, the source of the movement was normothermic or near-normothermic shivering.

Case Reports

Case 1

A 29-yr-old man with a history of aqueductal stenosis was admitted to the neurologic intensive care unit after surgery to remove an in-

fectured right-sided ventriculoperitoneal shunt. Six hours later, generalized tonic-clonic convulsions occurred, and electroencephalography (EEG) confirmed status epilepticus. When initial therapy with diazepam, phenytoin, and phenobarbital failed to control the seizure activity, an amobarbital infusion was begun. The trachea was intubated, and the lungs were mechanically ventilated. Additionally, the patient was treated with 100 mg intravenous phenytoin four times per day.

After 18 h of amobarbital infusion, subsequent EEG was obtained while the patient was without seizures or rhythmical movement. This revealed 0.5-1 Hz δ activity with superimposed rhythmic 10-12 Hz α activity. Also observed were sporadic or quasiperiodic sharp waves arising from the right frontocentral region. These findings were consistent with residual barbiturate effect plus potentially epileptogenic components. The amobarbital infusion rate was reduced to permit further evaluation of the patient's neurologic status. However, over the ensuing 4 h, the patient began experiencing rhythmic movement interpreted as clinical evidence for return of seizures. The amobarbital infusion was returned to the previous delivery rate, and a prolonged EEG recording was begun. The EEG data were consistent with general anesthesia; no seizure activity was observed.

A second attempt to wean the patient 30 h after the original administration of the barbiturate infusion resulted in intense, violent, rhythmic muscle activity, although the patient remained unresponsive to stimuli. The EEG findings were consistent with altered consciousness as a result of residual anesthetic; no clear seizure activity was identified. Instead, EEG tracings contained a rhythmic artifact that was represented in the scalp electrode recordings as 5- to 6-Hz waxing and waning deflections, consistent with a nonepileptic "movement disorder." The patient's core (bladder) temperature was 37.8°C. Based on the available data, a tentative diagnosis of near-normothermic shivering was made.

The patient was stripped of all clothing. The skin was irradiated using two 500 W infrared heat lamps (Emerson Equipment Model 96H; Emerson Electric, St. Louis, MO), with the light source 1 m from the skin surface. Within approximately 90 s, all rhythmic muscle activity ceased. Two minutes later, the light therapy was discontinued, and the rhythmical activity returned. When this sequence was repeated 5 min later with the same results, the diagnosis of near-normothermic shivering was confirmed. Throughout the test, the patient's temperature was unchanged and no antipyretics were administered.

The amobarbital infusion was not reinitiated. Over the next 24 h, the patient awakened from the amobarbital anesthetic without EEG or clinical evidence of seizures. The trachea was extubated 2 days later. During this period, the patient's skin was kept warm by the use of warm blankets, and the rhythmic muscle activity did not return. The patient was discharged from the intensive care unit 1 week after

* Resident, Department of Anesthesiology.

† Emeritus Professor, Department of Neurology (Electroencephalography Laboratory).

‡ Professor, Department of Anesthesiology.

Received from the Departments of Anesthesiology and Neurology, Mayo Clinic and Mayo Medical School, Rochester, Minnesota. Submitted for publication November 30, 1998. Accepted for publication April 19, 1999. Support was provided solely from institutional and/or departmental sources.

Address reprint requests to Dr. Lanier: Department of Anesthesiology, Mayo Clinic, 200 First Street SW, Rochester, Minnesota 55905. Address electronic mail to: lanier.william@mayo.edu

Key words: Convective warming; electroencephalography; hypothermia; movement disorders; neurosurgery; radiant warming; temperature; thermoregulation.

CASE REPORTS

admission. He left the hospital, without evidence of new neurologic deficit, 10 days later.

Case 2

A 67-yr-old man was scheduled for awake mini craniotomy and stereotactic placement of a left thalamic stimulator to treat an essential tremor. After headframe placement and magnetic resonance imaging (MRI), the patient was sedated with 1 mg intravenous midazolam, and the scalp was infiltrated with 8 ml of a mixture of 1% lidocaine and 0.375% bupivacaine local anesthetics. The scalp was incised and surgical probes were inserted through burr holes. Using stereotactic techniques, a recording probe was directed into the brain, and electrophysiologic monitoring and clinical examination were used to identify the location of the thalamic tremor generator. During this activity, crescendo and coarse, rhythmic motor activity involving the entire body developed, without alteration in consciousness. As the movement persisted, the patient became extremely anxious and expressed a strong desire to discontinue the surgery. The possibility of discontinuation of surgery also was expressed by the surgeon and neurologist because the new movement prevented the high-quality electrophysiologic recording necessary for successful completion of the surgery. In addition, there was concern for probe- and pinion-induced bleeding.

An extensive consoling conversation with the patient was initiated and a low-dose propofol infusion was begun (approximately $20 \mu\text{g} \cdot \text{kg}^{-1} \cdot \text{min}^{-1}$). This attenuated, but did not abolish, the anxiety, and the patient's underlying tremor and new-onset movements persisted. Based on these observations, a diagnosis of normothermic shivering was considered.

A convective warming blanket was placed next to the patient's skin, from the chest downward, and this was connected to a forced-air warmer (Bair Hugger Polar Air Model 600; Augustine Medical, Inc., Eden Prairie, MN) set at 43°C . All rhythmic motion (in excess of the patient's baseline hand tremor) ceased within 3 min. Concomitantly, the patient's anxiety level decreased still further. Surgery proceeded uneventfully, and the site for stimulator electrode placement was established. After 5 h of surgery, general anesthesia was induced to allow placement of the stimulator pulse generator. Temperature, as measured by esophageal stethoscope, was 36.0°C at this time, and the temperature remained unchanged at the end of the procedure 90 min later. Activation of the stimulator greatly attenuated the abnormal tremor activity on the right side. The patient was discharged on the first postoperative day.

Five months later, a fractured stimulator wire necessitated repeat surgery. The patient was sedated with an infusion of intravenous propofol at $50 \mu\text{g} \cdot \text{kg}^{-1} \cdot \text{min}^{-1}$, a stereotactic headframe was placed, and computed tomography was performed. No efforts were initiated to keep the patient warm during transportation and scanning. At return to the operating room, a urinary bladder catheter with temperature-sensing capability (Bardex 400-series; CR Bard, Covington, GA) was inserted. The patient's temperature was 35.6°C , with an ambient operating room temperature of 18°C . He complained of feeling cold. On this occasion, in the setting of the background tremor only (*i.e.*, without visible evidence of shivering), the patient also experienced mild anxiety. However, the anxiety was far less than that experienced during the initial surgery. A forced-air warmer (temperature set at 38°C) was used again, and, despite a core temperature that remained at 35.6°C , the patient's anxiety ceased within minutes. Surgery proceeded uneventfully and postoperative recovery was rapid.

Discussion

We describe two patients whose clinical course was complicated by shivering. In the first, the shivering interfered with the clinical and electrophysiologic diagnosis of seizures, thus extending the period in which the patient received an amobarbital anesthetic. In the second, intraoperative shivering again precluded accurate electrophysiologic monitoring and, additionally, increased the risk of bleeding. This patient experienced extreme anxiety associated with the shivering. Had the coupled shivering and anxiety not been treated, it would have been necessary to discontinue the surgery.

In patient 1, we had evidence that the shivering occurred during a period without core hypothermia. (A possible cause is that the hypothalamic "set point" for temperature regulation was increased, perhaps because a fever was developing.¹) In both patients, shivering ceased within minutes after initiating skin warming. Thus, the period of warming, that was sufficient to stop shivering, was insufficient to meaningfully alter core temperature.

Distinguishing between shivering and other forms of rhythmic motor activity can be difficult. One possible approach is to characterize and quantify the frequency of the motor activity and compare it to the reported properties of motor activity in different physiologic states. Electromyographic recordings at frequencies of 5–12 Hz can represent shivering, but there is overlap with a variety of physiologic and pathologic conditions.^{2,3} Although shivering also may exhibit a fairly characteristic 4- to 8-cycles/min waxing and waning pattern,⁴ this was not specifically identified as an artifact within the EEG in the first patient we described.

The effect of barbiturate infusion on the first patient's rhythmic movements was believed to represent evidence for underlying seizure activity. In hindsight, it probably represented the influence of an anesthetic agent on the "interthreshold range"⁵ for thermoregulation (*i.e.*, the 0.2°C range outside of which thermoregulatory mechanisms are initiated). For the same reason, the early use of propofol probably prevented shivering with hypothermia (*i.e.*, bladder temperature 35.6°C) during the second patient's second surgery.⁶ After we suspected a diagnosis of normothermic or near-normothermic shivering in our patients, the treatment was patterned after the reports of Sharkey *et al.*^{7,8} This therapy is based on the principle that reduction in skin temperature, independent of core hypothermia, can initiate shivering. Warming the skin in such patients will

abruptly halt shivering. Sharkey *et al.*⁷ irradiated shivering patients with a warming light. The patients ceased shivering in 61 ± 10 s (mean \pm standard deviation). However, after the warming light irradiation was discontinued, the patients resumed shivering in 43 ± 7 s. We used this principle of skin warming to effectively treat shivering in our patients and, in patient 1, to establish a diagnosis. In patient 2, direct skin irradiation was impossible because of space limitations caused by surgical draping and equipment. Instead, we used a forced-air warming blanket.^{9,10} In our patients, the rapid onset of the warming effect (patients 1 and 2) and the rapid offset (patient 1) were valuable in establishing the origin of the undesired movement.

Patient 2 had bouts of anxiety during both surgeries. In the first, when the patient shivered violently, the anxiety was debilitating. Although not relieved by the conventional approaches of conversation and sedation, the anxiety was halted by skin warming. Although core hypothermia plus input from thermal sensors within the skin may have directly affected the anxiety spells, the experience during the first surgery also suggests a correlation between muscle activity and the anxiety. Surface warming, which rapidly halted the shivering, also abolished the anxiety. These observations suggest that shivering *per se*, perhaps acting through muscle receptors (*e.g.*, muscle spindles), served to modulate the anxiety attack. Such an interpretation is consistent with a large body of experimental evidence that shows that increased muscle afferent traffic (as would be expected during shivering) has the potential to desynchronize the EEG and produce alterations in mentation and behavior in awake and lightly anesthetized subjects.¹¹

In summary, we present two cases in which the presence of shivering confounded the diagnosis and treatment of patients having central nervous system disease. Warming the skin, without altering core temperature, halted the shivering within minutes and, in one patient, also alleviated anxiety. Based on this experience, when

patients are normothermic, we recommend the inclusion of shivering in the differential diagnosis of patients who experience new-onset rhythmic movements. Additionally, our report confirms the effectiveness of using heating lamps or forced-air warmers to prevent, diagnose, and treat shivering.

References

1. Guyton AC, Hall JE: Textbook of Medical Physiology, 9th Edition. Philadelphia, WB Saunders, 1996, pp 911-22
2. Pozos RS, Iaizzo PA: Shivering and pathological and physiological clonic oscillations of the human ankle. *J Appl Physiol* 1991; 71:1929-32
3. Horowitz BA: Homeostatic responses to acute cold exposure: Thermogenic responses in birds and mammals, *Handbook of Physiology: Environmental Physiology*. Edited by Fregly MJ, Blatteis CM. New York, Oxford University Press, 1996, pp 359-77
4. Sessler DI: Temperature monitoring, *Anesthesia*, 4th Edition. Edited by Miller RD. New York, Churchill Livingstone, 1994, pp 1363-82
5. Lopez M, Sessler DI, Walter K, Emerick T, Ozaki M: Rate and gender dependence of the sweating, vasoconstriction, and shivering thresholds in humans. *ANESTHESIOLOGY* 1994; 80:780-8
6. Matsukawa T, Kurz A, Sessler DI, Bjorksten AR, Merrifield B, Cheng C: Propofol linearly reduces the core temperature thresholds for vasoconstriction and shivering thresholds. *ANESTHESIOLOGY* 1995; 82:1169-80
7. Sharkey A, Lipton JM, Murphy MT, Giesecke AH: Inhibition of postanesthetic shivering with radiant heat. *ANESTHESIOLOGY* 1987; 66:249-52
8. Sharkey A, Gulden RH, Lipton JM, Giesecke AH: Effect of radiant heat on the metabolic cost of postoperative shivering. *Br J Anaesth* 1993; 70:449-50
9. Lennon RL, Hosking MP, Conover MA, Perkins WJ: Evaluation of a forced-air system for warming hypothermic postoperative patients. *Anesth Analg* 1990; 70:424-7
10. Cheng C, Matsukawa T, Sessler DI, Ozaki M, Kurz A, Merrifield B, Lin H, Olofsson P: Increasing mean skin temperature linearly reduces the core-temperature thresholds for vasoconstriction and shivering in humans. *ANESTHESIOLOGY* 1995; 82:1160-8
11. Lanier WL, Iaizzo PA, Milde JH, Sharbrough FW: Cerebral and systemic effects of movement in response to a noxious stimulus in lightly anesthetized dogs. Possible modulation of cerebral function by muscle afferents. *ANESTHESIOLOGY* 1994; 80:392-401

CASE REPORTS

Anesthesiology
1999; 91:877-9
© 1999 American Society of Anesthesiologists, Inc.
Lippincott Williams & Wilkins, Inc.

Management of Post-thoracotomy Pseudoangina and Myofascial Pain with Botulinum Toxin

James H. Diaz, M.D., Dr.P.H.,* Harry J. Gould III, M.D., Ph.D.†

LEFT brachial plexus injury and musculoskeletal pain have been reported after left internal mammary (LIMA) harvesting for left anterior descending coronary artery bypass grafting.¹ Prolonged elevation and retraction of the left hemithorax with the Favoloro sternal retractor during LIMA harvesting has been implicated as a cause of left upper extremity peripheral neuropathy from brachial plexus stretch injury and postoperative musculoskeletal pain from rib fracture, intercostal muscle disruption, and costotransverse and costosternal cartilage separations.² We report a case of factitious pseudoangina from prolonged postoperative musculoskeletal pain treated as angina pectoris with nitrates and anticoagulants after LIMA harvesting for left anterior descending coronary artery bypass grafting (table 1).

Case Report

A 52-yr-old man with a 70% stenosis of the left main coronary artery underwent a single coronary artery bypass graft with a LIMA graft to the proximal left anterior descending coronary artery in 1988 at age 42. The coronary artery bypass graft was performed during balanced narcotic and inhalational anesthesia through a median sternotomy incision with the patient in the supine position with both arms adducted. Invasive vascular monitoring included a right radial artery catheter and

a central venous catheter inserted *via* the right internal jugular vein. The LIMA was harvested over 25 min with exposure provided by a Favoloro retractor. The LIMA-to-left anterior descending anastomosis was conducted during 25 min of complete cardiopulmonary bypass and circulatory arrest. The immediate postoperative course was uneventful, and the patient was discharged on the sixth postoperative day. The patient was readmitted for a 24-h hospital stay 2 days after discharge for tube thoracostomy drainage of a spontaneous left pneumothorax.

One week after the second hospital discharge, the patient first noted left anterior chest wall pain during movement of the left arm with radiation to the left side of the neck, the left shoulder, and left-sided scapula. The pain was dysesthetic, nonlancinating, and pressing, and was initiated by exercise of the left arm, particularly lifting and carrying light items, such as books or a briefcase. The pain was relieved only by resting the left arm. Exercise electrocardiography showed no evidence of cardiac ischemia or myocardial infarction. Cardiac angiography showed no significant additional coronary artery disease or LIMA graft stenosis or occlusion. Cardiac ejection fraction and myocardial performance were assessed as normal, and oral analgesics for prolonged postoperative incisional pain were prescribed.

Between 1988 and 1997, the patient consulted innumerable specialists, including cardiovascular surgeons, physiatrists, cardiologists, and rheumatologists, and underwent five additional coronary arteriograms to assess "recurrent angina." The patient was treated for presumed costochondritis with oral analgesics, nonsteroidal antiinflammatory agents, muscle relaxants, and trigger-point injections in the back. The patient also was prescribed long-term aspirin prophylaxis for coronary artery disease and lovastatin for hypercholesterolemia, and encouraged to take sublingual nitroglycerin for exertional "anginal", *i.e.*, left chest wall and upper arm pain and muscle spasm. The patient continued to exercise despite attacks of left-sided chest wall pain, participated in several marathon runs over the years, but gave up golf and weightlifting because of severe pain and spasms in the left pectoralis major muscle precipitated by movement and weight-bearing exercise of the left upper extremity.

The patient was ultimately referred to the Louisiana State University Medical Center Multidisciplinary Pain Mastery Center for evaluation in November 1997, and, at physical examination, was found to have a 5-cm circumferential area of dysesthesia, muscular irritability, and spasm overlying the left-sided first and second parasternal intercostal spaces. The remainder of the physical examination, particularly the neuromuscular examination of the left upper extremity, was within normal limits. A magnetic resonance imaging study of the thorax in January 1998 showed no evidence of costochondritis, costochondral, or costotransverse junction separation or dislocation; rib fracture, callus, or pseudoarthrosis; sternal or xiphisternal abscess; pseudoar-

* Professor of Anesthesiology and Public Health and Preventive Medicine, Departments of Anesthesiology and Public Health and Preventive Medicine.

† Associate Professor of Neurology, Department of Neurology.

Received from the the Louisiana State University Medical Center Multidisciplinary Pain Mastery Center, New Orleans, Louisiana. Submitted for publication January 29, 1999. Accepted for publication April 26, 1999. Support was provided solely from institutional and/or departmental sources.

Address reprint requests to Dr. Diaz: Department of Public Health and Preventive Medicine, Louisiana State University School of Medicine, 1600 Canal Street, Suite 800, New Orleans, Louisiana 70112. Address electronic mail to: jdiaz@lsu.edu

Key words: Anesthesia; cardiac; cardiac surgery; complications; pain; postoperative.

CASE REPORTS

Table 1. Chronology and Outcomes of Treatments

Date	Treatment or Procedure	Pain Type and Outcome
1988	Open heart bypass surgery	Cardiac angina relieved; pseudoangina began; function restricted
1988–1997	Oral nitrates	Pseudoangina unrelieved; function restricted
November 1997	Thoracic MRI scan	Pseudoangina redefined as myofascial pain
January 1998	Initial botulinum toxin (BoTox) injection	Myofascial pain relieved; nighttime breakthrough pain only; full function resumed
July 1998–Present	Subsequent BoTox injection (July 1998); oral adjuvant therapy with venlafaxine and methocarbamol	Myofascial pain relieved; nighttime breakthrough pain relieved; full function continued

throsis; or dehiscence. The mediastinum, hemidiaphragms, lungs, and hemithoraces were consistent with poststernotomy and otherwise normal. The hemidiaphragms were symmetrically shaped and positioned bilaterally, and there was no radiographic evidence of phrenic neuropathy. Phrenic nerve conduction studies were not indicated.

The patient received an intramuscular injection of 50 U botulinum A toxin suspended in 10 ml bupivacaine, 0.25%, into the dysesthetic trigger point described in the left pectoralis major muscle in January 1998, with dramatic reduction of symptoms. Supplemental therapy for breakthrough pain was initiated at the same time with 75 mg oral venlafaxine and 500 mg oral methocarbamol, both taken at bedtime. The patient remains on a regimen of semiannual intramuscular trigger-point injections with 50 U botulinum toxin supplemented orally with night-time venlafaxine, a selective norepinephrine-reuptake-inhibiting antidepressant with analgesic properties, and methocarbamol, a skeletal muscle relaxant. The patient continues to participate in jogging marathons and has restarted a weekly golf game.

Discussion

Brachial plexus and musculoskeletal injuries of the chest wall and upper extremities have been reported after cardiac surgery, with incidences ranging from 2% to 38%.² Brachial plexus injuries have been associated with the median sternotomy technique, paramedian sternotomy, forced or prolonged sternal retraction with the Favoloro retractor, penetrating trauma from first-rib fractures, hyperabducted arm positioning, and needle trauma during insertion of internal jugular catheters.³ Musculoskeletal injuries have also been associated with rib fractures from forced sternal retraction, costochondral cartilage separations, and costotransverse rib disarticulations.^{1–3} In a prospective investigation of 162 patients undergoing median sternotomy for cardiac surgery, Roy *et al.*¹ reported a significantly greater incidence (39%) of musculoskeletal complaints and neurologic dysfunction in patients undergoing internal mammary artery grafts for aortocoronary bypasses than in patients (17%) undergoing valvular and other cardiac operations without internal mammary artery graft harvesting.

Neurologic dysfunction from brachial plexus and peripheral nerve injuries after cardiac surgery often present with neuropathic pain and dermatomal sensorimotor disturbances that require diagnostic confirmation with nerve conduction studies and electromyography.² Musculoskeletal complaints after cardiac surgery were described by Roy *et al.*¹ as pain at rest and exercise and limitation of motion in the arms, shoulders, chest, and back. Postoperative musculoskeletal complaints were difficult to describe clinically and confirm radiographically in the absence of old fractures, cartilaginous separations, and rib disarticulations.¹ Using either chest wall computed tomography or exploratory resternotomy, Shafir *et al.*³ identified inadvertent paramedian sternotomy as a cause of postoperative musculoskeletal pain, chronic thoracic fistulas, sternal osteomyelitis, and sternal dehiscence in 11 of 55 patients undergoing cardiac surgery. Shafir *et al.*³ recommended that when a painful paramedian sternotomy is diagnosed radiographically or surgically at resternotomy, sternectomy and myocutaneous flap wound closures be performed rather than simple sternal reclosures.

We reported a case of chronic myofascial pain in the left upper thorax and arm repeatedly misdiagnosed as angina pectoris and coronary artery spasm despite normal coronary angiography and left ventricular wall motion and ejection fraction (table 1). Although the patient requested sternal reexploration to assess faulty sternotomy, magnetic resonance imaging of the chest wall, mediastinum, and thorax was initially recommended to rule out sternal fistula, sternal osteomyelitis, occult sternal dehiscence, costochondral cartilage separations, old rib fractures or pseudoarthroses, costotransverse rib disarticulations, and pleuropericardial defects or hernias. Chest magnetic resonance imaging was selected over chest radionuclide scanning, a better imaging technique to detect chronic infection and deep abscesses, for its superior soft tissue and bone density delineation and

CASE REPORTS

because the erythrocyte sedimentation rate, differential count, and serum protein electrophoresis did not suggest chronic infection from osteomyelitis or fistula. In addition, chest magnetic resonance imaging ruled out chronic atelectasis and pleurisy from phrenic neuropathy as an unusual cause of postoperative chest pain.⁴ Although common after open heart surgery, with incidences ranging from 10% to 73%, phrenic neuropathy from topical cardioplegia is usually short-lived and painless and causes elevation and abnormal motion of the hemidiaphragms and persistent ipsilateral atelectasis.⁴

Physical examination of the patient was consistent with a tight and painful myofascial band in the pectoralis major muscle, with irritation and fasciculation during percussion and radiation to the uppermost clavicular portion of the muscle and left upper arm.⁵ The pectoralis major, pectoralis minor, and intercostal muscles are all common sites of myofascial pain syndromes, especially after chest wall trauma and surgery, and have unique pain referral patterns, as initially mapped by Travell and Rinzler.⁶

Conditions that may mimic myofascial pain syndromes of the anterior chest wall and upper arm may include angina pectoris, as in this case, diffuse myopathies, fibromyalgia, polymyalgia rheumatica, dermatomyositis, postherpetic neuralgia, connective tissue disorders, hypothyroidism, early Parkinsonism, multiple myeloma, osteoarthritis, bursitis, and tendonitis.⁵ Inflammatory and malignant diseases should be ruled out using the appropriate laboratory tests. Postherpetic neuralgia causes a characteristic neuropathic pain condition and usually is heralded by dermatomal shingles.

Conventional therapies for myofascial pain syndromes include physical therapy, regular stretching and exercises, vapocoolant spray and stretch techniques, dry needling and injections of trigger points with local anesthetics and antiinflammatory agents, psychotherapy, biofeedback, and pharmacotherapy.⁵ Conventional pharmacologic agents effective in myofascial pain syndromes include the tricyclic and selective norepinephrine-reuptake-inhibiting antidepressants, such as venlafaxine, nonsteroidal antiinflammatory drugs, and skeletal muscle relaxants, such as methocarbamol.⁵ Most recently, botulinum A and F toxin injections, which are approved as orphan drugs for managing severe pain and dystonia in cerebral palsy,⁷ thalamic stroke,⁸ spastic torticollis,⁹ and spinal cord infarcts and trauma,¹⁰ have been recommended for the management of chronic myofascial pain syndromes.¹¹

Myofascial pain syndromes may mimic angina pectoris after median sternotomy for cardiac surgery. Brachial plexus and musculoskeletal injuries may occur even more commonly after median sternotomy for cardiac surgery and have been correlated with harvesting of the ipsilateral internal mammary artery, usually the left, but not with intraoperative arm positioning.¹ Precise diagnostic imaging techniques may be necessary to assess chronic chest wall pain after median sternotomy for cardiac or anterior mediastinal surgery and to eliminate faulty sternotomy techniques, cartilaginous injuries, and rib fractures or disarticulations. Nerve conduction studies may be necessary to assess sensorimotor dysfunction in brachial plexus injuries. Although usually reserved for painful spasticity disorders, botulinum A toxin injections may offer a new, safe, and effective technique to manage myofascial pain syndromes.

References

1. Roy RC, Stafford MA, Charlton JE: Nerve injury and musculoskeletal complaints after cardiac surgery: Influence of internal mammary artery dissection and left arm position. *Anesth Analg* 1988; 67:277-9
2. Vahl CF, Carl I, Muller-Vahl H, Struck E: Brachial plexus injury after cardiac surgery: The role of internal mammary artery preparation: A prospective study on 1000 consecutive patients. *J Thorac Cardiovasc Surg* 1991; 102:724-9
3. Shafir R, Weiss J, Herman O, Cohen N, Stern D, Igra Y: Faulty sternotomy and complications after sternotomy. *J Thorac Cardiovasc Surg* 1988; 96:310-3
4. DeVita MA, Robinson LR, Rehder J, Hattler B, Cohen C: Incidence and natural history of phrenic neuropathy occurring during open heart surgery. *Chest* 1993; 103:850-7
5. Reynolds M.D.: Myofascial trigger points in persistent posttraumatic shoulder pain. *South Med J* 1984; 77:1277-80
6. Travell J, Rinzler SH: The myofascial genesis of pain. *Postgraduate Med* 1952; 11:425-34
7. Racette BA, Laurysen C, Perlmutter JS: Preoperative treatment with botulinum toxin to facilitate cervical fusion in dystonic cerebral palsy: Report of two cases. *J Neurosurg* 1998; 88:328-30
8. Motoi Y, Hattori Y, Miwa H, Shina K, Mizuno Y: A case of post-hemiplegic painful dystonia following thalamic infarction with good response to botulinum toxin. *Clin Neurol* 1997; 37:881-6
9. Houser MK, Sheean GL, Lees AJ: Further studies using higher doses of botulinum toxin F for torticollis resistant to botulinum toxin type A. *J Neurol Neurosurg Psychiatry* 1998; 64:577-80
10. Richardson D, Edwards S, Sheean GL, Greenwood RJ, Thompson AJ: The effect of botulinum toxin on hand function after incomplete spinal cord injury at the level of C5/6: A case report. *Clin Rehab* 1997; 11:288-92
11. Wheeler AH: Therapeutic uses of botulinum toxin. *Am Fam Phys* 1997; 55:541-5

Anesthesiology
 1999; 91:880-3
 © 1999 American Society of Anesthesiologists, Inc.
 Lippincott Williams & Wilkins, Inc.

Life-threatening Ventricular Dysrhythmias with Inadvertent Asynchronous Temporary Pacing after Cardiac Surgery

Sergey Preisman, M.D.,* Davy C. H. Cheng, M.D., M.Sc., F.R.C.P.C.†

POTENTIALLY lethal arrhythmias have long been recognized as a rare complication of cardiac pacing.^{1,2} The incidence of this catastrophic event is thought to be low even in cases of asynchronous ventricular pacing, presumably because the electrical stimuli provided by the pulse stimulator usually remain below the fibrillation threshold.³ Furthermore, the possibility of serious pacemaker-induced arrhythmias has been greatly reduced by the introduction of advanced demand modes of pacing into clinical practice. Nevertheless, this problem can still be encountered when pacemaker pulse generator is switched to asynchronous mode. We report a case in which a recently introduced and commonly used epicardial temporary pacemaker (Model 5388, Medtronic Inc., Minneapolis, MN) was accidentally switched several times to asynchronous mode, causing ventricular fibrillation in a patient after cardiac surgery.

Case Report

A 49-yr-old man with a history of aortic insufficiency of rheumatic origin and hypertension, treated with calcium channel blockers and angiotensin-converting enzyme inhibitors, was admitted to the hospital for elective aortic valve replacement. The preoperative coronary angiogram showed no signs of coronary artery disease. The electrocardiogram (ECG) demonstrated signs of left ventricular hypertrophy with strain pattern. Holter monitoring showed sinus rhythm with occasional premature atrial contractions and premature ventricular contractions (couplets and triplets).

* Fellow, Division of Cardiac Anesthesia and Intensive Care.

† Associate Professor of Anesthesia.

Received from Toronto General Hospital, University of Toronto, Toronto, Ontario, Canada. Submitted for publication December 21, 1998. Accepted for publication April 23, 1999. Support was provided solely from institutional and/or departmental resources.

Address reprint requests to Dr. Cheng: Department of Anesthesia, Toronto General Hospital, 585 University Avenue, Toronto, Ontario, Canada M5G 2C4. Address electronic mail to: davycheng@compuserve.com

Key words: Asynchronous pacing; pacemaker arrhythmias; ventricular fibrillation.

The patient underwent aortic valve replacement with a 27-mm stentless porcine valve. No intraoperative problems were encountered. In the immediate postoperative hours, several episodes of premature ventricular contractions were noticed, which resolved after normalization of potassium balance (fig. 1A). Two hours later his heart rate slowed down. Second-degree atrioventricular block with a ventricular rate of 50-54 beats/min was apparent on the ECG trace. Dual chamber paced, dual chamber sensing, and dual response (DDD) pacing was started (Medtronic 5388 dual chamber temporary pacemaker) with an atrial sensitivity of 0.5 mV and output of 10 mA, ventricular sensitivity of 2 mV and output of 10 mA, and an atrioventricular interval of 170 ms. This resulted in ventricular rate of 100-102 beats/min (atrial sensing and ventricular pacing; fig. 1B). The patient was uneventfully extubated 6 h after surgery. Occasional premature ventricular contractions, present during the first night after surgery, resolved after removal of the pulmonary artery catheter on the morning of the first postoperative day. The parameters of the pacemaker were checked. The underlying rhythm at this time was third-degree atrioventricular block with a rate of ventricular escape of 50-60 beats/min. DDD pacing with the previous parameters was commenced, and the patient was transferred to the surgical ward on a telemetry bed. Before the transfer, the pacemaker was checked again, and settings were locked. Serum magnesium and potassium levels were normal.

Approximately 1 h after the transfer, asynchronous ventricular pacing at a rate of 80 beats/min was noticed on ECG telemetric monitoring. Several minutes later, the patient suddenly lost consciousness. A decrease of pacing stimuli on the T wave with resultant ventricular fibrillation was observed on the ECG tracing (fig. 2). Cardiopulmonary resuscitation was initiated. Over an 8-min period, the patient received three external defibrillatory shocks of 300 J. After the second shock, slow ventricular rhythm of 50 beats/min was observed with rapid degeneration to polymorphic ventricular tachycardia. After the administration of 80 mg lidocaine, 2 g magnesium sulfate, and a third shock, stable rhythm with dual-chamber pacing of 100 beats/min was achieved. The patient regained consciousness and was transferred back to the intensive care unit. On arrival, the pacemaker was found to be in asynchronous mode with maximal atrial and ventricular output (20 and 25 mA, respectively). The underlying rhythm at this time was complete heart block with ventricular escape of 60-65 beats/min. The impulse generator was reprogrammed to DDD mode with the parameters described previously and was locked. The patient was stable and breathing spontaneously with a face mask. No neurologic deficit was found. After 24 h in the intensive care unit, the patient continued with DDD pacing with atrial tracking and a ventricular rate of 100-104 paced pulses/min. The underlying rhythm was complete heart block. At this point, the pacemaker was checked again because a short run of ventricular tachycardia was observed on the ECG monitor. The pacemaker was found to be in asynchronous mode again (dual chamber

CASE REPORTS

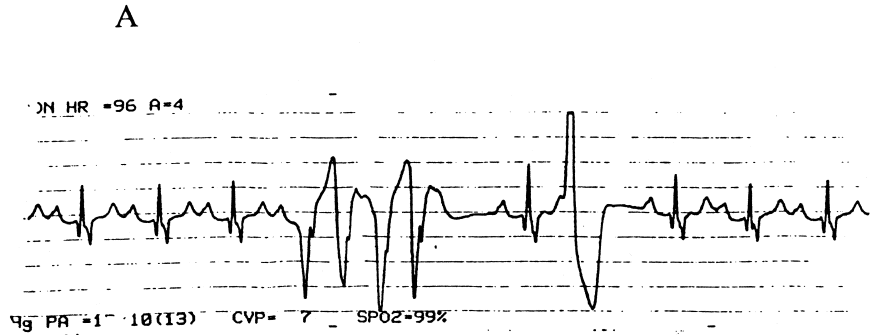


Fig. 1. Rhythm disturbances during the night after surgery. (A) Multiple multifocal premature ventricular contractions; (B) DDD pacing with atrial tracking.

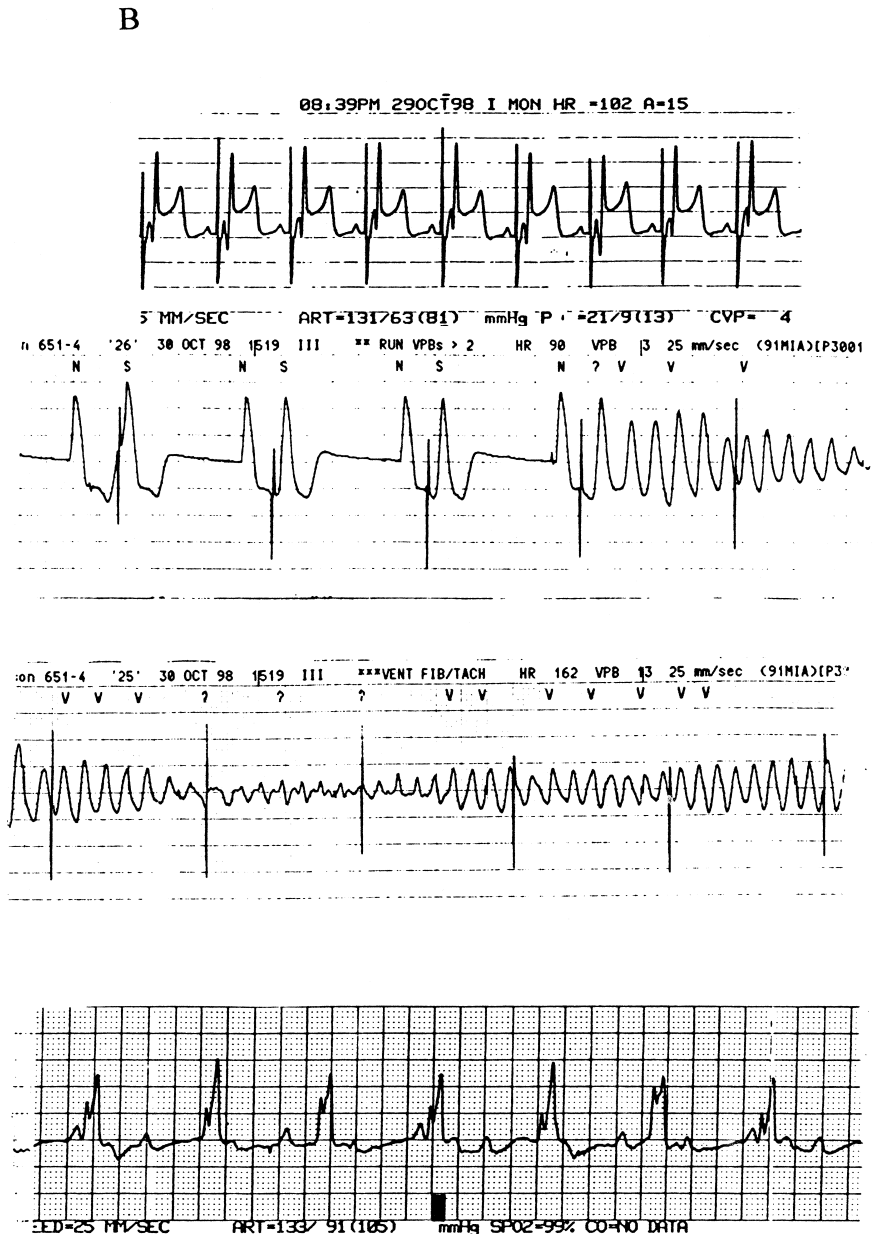


Fig. 2. Initiation of ventricular fibrillation by pacing impulse, superimposed with T wave, and electrocardiogram after resuscitation.

Downloaded from http://esa2.silverchair.com/anesthesiology/article-pdf/91/3/874/397466/0000542-199909000-00044.pdf by guest on 02 March 2024

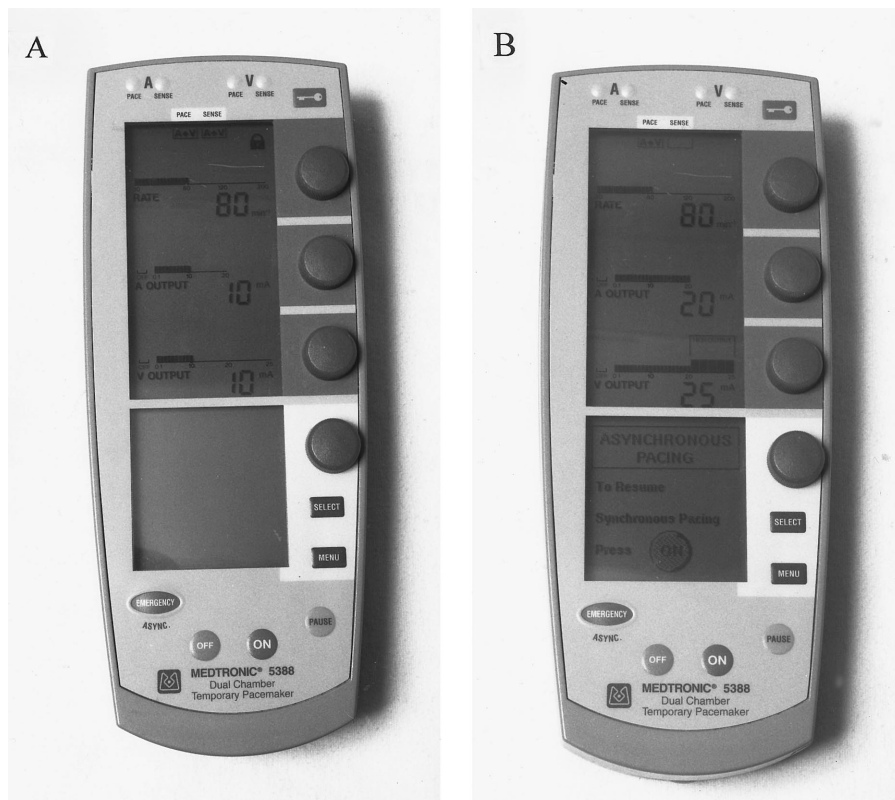


Fig. 3. Front panel of the Medtronic 5388 dual-chamber temporary pacemaker in DDD mode (A) and asynchronous mode (B).

paced, zero sensing, zero inhibition [DDO]: dual-chamber asynchronous pacing at 80 paced pulses/min, atrial output of 20 mA, and ventricular output of 25 mA). The impulse generator was replaced and checked in detail. On close examination it was found that this particular model of temporary pulse generator was very easily switched from DDD mode (atrial-triggered, ventricular-inhibited pacing) to dual-chamber asynchronous (DOO) pacing (the factory programmed default mode) by light pressure (single-finger touch) on the emergency button situated on the front panel of the device (fig. 3). This emergency DOO default mode overrides any preset (locked) pacing parameters and can be switched on even when the pacemaker is off.

The patient experienced no further dysrhythmias after changing to another atrioventricular sequential demand pulse generator (Model 5330, Medtronic Inc.). He remained in complete atrioventricular block and eventually required implantation of a permanent pacemaker.

Discussion

Reported cases of ventricular tachyarrhythmias caused by a decrease in pacemaker stimulus during the "vulnerable period" of cardiac cycle have occurred in settings of acute myocardial ischemia, electrolyte disturbances, and drug effects, when the ventricular vulnerability to fibrillation is lower.⁴ Our patient did not have demonstrable coronary artery disease. Potassium and magnesium concentrations

before arrhythmias were normal. However, the potential for altered ventricular excitation threshold must have existed. Evidence for this was atrial and ventricular dysrhythmias on the patient's preoperative Holter recording. The probable cause for this was cardiomyopathy secondary to long-standing ventricular volume overload.

This case report should alert clinicians and nursing staff to the possible danger of accidental asynchronous pacing with this model of temporary pulse generator. This could be atrial asynchronous (AOO), ventricular asynchronous (VOO), or DOO depending on whether the device was programmed AAI (atrial inhibited or demand), VVI (ventricular inhibited or demand) or DDD (also DDI; dual-chamber inhibited), respectively. Even light pressure on the emergency button, located on the front panel of the device, may trigger default mode of asynchronous pacing. This easily could happen if the patient or care provider mistakenly mishandled or touched the emergency button on the pulse generator (e.g., by picking up the pacemaker). Possible means to reduce this risk include eliminating this feature or requiring more than one depression or some other method to activate default-mode asynchronous pacing.

CASE REPORTS

References

1. Tavel EM, Fisch C: Repetitive ventricular arrhythmia resulting from artificial internal pacemaker. *Circulation* 1964; 30:493-500
2. Robinson JS, Sloman G, Hogan J, McConchie IH: Ventricular tachycardia and fibrillation with implanted electrical pacemakers. *Br Heart J* 1965; 27:937-41
3. Zoll PM, Weintraub MJ: Safety of competition from fixed rate pacemakers, *Cardiac Pacing*. Edited by Watanabe Y. Amsterdam, Excerpta Medica, 1976, pp 325-7
4. Han J: Ventricular vulnerability to fibrillation, *Cardiac Arrhythmias*. Edited by Dreifus LS. New York, Grune and Stratton, 1973, pp 87-95