

## CASE REPORTS

Anesthesiology  
1999; 91:1535-7  
© 1999 American Society of Anesthesiologists, Inc.  
Lippincott Williams & Wilkins, Inc.

## Systolic Anterior Motion of the Anterior Mitral Leaflet after Heart Transplantation

Didier Chatel, M.D.,\* Sandrine Paquin, M.D.,† Mohammad Oroudji, M.D.,‡ Sophie Provenchere, M.D.,§  
Gaetan Plantefeve, M.D.,§ Ivan Philip, M.D.†

TRANSESOPHAGEAL echocardiography (TEE) is a new tool for the perioperative treatment of cardiac surgery patients. We report a clinical case to illustrate the usefulness of TEE for evaluating morphologic and functional features of a cardiac graft. Mitral regurgitation (MR) secondary to left ventricular outflow tract obstruction with systolic anterior motion (SAM) of the anterior mitral leaflet was diagnosed preoperatively with TEE. Medical treatment of the recipient was changed consequently to prevent hemodynamic deterioration.

### Case Report

A 50-yr-old man underwent an orthotopic cardiac transplantation because of a dilated cardiomyopathy. The donor heart was retrieved from a 53-yr-old man who died from a cerebral hemorrhage. The donor had been treated for hypertension. A transthoracic echocardiogram of the donor heart showed a normal left ventricle with normal systolic function and no valvular abnormalities. The donor heart was arrested with cold St Thomas' Hospital cardioplegic solution, excised, and then stored in 4°C cold saline solution.

The recipient was anesthetized with fentanyl (total amount, 80

μg/kg), pancuronium bromide, and midazolam and was monitored with a radial artery, pulmonary artery catheter and standard anesthesia monitors. A TEE was performed with a biplane transesophageal probe (5 MHz, Aloka 870; Aloka CO, Ltd., Tokyo, Japan). The donor heart was grafted according to the standard procedure with atrial anastomoses,<sup>1</sup> but keeping only a small atrial cuff around the four pulmonary vein orifices. Total ischemia time for the graft was 3 h. Weaning from cardiopulmonary bypass was performed using isoproterenol (0.05 μg · kg<sup>-1</sup> · min<sup>-1</sup>). Subsequent hemodynamic measurements showed sinus tachycardia (130 beats/min), systolic blood pressure of 105 mmHg, pulmonary capillary wedge pressure of 14 mmHg, cardiac index of 3.1 l · min<sup>-1</sup> · m<sup>2</sup><sup>-1</sup>, and stroke volume of 42 ml. TEE examination showed a hyperkinetic left ventricle with global left ventricle hypertrophy (wall thicknesses of 14, 15, and 15 mm for anterior, septal, and posterior walls, respectively). Color flow mapping demonstrated grade II MR, assessed by the regurgitant jet diameter at the origin (4 mm) and the regurgitant jet area (5 cm<sup>2</sup>). Bidimensional analysis showed a SAM of the anterior mitral leaflet (fig. 1). Mitral valve anatomy was otherwise normal. Given that medical management (hypovolemia, tachycardia, vasodilation, and enhanced inotropism caused by isoproterenol infusion) might cause or aggravate SAM and MR, isoproterenol infusion was replaced by 10-μg · kg<sup>-1</sup> · min<sup>-1</sup> dopamine infusion (with expected alpha effects), and 500 ml modified fluid gelatine was quickly infused. Fifteen minutes later, heart rate decreased from 130 to 85 beats/min, cardiac index was 2.8 l · min<sup>-1</sup> · m<sup>2</sup><sup>-1</sup> with a stroke volume of 59 ml, and pulmonary capillary wedge pressure did not change. MR and SAM both completely resolved (fig. 2). The patient remained hemodynamically stable.

The postoperative course was uneventful. Postoperative transthoracic echocardiogram on day 10 showed a left ventricular hypertrophy with normal systolic function and trivial MR with normal mitral valve function.

### Discussion

We report a case of MR secondary to SAM of the anterior mitral leaflet after heart transplantation. This phenomenon has been previously described after other surgical procedures, including mitral valve repair and aortic valve replacement.<sup>2,3</sup> This phenomenon of left ventricular outflow tract obstruction with SAM and MR was initially described in hypertrophic cardiomyopathies with specific anatomic features<sup>4,5</sup>: a thickened interventricular septum and an anterior and medial displacement of the anterior mitral papillary muscle.

Additional material related to this article can be found on the ANESTHESIOLOGY Web Site. Go to the following address, click on Enhancements Index, and then scroll down to find the appropriate article and link. <http://www.anesthesiology.org>

\* Assistant Professor, Department of Cardiovascular Surgery.

† Staff Anesthesiologist, Department of Anesthesiology.

‡ Resident, Department of Cardiovascular Surgery.

§ Resident, Department of Anesthesiology.

Received from the Departments of Cardiovascular Surgery and Anesthesiology, Bichat Hospital, Paris, France. Submitted for publication February 8, 1999. Accepted for publication June 11, 1999. Support was provided solely from institutional and/or departmental sources.

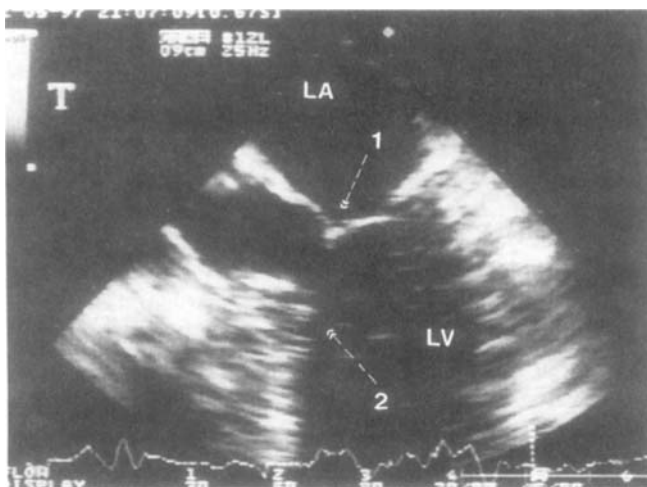
Address reprint requests Dr. Chatel: Service de Chirurgie Cardiovasculaire, Hopital Bichat, 46, rue Henri Huchard, 75877 Paris cedex 18, France. Address electronic mail to: [nativan@club-internet.fr](mailto:nativan@club-internet.fr)

Key words: Echocardiography; mitral regurgitation.

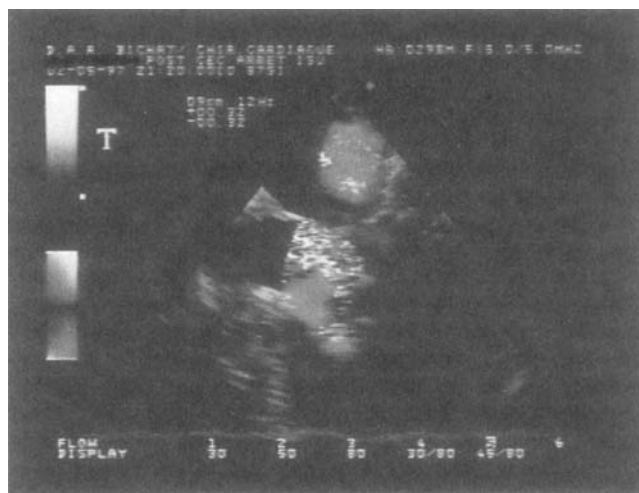
## CASE REPORTS

leading to mitral-septal contact with possible SAM and MR and, finally, mitral leaflet elongation.<sup>6</sup> Two mechanisms have been proposed for such mitral-septal contact<sup>7</sup>: a flow drag on the protruding mitral leaflet or Venturi effect through a narrowed left ventricle outflow tract. Both mechanisms can be worsened by hemodynamic conditions such as tachycardia, vasodilation, hypovolemia, and increased inotropism. After heart transplantation, common use of the  $\beta$ -adrenergic agonist isoproterenol with resultant vasodilation, tachycardia, and increased myocardial contractility, along with iatrogenic hypovolemia to prevent graft dilation, might cause or aggravate SAM of the anterior mitral leaflet.<sup>8</sup> Although we did not document it in this case, the timing of recipient atrial contraction may also have a substantial effect on the atrial contribution to left ventricular filling as well as pulmonary venous return.<sup>9</sup> Intrinsic hypertrophy of the cardiac graft, although not observed on a technically difficult transthoracic echocardiogram, was likely a major predisposing factor for SAM of the anterior mitral leaflet and associated MR. Alterations in medical management elicited by the TEE findings of SAM of the anterior mitral leaflet with associated MR enabled us to correct the MR and prevent possible deterioration in the recipient's hemodynamic status.

Mitral regurgitation has been previously reported on postoperative transthoracic echocardiogram and TEE examinations performed on heart recipients.<sup>10-12</sup> However, the cause was different than in this case. Stevenson *et al.*<sup>12</sup> noted MR in 14 of 16 post-transplant patients and attributed this high rate to surgical techniques that re-



**Fig. 1.** Transverse view showing the systolic anterior motion of the anterior mitral leaflet (*arrow 1*) and the interventricular septum hypertrophy (*arrow 2*). LA = left atrium; LV = left ventricle.



**Fig. 2.** Transverse view after the medication changes showing no mitral regurgitation.

sulted in an enlarged left atrium with mitral annular dilatation and resultant anuloventricular disproportion. This disproportion was explained as follows: left ventricle is restrictive because of increased contractility due to decreased vagal/tone or higher heart transplant rates; the mitral annulus is dilated in absolute value during the systole and, because of an abnormal geometry of the left atrium, configured as a "snowman" with the actual anastomoses. This anatomic configuration was not observed in our current case because we kept a minimal cuff of left atrium around the pulmonary vein orifices.<sup>13</sup> Other investigators suggested that multivalvular regurgitation observed after heart transplantation might be a result of mild edema of the cardiac structures.<sup>10</sup> Indeed, they found a significant left ventricular mass reduction within the first postoperative weeks, with a progressive resolution of valvular regurgitation. In a more recent work, the incidence of MR after cardiac transplantation was 48%; MR was mild and correlated with neither hemodynamic indices nor atrial distortion, by contrast with tricuspid regurgitation.<sup>11</sup> Taken together, all of these works show that MR is frequent after heart transplantation; nevertheless, the mechanism often remains controversial.

## References

1. Shumway NE, Lower RR, Stofer RC: Transplantation of the heart. *Adv Surg* 1966; 2:265-84
2. Mihaileanu S, Marino JP, Chauvaud S, Perier P, Forman J, Vissoat J, Julien J, Dreyfus G, Abastado P, Carpentier A: Left ventricular outflow obstruction after mitral valve repair (Carpentier's technique). *Circulation* 1988; 78(suppl 1):I-78-84

## CASE REPORTS

3. Cutrone F, Coyle JP, Novoa R, Stewart R, Currie PJ: Severe dynamic left ventricular outflow tract obstruction following aortic valve replacement diagnosed by intraoperative echocardiography. *ANESTHESIOLOGY* 1990; 72:563-6
4. Schwammenthal E, Nakatani S, He S, Hopmeyer J, Sagie A, Weyman AE, Lever HM, Yoganathan AP, Thomas JD, Levine RA: Mechanism of mitral regurgitation in hypertrophic cardiomyopathy. *Circulation* 1998; 98:856-65
5. Wigle ED, Rakowski H, Kimball BP, Williams WG: Hypertrophic cardiomyopathy: Clinical spectrum and treatment. *Circulation* 1995; 92:1680-92
6. He S, Hopmeyer J, Lefebvre XP, Schwammenthal E, Levine RA: Importance of leaflet elongation in causing systolic anterior motion of the mitral valve. *J Heart Valve Dis* 1997; 6:149-59
7. Sherrid MV, Dellia E, Mogtader A, Dwyer EM: An echocardiographic study of the fluid mechanics of obstruction in hypertrophic cardiomyopathy. *J Am Coll Cardiol* 1993; 22:816-25
8. Udelson JE, Cannon RO, Bacharach SL, Rumble TF, Bonow RO:  $\beta$ -adrenergic stimulation with isoproterenol enhances left ventricular diastolic performance in hypertrophic cardiomyopathy despite potentiation of myocardial ischemia. *Circulation* 1989; 7:371-82
9. Valentine HA, Appleton CP, Hatle LK, Hunt SA, Stinson EB, Popp RL: Influence of recipient atrial contraction on left ventricular filling dynamics of the transplanted heart assessed by Doppler echocardiography. *Am J Cardiol* 1987; 59:1159-63
10. Cladellas M, Abadal ML, Pons-Llado G, Ballester M, Carreras F, Obrador D, Garcia-Moll M, Padro JM, Aris A, Caralps JM: Early transient multivalvular regurgitation detected by pulsed Doppler in cardiac transplantation. *Am J Cardiol* 1986; 58:1122-4
11. De Simone R, Lange R, Sack FU, Mehmanesh H, Hagl S: Atrioventricular valve insufficiency and atrial geometry after orthotopic heart transplantation. *Ann Thorac Surg* 1995; 60:1686-93
12. Stevenson LW, Dadourian BJ, Kobashigawa J, Child JS, Clark SH, Laks H: Mitral regurgitation after cardiac transplantation. *Am J Cardiol* 1987; 60:119-22
13. Deleuze PH, Benvenuti C, Mazzucotelli JP, Perdrix C, Le Besnerais P, Mourtada A, Hillion ML, Patrat JF, Jouannot P, Loisançe DY: Orthotopic cardiac transplantation with direct caval anastomosis: Is it the optimal procedure? *J Thorac Cardiovasc Surg* 1995; 109:731-7

Anesthesiology  
1999; 91:1537-40  
© 1999 American Society of Anesthesiologists, Inc.  
Lippincott Williams & Wilkins, Inc.

## Case of Cowden's Disease that Caused Airway Obstruction during Induction of Anesthesia

Keiichi Omote, M.D.,\* Tomoyuki Kawamata, M.D.,† Hitoshi Imaizumi, M.D.,‡ Akiyoshi Namiki, M.D., Ph.D.§

COWDEN'S disease, known also as multiple hamartoma syndrome, is a rare, predominantly inherited condition characterized by various ecto-, meso-, and endodermal benign and malignant tumors that may affect the skin; oropharyngeal, laryngeal, and gastrointestinal mucosa; thyroid; breast; and other organs.<sup>1,2</sup> We report a case of airway obstruction during induction of general anesthe-

sia caused by the presence of extended multiple papillomas on the lingual tonsils, epiglottis, and the surrounding structure, for which a diagnosis of Cowden's disease was made postoperatively.

### Case Report

A 55-yr-old woman was scheduled for elective mastectomy for cancer of the right breast. At the age of 12 yr, the patient had undergone bilateral tonsillectomy. Three years later, she underwent surgery for chronic sinusitis. At age 27 yr, she underwent partial thyroidectomy for benign adenomatous changes in the right lobe of the thyroid gland. The patient denied having had any complications from previous anesthesia. Preoperative plain radiograph and computed tomography images showed a giant adenoma in the left lobe of the thyroid gland that did not show any signs of compressing the trachea. The patient had neither history of decreased activity nor any obvious breathing difficulty.

Anesthesia was induced with intravenous propofol (1.2 mg/kg) and vecuronium (0.1 mg/kg). While performing tracheal intubation, visualization of the hypopharynx by direct laryngoscopy showed a mass of tumors occupying the airway. The epiglottis and the surrounding structures could not be identified because of the presence of numerous

\* Assistant Professor, Department of Anesthesiology.

† Instructor, Department of Anesthesiology.

‡ Associate Professor, Department of Emergency Medicine.

§ Professor and Chairman, Department of Anesthesiology.

Received from the Departments of Anesthesiology and Emergency Medicine, Sapporo Medical University School of Medicine, Sapporo, Japan. Submitted for publication February 22, 1999. Accepted for publication June 22, 1999. Support was provided solely from institutional and/or departmental sources.

Address reprint requests to Dr. Omote: Department of Anesthesiology, Sapporo Medical University School of Medicine, South-1, West-16, Chuoku, Sapporo, 060-8543, Japan. Address electronic mail to: komote@sapmed.ac.jp

Key words: Hamartoma; lingual tonsil; papilloma.