

Efficiency of a New Fiberoptic Stylet Scope in Tracheal Intubation

Takayuki Kitamura, M.D.,* Yoshitsugu Yamada, M.D., Ph.D.,† Hong-Lin Du, M.D., Ph.D.,‡
 Kazuo Hanaoka, M.D., Ph.D.§

Background: Failed or difficult tracheal intubation is an important cause of morbidity and mortality during anesthesia. Although a number of fiberoptic devices are available to circumvent this problem, many do not allow manual control of the flexion of the tip and necessitate time-consuming preparation, special training, or the use of an external light source. To improve these limitations, the authors designed a new fiberoptic stylet scope (FSS) that has a simple form of a standard stylet with the fiberoptic view and maneuverability of its tip. This study was undertaken to prospectively evaluate the effectiveness of the FSS in tracheal intubation.

Methods: Thirty-two patients undergoing general surgery participated in this study. The authors used a standard laryngoscope only to elevate the tongue, then tracheal intubation was attempted with the glottic opening being viewed only through the FSS. The success rate, time necessary for intubation, hemodynamics, and adverse effects were recorded.

Results: The success rate of tracheal intubation on the first attempt using the FSS was 94% (30 of 32 patients), and the remaining two patients were intubated successfully on the second attempt. The mean time necessary for the intubation procedure was 29 ± 14 s in all patients (mean \pm SD). Changes in hemodynamics during intubation were well within acceptable ranges. There were no major adverse effects, but minor sore throat (28%) and minor hoarseness (25%) on the first postoperative day.

Conclusions: Tracheal intubation using the FSS proved to be a simple and effective technique for airway management. (Key words: Airway management; fiber optics.)

* Clinical and Research Fellow, Surgical Center, The Institute of Medical Science.

† Associate Professor, Surgical Center, The Institute of Medical Science.

‡ Visiting Assistant Professor, Department of Anesthesiology, Faculty of Medicine.

§ Professor and Chairman, Department of Anesthesiology, Faculty of Medicine.

Received from the Surgical Center, the Institute of Medical Science, and the Department of Anesthesiology, Faculty of Medicine, University of Tokyo, Tokyo, Japan. Submitted for publication April 12, 1999. Accepted for publication July 2, 1999. Support was provided by institutional and/or departmental sources.

Address reprint requests to Dr. Yamada: Surgical Center, the Institute of Medical Science, University of Tokyo, 4-6-1 Shirokane-dai, Minato-ku, Tokyo 108-8639, Japan. Address electronic mail to: ysyamada-tyk@umin.u-tokyo.ac.jp

FAILED or difficult tracheal intubation is an important cause of morbidity and mortality during anesthesia. The most common factor preventing successful tracheal intubation is the inability to see the vocal cords during direct laryngoscopy. A number of devices are available to circumvent the difficult airway problems typically encountered with conventional direct laryngoscopy. These airway devices include flexible fiberoptic bronchoscopes, the rigid optical stylet, light wands, rigid fiber-scopes, such as the UpsherScope (Upsher Laryngoscope Corp., Foster City, CA), the Bullard laryngoscope (Circon ACMI, Stamford, CT), the Augustine Scope (Augustine Medical Inc. Eden Prairie, MN), and a visualized endotracheal tube. Although these devices have been used as adjuncts to facilitate difficult tracheal intubation, many necessitate the use of a specific video system, do not allow manual control of the flexion of the fiberoptic tip, and necessitate time-consuming preparation and an external light source, or both.¹⁻⁵ To improve the usefulness of available devices, we designed a fiberoptic stylet scope (FSS) that enables us to guide the endotracheal tube (ETT) into the trachea using visual control, requires short time to prepare, and does not need an external light source. The FSS is a simple form of a standard stylet, with the functional maneuverability and control of its tip and fiberoptic cables in the body. The intubation procedure is performed in the usual manner without compromising the view of direct laryngoscopy, while the view of the airway from the tip of the ETT can be controlled manually because of the FSS tip flexion.

The current study was undertaken to prospectively assess the efficiency of the FSS as an intubating tool.

Materials and Methods

Device

The diagram of the FSS (StyletScope, NihonKoden Corp., Tokyo, Japan) is shown in figure 1. Instead of glass fibers, the FSS uses a plastic fiberoptic imaging

EFFICIENCY OF A NEW FIBEROPTIC STYLET SCOPE




Fig. 1. The new fiberoptic stylet scope (FSS), StyletScope. (A) Diagram of the new FSS. By depressing the lever of the proximal handle, the distal tip of the stylet, together with the endotracheal tube, can be flexed 75° (B).

system incorporated directly into an endotracheal tube stylet (diameter, 6.0 mm). The FSS can be used with an ETT with an internal diameter of 7.0 mm or larger. The FSS consists of a flexing element made of two 2.0-mm malleable metal plates, a 1.0-mm-diameter plastic fiberoptic image guide embedded in an illumination fiberoptic bundle to form a lightweight intubation stylet. The proximal handle of the stylet carries a connector that fits to the 15-mm ETT adapter. The image guide is 3,500 pixels with an attached lens. The lens has a 50-mm focal length and a 50° field of view. An eyepiece is mounted on the handle of the scope. By depressing the lever

attached to the proximal handle, the distal tip of the stylet, together with the ETT, can be flexed 75° anteriorly to provide direct access to anterior airways. A light source is built-in to the stylet handle and powered by two 1.5-V alkaline batteries. The FSS is reusable and can be sterilized using ethylene oxide.

Technique

The FSS is inserted into an ETT and locked with the stylet connector to the endotracheal tube adapter, preventing rotational and longitudinal displacement. The proper position of the stylet tip is just proximal to the bevel of the ETT, and it can be adjusted by sliding the connector within the housing. An antifog agent (Lens Cleaner, Olympus Japan, Tokyo, Japan) was lightly applied to the tip of the FSS using a clean gauze. Before the start of the intubation procedure, the FSS should be quickly checked for correct view and function. While the tongue is lifted using a standard laryngoscope blade, the ETT with the FSS is inserted into the mouth (fig. 2). The view of the epiglottis can be obtained directly behind the tongue. After the tip of the ETT has passed the epiglottis, if the direct view of the laryngeal aperture is not obtained instantaneously, the lever of the FSS can be gently depressed to bend the ETT anteriorly. In most cases, this maneuver resulted in orientation of the ETT tip toward the opening between the vocal cords, and the ETT can be inserted easily during direct visual control (the view is shown in fig. 3).

Study Protocol

After obtaining approval from the Ethics Committee for Research of the Institute of Medical Science, the University of Tokyo, and the informed consent from each patient, we studied 32 consecutive patients undergoing general surgery who required oral tracheal intubation. Exclusion criteria from enrollment were age younger than 18 or older than 85 yr, American Society of Anesthesiologists (ASA) physical status IV, presence of coronary heart disease, cerebrovascular disease, or respiratory tract disease, and the known risk of regurgitation-aspiration (e.g., hiatal hernia, esophageal reflux, peptic ulcer, or not having fasted). During the preoperative visit, the Mallampati test, as modified by Samssoon and Young,⁶ was performed by asking each patient to maximally protrude the tongue from a fully open mouth while sitting upright. During induction of anesthesia, the thyromental distance and the interincisor distance were measured. The thyromental distance was described as a

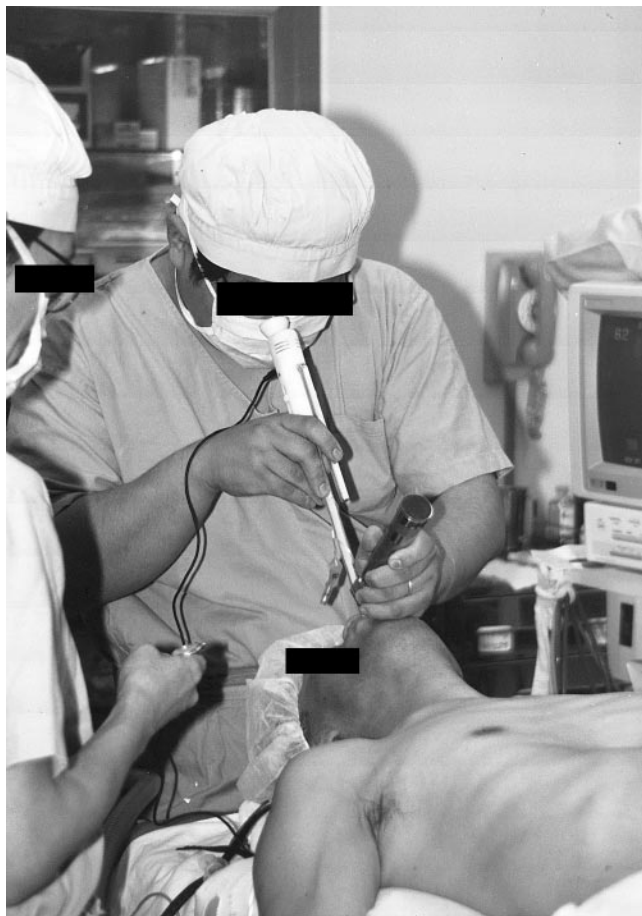

Fig. 2. Tracheal intubation procedure. After lifting the tongue using a standard laryngoscope blade, tracheal intubation is performed with the glottic opening viewed only by the fiberoptic stylet scope.

straight line from the thyroid notch to the lower border of the mentum with the head extended.

Patients were premedicated with 0.01 mg/kg atropine sulfate and 0.5 mg/kg hydroxyzine. Routine monitoring, including electrocardiography, pulse oximetry, capnography, and noninvasive blood pressure monitoring, was performed before induction. The lungs of all patients were preoxygenated for 2 min and 2.0 $\mu\text{g}/\text{kg}$ fentanyl was administered intravenously. Propofol, 1.0 mg/kg, was administered over 20 s and subsequently infused at a rate of 10 $\text{mg} \cdot \text{kg}^{-1} \cdot \text{h}^{-1}$. After adequate mask ventilation with 100% oxygen was ensured, 0.15 mg/kg vecuronium was administered to facilitate tracheal intubation.

With the patient's head and neck in the neutral position, a standard Macintosh laryngoscope (blade No. 3) was used only to elevate the tongue. Gentle traction

force was exerted on the laryngeal soft tissues without attempting direct visualization of the glottic opening. At this time, the patient's laryngeal structures were inspected and graded according to Cormack and Lehane.⁷ The intubation was completed, with the glottic opening being viewed only through the FSS (fig. 3). All intubations were performed by a 3-yr resident in anesthesiology (T.K.) who had no experience with the FSS but had received brief instruction regarding the use of the FSS before the study.

Times necessary for tracheal intubation were recorded, beginning at the moment of insertion of the laryngoscope into the mouth until the time when the FSS was removed from the ETT. The following data were recorded: age, weight, height, sex, potential, or known airway difficulty. Heart rate, blood pressure, and SpO_2 were recorded before induction of anesthesia, before starting intubation, and immediately after intubation.

Statistics

Results are expressed as the mean \pm SD. The time necessary for intubation among the groups divided according to the classes of Mallampati was compared using one-way analysis of variance. A comparison between the first five and last five patients was performed using an unpaired *t* test. A *P* value < 0.05 was considered significant.

Results

Mean age, height, and weight were 57 yr (range, 39–81 yr), 161 cm (range, 142–178 cm), and 56 kg

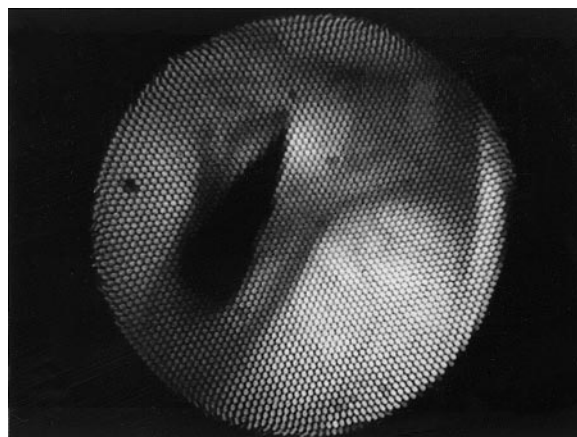


Fig. 3. A view of the glottic opening through the fiberoptic stylet scope (FSS). This photograph was taken using a charge-coupled device camera attached to the eyepiece of the FSS.

EFFICIENCY OF A NEW FIBEROPTIC STYLET SCOPE

Table 1. Variables Concerning the Difficult Airway

Class of Mallampati (number of patients)	I:19 II:10 III:3 IV:0
Thyromental distance (mm) [mean \pm SD (range)]	83 \pm 11 (61–106)
Interincisor distance (mm) [mean \pm SD (range)]	37 \pm 8 (24–57)

(range, 39–77 kg), respectively. The male:female ratio was 14:18. Airway variables are shown in table 1. Because we used a standard laryngoscope only to elevate the tongue, all patients were graded as Cormack grade III, indicating that only the epiglottis could be visible by direct laryngoscopy. In this condition, tracheal intubation using the FSS was successful during the first attempt in all patients except for two (the success rate during the first attempt, 94%). The second attempt was successful in these two patients (6%). The reasons for failure during the first attempt were mucous secretions on the lens in one instance and insufficient visualization of the glottic opening caused by the lack of space behind the epiglottis in the other. The mean time necessary for the intubation procedure was 29 ± 14 s in all patients, and 30 ± 15 s, 22 ± 7 s, and 32 ± 19 s in the patients classified as Mallampati class I, II and III, respectively (fig. 4). There was no significant difference ($P = 0.64$) between the time necessary for the intubation procedure for the first five patients (33 ± 8 s) and that for the last five patients (29 ± 14 s).

All patients were hemodynamically stable and Sp_{O_2} was maintained above 98% throughout the intubation procedure. There were no adverse airway events during intubation. Neither major soft tissue damage nor dental trauma occurred, as determined by oral examination after intubation and by postoperative questioning. The incidence of minor sore throat and minor hoarseness on the first day after operation was 28 and 25%, respectively. No patient suffered from sustained hoarseness or laryngeal damage.

Discussion

This prospective study showed that the FSS enables simple, reasonably rapid, gentle intubation. The rate of successful intubation was 94% on the first attempt and all patients in whom the first attempt was unsuccessful were successfully intubated on the second attempt.

Many commercially available airway devices necessitate the use of a specific video system, do not allow manual control of the flexion of the fiberoptic tip, and

need time-consuming preparation and an external light source, or both.¹⁻⁵ The FSS, with its flexible plastic fiberoptic image system incorporated into the ETT stylet, can be flexed 75° anterior using the built-in light source and lightweight. It enables visualization of laryngeal structures and the trachea during the entire intubation procedure. During visual control viewed from the tip, the ETT can be directed at and passed through the glottic opening by maneuvering the tip when direct laryngeal exposure using a common laryngoscope blade is inadequate. In comparison, many other airway devices that directly view the glottis (e.g., UpsherScope) lack this maneuverability and force the patients upper airway anatomy to conform to the particular shape of the laryngoscope blade.¹ Although the image quality of the FSS appears to be inferior to the glass fiberscopes using 5,000 to 10,000 pixels in clinical practice, our experience indicates that it is clear enough for a successful intubation (fig. 3).

Other advantages of the FSS include necessitation of only little preparation time, prompt recognition and confirmation of tracheal placement of the tube, and simplicity of the intubation technique without the need for special training. The operator of the FSS in this study did not undergo preliminary training specific to the FSS technique before the study. There was no significant difference between the time necessary for intubation of the first five patients and the last five patients in this study.

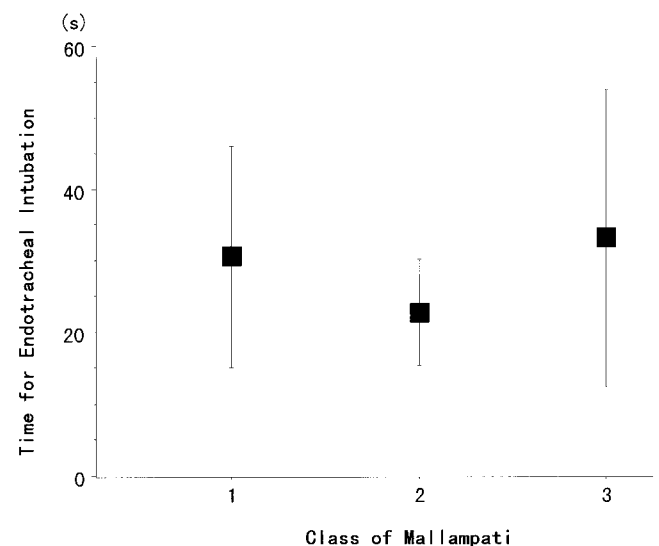


Fig. 4. Comparison of the time necessary for tracheal intubation using the new fiberoptic stylet scope among the groups divided according to the classes of Mallampati. There is no significant difference among the three groups.

Changes in hemodynamics were well within acceptable ranges and arterial blood was maintained fully saturated throughout the intubating procedure. No trauma associated with the procedure was observed in this study. Although no patient had sustained hoarseness or laryngeal damage, the incidence of minor sore throat and minor hoarseness on the first day after operation were 28 and 25%, respectively. These incidences are comparable to those in the patients intubated using usual direct laryngoscopy (50%).⁸

This study was conducted in a simulated difficult airway with Cormack grade III. Although this simulation may not be equivalent to a truly difficult airway, the FSS might be useful in the event of a difficult airway. There are several potential limitations with the FSS. Similar to fiberoptic intubation, intubation with the FSS might become difficult in patients with heavy secretions or gross blood in their airways. Secretions or blood in the oropharynx should be removed by airway suction during standard laryngoscopy before attempting intubation with the FSS. In addition, nasal intubation is impractical using the FSS.

In conclusion, intubation using the FSS proved to be a simple and effective technique for airway management.

References

1. Fridrich P, Frass M, Krenn CG, Weinstabl C, Benumof JL, Krafft P: The UpsherScope™ in routine and difficult airway management: A randomized, controlled clinical trial. *Anesth Analg* 1997; 85:1377-81
2. Cooper SD, Benumof JL, Ozaki GT: Evaluation of the Bullard laryngoscope using the new intubating stylet: Comparison with conventional laryngoscopy. *Anesth Analg* 1994; 79:965-70
3. Krafft P, Krenn CG, Fitzgerald RD, Pernerstorfer T, Fridrich P, Weinstabl C: Clinical trial of a new device for fiberoptic orotracheal intubation (Augustine Scope™). *Anesth Analg* 1997; 84:606-10
4. Katz RL, Berci G: The optical stylet? A new intubation technique for adults and children with specific reference to teaching. *ANESTHESIOLOGY* 1979; 51:251-4
5. Weiss M: Video-intuboscopy: A new aid to routine and difficult tracheal intubation. *Br J Anaesth* 1998; 80:525-7
6. Samsoun GLT, Young JRB: Difficult tracheal intubation: A retrospective study. *Anaesthesia* 1987; 42:487-90
7. Cormack RS, Lehane J: Difficult tracheal intubation in obstetrics. *Anaesthesia* 1984; 39:1105-11
8. Alexander CA: Incidence of sore throat with the laryngeal mask (letter). *Anaesthesia* 1989; 44:791